

Original Research Article

An institutional evaluation of radiotherapy with concurrent and adjuvant temozolomide exclusively in grade III gliomas

Naga Chandra Sekhar Darisi¹, V. L. Anusha Konakalla^{1*}, Venkata Pradeep Babu Koyyala²

¹Department of Radiotherapy, GSL Medical College and General Hospital, Rajahmundry, Andhra Pradesh, India

²Department of Medical Oncology, Assam Cancer Care Foundation, Tezpur, Assam, India

Received: 25 October 2021

Revised: 09 November 2021

Accepted: 10 November 2021

*Correspondence:

Dr. V. L. Anusha Konakalla,

E-mail: anushakvl@gmail.com

Copyright: © the author(s), publisher and licensee Medip Academy. This is an open-access article distributed under the terms of the Creative Commons Attribution Non-Commercial License, which permits unrestricted non-commercial use, distribution, and reproduction in any medium, provided the original work is properly cited.

ABSTRACT

Background: Gliomas are the most common tumors that develop from glial cells in the brain. As per WHO classification, grade III (high-grade) gliomas are usually treated by surgery followed by radiotherapy. Concurrent and adjuvant chemotherapy with temozolomide (TMZ) is showing new hope in the management.

Methods: Prospective study was conducted in 20 WHO grade III glioma patients at GSL medical college and general hospital for a period of 2 years (August 2019 to July 2021) to evaluate the role of concurrent and adjuvant TMZ with radiation in the treatment of grade III gliomas. The primary objectives of the study were to determine toxicity and response rates in our set of patients. The secondary objectives were to determine progression-free survival and overall survival.

Results: Majority were males (80%) in the age group of 30 to 49 (75%). 40% of gliomas were in the temporal lobe. Headache was the most presenting symptom (60%) followed by seizures (35%). 70 to 80 Karnofsky performance status/ KPS score was seen in 70% of cases. None of the patients in the study had grade 3 or 4 toxicities. 40% had a complete response according to MacDonald's criteria. At a median follow-up of 10 months, 25% of patients had disease progression and 1yr overall survival was 95%.

Conclusions: TMZ combined with radiation was well tolerated in our set of patients with grade III gliomas without any significant toxicity.

Keywords: Grade III glioma, TMZ, Radiotherapy

INTRODUCTION

Gliomas are tumors that develop from glial cells in the brain or spine and they make up the majority of primary brain parenchymal cancers. According to the latest GBD-2016 brain and other CNS cancer report, gliomas are still a major contributor to the burden of brain cancers.¹ In the revised fourth edition of the WHO classification of CNS tumors published in 2016, grades I and II were considered as low-grade gliomas and grades III and IV as high-grade gliomas.² Grade III consists of Anaplastic astrocytoma, anaplastic oligodendroglioma, and

anaplastic oligoastrocytoma with a survival rate of 30-60%.² As per SEER data analysis the median survival increased from 15 to 24 months for grade III astrocytoma patients.³

Grade III gliomas exhibit nuclear atypia, hypercellularity, and increased mitotic figures. These gliomas diffusely infiltrate surrounding brain parenchyma and they have a tendency to cross the midline to involve the contralateral hemisphere. Patients present with features of raised intracranial pressure, seizures, and focal neurological deficits depending on the size and area of the brain

involved. They produce considerable edema and mass effect.

The standard initial treatment for grade III gliomas is safe maximal resection. Surgery is useful to establish the diagnosis, alleviate symptoms, and better survival but because of its infiltrative nature gross tumor resection (GTR) is difficult to achieve.⁴ Radiation therapy has been the standard component of the adjuvant treatment for grade III lesions.⁴ Adjuvant RT with concurrent and adjuvant TMZ is the standard treatment for glioblastoma patients based on results from the EORTC NCIC study done by Stupp et al which showed better OS at 5 years (10% vs 2%).⁵ Although TMZ is effective for treating recurrent grade III gliomas, its role in primary grade III glioma patients exclusively has not been extensively used because it was not fully tested.^{6,7} The addition of TMZ to radiation for patients with grade III gliomas is common clinical practice despite the lack of strong evidence demonstrating a survival advantage.

Aim and objectives

The present study aims to evaluate the role of concurrent and adjuvant TMZ with radiation in the treatment of grade III gliomas. The primary objectives of the study were to determine toxicity and response rates in our set of patients. The secondary objectives were to determine progression-free survival and overall survival.

METHODS

This prospective study was conducted at GSL medical college and general hospital which is a tertiary multispecialty teaching hospital for a period of 2 years (August 2019 to July 2021). All the patients who attended the outpatient department of the institution with a diagnosis of grade III gliomas (including anaplastic astrocytomas, oligodendrogliomas, and mixed oligoastrocytomas) and who gave consent to participate in the study were included for the study. Patients with grade II gliomas with both radiological features of high-grade gliomas and a higher MIB-1 index (>5%) were also included. Grade-I and II and grade III glioma patients who were not willing to participate or lost to follow-up were excluded from the study. Institutional ethics committee (IEC) approval was taken.

Patients were immobilized in the supine position with headrest by thermoplastic mould and planning CECT was obtained in the same position. Planning MRI was obtained with no interslice gap and all the sequences (FSPGR/ BRAVO, FSPGR/ BRAVO with contrast, T2, T2 FLAIR) were captured and fused with the planning CT.

Target volume: Initial tumor volume consists of preoperative tumor volume (GTV) with 1.5 cm margin covering perilesional edema (CTV) and 0.5 cm PTV margin for setup errors to a dose of 50 Gy in 25 fractions

with 200 cGy as fraction dose followed by boost dose to GTV with 1 cm margin to a total dose to 60 Gy in 30 fractions.

All patients were treated with 6MV photons by volumetric modulated arc therapy (VMAT) to a total dose of 60 Gy/30#, 5#/week along with daily concurrent TMZ 75 mg/m² followed by 6 cycles of adjuvant TMZ 150-200 mg/m² from day 1-5 for every 28 days. TMZ when given concurrently with radiation was started from day 1 daily and 30 minutes before radiation.

All patients were closely monitored during their entire treatment course. All patients received TMZ based on BSA. Hydration, protein, and caloric intake were adequately maintained for all the patients during the entire treatment course. Hemogram and biochemical investigations were done and noted weekly. All patients were examined weekly during the treatment.

During follow up, the patients were assessed for radiological response at 3, 6, 12, 18 months. The radiological response was assessed based on Macdonald's criteria.⁸

Data were entered into Microsoft excel and analyzed by IBM SPSS software trial version 21 from the period of inclusion in the study. Descriptive data were presented as percentages. Data is also tabulated and graphically represented. The survival curves were estimated using the Kaplan-Meier method for progression-free survival and overall survival at 1-year follow-up.

Informed consent was taken from each participant before including in the study. In case of noncompliance to follow-up, patients were contacted by phone or post to collect the relevant information.

RESULTS

A total of 20 patients with grade III glioma were included in the study. 80% of the study population were males. 30 to 39 years age group were more in this study followed by 40 to 49 years (median age 43). Temporal lobe was the most common site (40%) followed by frontal lobe (35%). Grade III anaplastic astrocytoma was the most common frequent glioma (35%) followed by grade III oligodendroglioma (30%). Headache was the most presenting symptom (60%) followed by seizures (35%). All the patient and disease characteristics were mentioned in Tables 1 and 2. The majority of patients had a KPS score of 70-80.

A great majority of patients included in this study had pathology-proven grade III tumors (85%). Whereas in 3 patients (15%), although the histopathology revealed that the tumor was grade II, imaging was suggestive of a high-grade tumor and the MIB-1 index was higher than 5%. A majority (80%) of patients received steroids for at least a week during the radiotherapy.

Table 1: Distribution of patient characteristics.

Variables		N	Percentage (%)
Gender	Male	16	80
	Female	4	20
Age (years)	30-39	11	55
	40-49	4	20
	50-59	3	15
	>60	2	10
	Median age	43	
Site	Frontal lobe	7	35
	Temporal lobe	8	40
	Parietal lobe	4	20
	Inaccessible site	1	5
WHO grade II with high MIB-1 index/radiological high grade	Anaplastic astrocytoma	1	5
	Oligodendroglioma	1	5
	Mixed astrocytoma	1	5
WHO grade III	Anaplastic astrocytoma	7	35
	Oligodendroglioma	6	30
	Mixed astrocytoma	4	20
Presenting complaints	Headache	12	60
	Seizures	7	35
	Speech abnormality	3	15
	Parosmia	1	5

Table 2: Distribution of KPS, toxicity, and response among total study population.

Variables		N	Percentage (%)
KPS	100	1	5
	90	2	10
	80	7	35
	70	7	35
	60	3	15
Toxicity	Loss of appetite	10	50
	Nausea	7	35
	Parosmia	5	25
	Grade 3 or 4 hematological toxicity	0	0
Response (Macdonald criteria)	Complete response	8	40
	Partial response	7	35
	Stable disease	5	25

All the patients received planned adjuvant radiation dose of 60 Gy/30#, 5#/week along with concurrent TMZ and 6 months of adjuvant TMZ. No patient had treatment

breaks or grade 3 or 4 hematological toxicities. Half of the study population had a loss of appetite, 35% had nausea.

The majority (40%) had a complete response according to MacDonald’s criteria.⁸

The Median follow-up in the study population was 10 months.

The 25% of patients had disease progression at the time of analysis and 1-year overall survival was 95% (Figure 1 and 2).

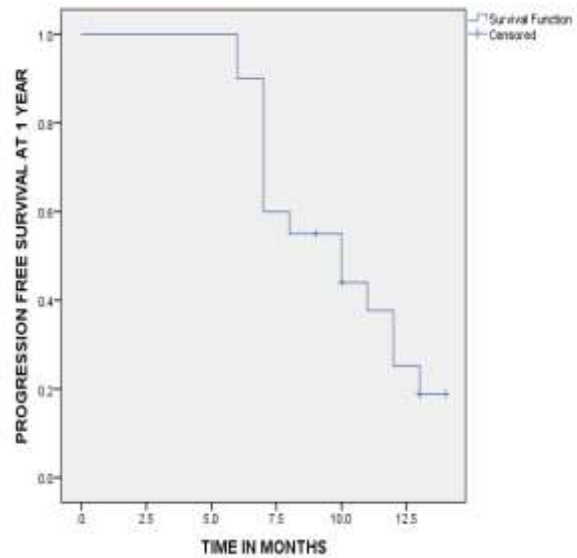


Figure 1: Kaplan-Meier survival plot for progression-free survival at 1 year.

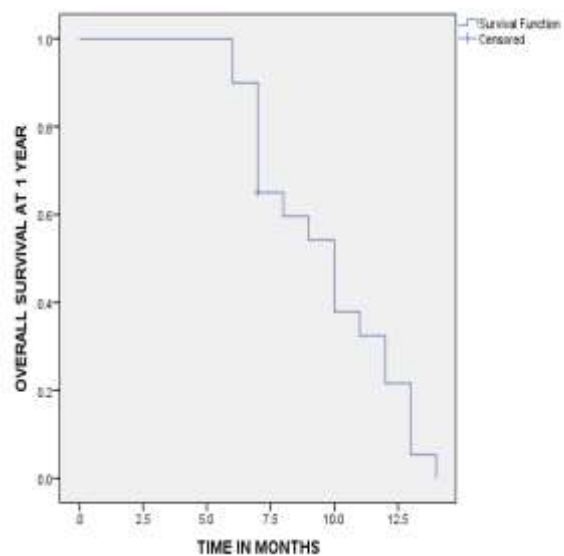


Figure 2: Kaplan-Meier survival plot for overall survival at 1 year.

Table 3: Outcome at 1 year.

Outcome at 1 year	N (%)	Meantime (Months)	95%, CI	Median time (Months)	95%, CI
Progression-free survival	75	9.8	8.5 to 11.1	10	5.9 to 14
Overall survival	95	9.6	8.4 to 10.8	10	7.9 to 12

Table 4: Comparison of present study with similar studies.

Study	Progression-free survival at 1 year (%)	Overall survival rate at 1 year (%)
Young-Hoon et al¹⁵	74.2	96.8
Hwang et al¹⁶	71.4	84
Present study	75	95

DISCUSSION

In this institutional prospective study, a total of 20 grade III glioma patients were included in final analysis. The median age of patients is 43 years (Range: 30-65 years). 80% (16/20) of the patients were males.

According to literature, mean age of presentation of glioma was ranging from 44 (ZURICH) to 50 (USA), which supports the present study.^{9,10} Though the pathology behind gender predilection is not discovered male predominance was supported by McKinley et al in glial tumors.¹¹

75% of the glial tumors were seen in the temporal lobe and frontal lobe in the present study, which was supported by Larjavaara et al who did a further investigation on the role of the anatomical site in prognosis.¹²

All the patients began adjuvant treatment within 4 weeks of surgery. All the patients received a full dose of radiation therapy without any treatment interruptions. The treatment was relatively well tolerated with none of the patients developing grade III neurotoxicity. All the patients received a planned dose of TMZ without any treatment interruptions and dose modifications. Hemograms done during the concurrent phase of treatment showed that none of the patients had grade 3 hematological toxicity. The 5/20 patients complained of parosmia and 10/20 reported a moderate loss of appetite and nausea in 7/20 patients during the adjuvant course of TMZ (Table 1).

In contrast to present study findings, 43% had to discontinue similar chemotherapy due to a deterioration of blood cell count, worsening of general health status, and liver damage in a retrospective study done by Niewald et al.¹³

Jalali et al also did a similar study in 20 pediatric age group cases where they had grade-III/ IV toxicity during the concurrent RT-TMZ phase included thrombocytopenia in 3 patients, leucopenia in 2, and vomiting in 7 patients.¹⁴

Response rates as assessed using MRI post chemoradiation (by MacDonald’s criteria) revealed that 40% had complete response while 35% of patients had a partial response and 25% had stable disease. The 3 patients who had grade II disease had a complete response after complete treatment (Table 2).

The complete response rate was seen in 27%, and partial in 33% in a prospective multicenter study done by Young-Hoon et al among WHO grade III gliomas, which coincides with the present study.¹⁵

At a median follow-up of 10 months, 75% of patients had disease progression-free survival and 1-year overall survival was 95% (Table 3).

Young-Hoon et al showed 74.2% of disease progression-free survival in their study population at 12months follow-up, and 96.8% overall survival rate, which is almost similar to the present study.¹⁵ Hwang et al had 71.4% of disease progression-free survival in their study population at 12 months follow-up, and 84% overall survival rate, which supports present study (Table 4).¹⁶

In recent years, it was shown that the survival of patients with anaplastic glioma was found to be strongly dependent on the presence or absence of the 1p/19q co-deletion.

Sequential radiation with PCV did not improve survival in non-co-deleted patients in the RTOG 9402 and EORTC 26951 studies.^{17,18} Survival was similar in patients who received chemotherapy with either PCV or TMZ to radiation alone in the NOA-04 study.¹⁹ Results of the phase III CATNON study will be required to confirm the role of TMZ in the management of non-co deleted anaplastic gliomas.²⁰ Preliminary results showed a survival benefit of adjuvant TMZ in non co deleted anaplastic gliomas.

Limitations

In the present study, prognostic factors such as molecular characteristics of the tumors (i.e., O6 -methylguanine-DNA-methyltransferase, MGMT, promoter methylation

or isocitrate dehydrogenase 1, IDH1, mutation, 1p/19q co-deletion) were not done to explore differences in survival and the sample size is small and with shorter follow up.

CONCLUSION

TMZ concurrently during radiation as well as in adjuvant setting has become standard of care for the management of GBM and its use has been widely extrapolated to grade III gliomas. TMZ combined with radiation was well tolerated in our set of patients with grade III gliomas without any significant toxicity. TMZ is given concurrently with radiation resulted in a 40% complete response rate. At a median follow-up of 10 months, 1 year progression-free survival and 1-year overall survival were 75% and 95% respectively.

Funding: No funding sources

Conflict of interest: None declared

Ethical approval: The study was approved by the Institutional Ethics Committee

REFERENCES

- GBD 2016 Brain and Other CNS Cancer Collaborators. Global, regional, and national burden of the brain and other CNS cancer, 1990-2016: a systematic analysis for the Global Burden of Disease Study 2016. *Lancet Neurol.* 2019;18(4):376-93.
- Wesseling, P, and D Capper. WHO 2016 Classification of gliomas. *Neuropathol Appl Neurobiol.* 2018;44(2):139-50.
- Dong X, Noorbakhsh A, Hirshman BR, Zhou T, Tang JA, Chang DC et al. Survival trends of grade I, II, and III astrocytoma patients and associated clinical practice patterns between 1999 and 2010: A SEER-based analysis. *Neurooncol Pract.* 2016;3(1):29-38.
- Altwaairgi AK, Raja S, Manzoor M, Aldandan S, Alsaed E, Balbaid A et al. Management and treatment recommendations for World Health Organization Grade III and IV gliomas. *Int J Health Sci (Qassim).* 2017;11(3):54-62.
- Stupp R, Hegi ME, Mason WP, van den Bent MJ, Taphoorn MJ, Janzer RC et al. Effects of radiotherapy with concomitant and adjuvant temozolomide versus radiotherapy alone on survival in glioblastoma in a randomized phase III study: 5-year analysis of the EORTC-NCIC trial. *Lancet Oncol.* 2009;10:459-66.
- Stewart LA. Chemotherapy in adult high-grade glioma: A systematic review and meta-analysis of individual patient data from 12 randomised trials. *Lancet.* 2002;359:1011-8.
- Yung WK, Prados MD, Yaya-tur R, Rosenfeld SS, Brada, Friedman HS et al. Multicenter phase II trial of Temozolomide With anaplastic astrocytoma or anaplastic oligoastrocytoma at first relapse. *J Clin Oncol.* 2015;17:2762-71.
- Macdonald DR, Cascino TL, Schold SC Jr, Cairncross JG. Response criteria for phase II studies of supratentorial malignant glioma. *J Clin Oncol.* 1990;8(7):1277-80.
- Ostrom QT, Gittleman H, Stetson L, Virk SM, Barnholtz-Sloan JS. Epidemiology of gliomas. *Cancer treat Res.* 2015;163:1-14.
- Tian M, Ma W, Chen Y, Yu Y, Zhu D, Shi J. Impact of gender on the survival of patients with glioblastoma. *Biosci Rep.* 2018;38(6):BSR20180752.
- McKinley BP, Michalek AM, Fenstermaker RA, Plunkett RJ. The impact of age and sex on the incidence of glial tumors in New York state from 1976 to 1995. *J Neurosurg.* 2000;93(6):932-9.
- Larjavaara S, Mäntylä R, Salminen T, Haapasalo H, Raitanen J, Jääskeläinen J et al. Incidence of gliomas by anatomic location. *Neuro Oncol.* 2007;9(3):319-25.
- Niewald M, Berdel C, Fleckenstein J, Licht N, Ketter R, Rube C. Toxicity after radiochemotherapy for glioblastoma using temozolomide--a retrospective evaluation. *Radiat Oncol.* 2011;6:141.
- Jalali R, Raut N, Arora B, Gupta T, Dutta D, Munshi A et al. Prospective evaluation of radiotherapy with concurrent and adjuvant temozolomide in children with newly diagnosed diffuse intrinsic pontine glioma. *Int J Radiat Oncol Biol Phys.* 2010;77(1):113-8.
- Young-Hoon K, Park CK, Cho WH, Kim IA, Moon S, Choe G et al. Temozolomide during and after radiation therapy for WHO grade III gliomas: preliminary report of a prospective multicenter study. *J Neurooncol.* 2011;103(3):503-12.
- Hwang K, Kim TM, Park CK, Chang JH, Jung TY, Kim JH et al. Concurrent and Adjuvant Temozolomide for Newly Diagnosed Grade III Gliomas without 1p/19q Co-deletion: A Randomized, Open-Label, Phase 2 Study (KNOG-1101 Study). *Cancer Res Treat.* 2020;52(2):505-15.
- Van Den Bent MJ, Brandes AA, Taphoorn MJ, Kros JM, Kouwenhoven MC, Delattre JY et al. Adjuvant procarbazine, lomustine, and vincristine chemotherapy in newly diagnosed anaplastic oligodendroglioma: long-term follow-up of EORTC brain tumor group study 26951. *J Clin Oncol.* 2013;31:344-50.
- Cairncross G, Wang M, Shaw E, Jenkins R, Brachman D, Buckner J et al. Phase III trial of chemoradiotherapy for anaplastic oligodendroglioma: long-term results of RTOG 9402. *J Clin Oncol.* 2013;31:337-43.
- Wick W, Hartmann C, Engel C, Stoffels M, Felsberg J, Stockhammer F et al. NOA-04 randomized phase III trial of sequential radiochemotherapy of anaplastic glioma with procarbazine, lomustine, and vincristine or temozolomide. *J Clin Oncol.* 2009;27:5874-80.
- van den Bent MJ, Baumert B, Erridge SC, Vogelbaum MA, Nowak AK, Sanson M, et al.

Interim results from the CATNON trial (EORTC STUDY 26053-22054) of treatment with concurrent and adjuvant temozolomide for 1p/19q non-co-deleted anaplastic glioma: a phase 3, randomised, open-label intergroup study. *Lancet.* 2017;390:1645-53.

Cite this article as: Darisi NCS, Konakalla VLA, Koyyala VPB. An institutional evaluation of radiotherapy with concurrent and adjuvant temozolomide exclusively in grade III gliomas. *Int J Res Med Sci* 2021;9:3565-70.