

Original Research Article

Evaluation of functional outcome of metacarpal fractures managed by operative techniques: a hospital based study

Amit Kumar^{1*}, Sanjeev Gupta^{1, 2}, Vinay Badyal²

¹Department of Orthopaedics, GMCH, Jammu, Jammu and Kashmir, India

²Department of Oral Medicine and Radiology, Oracare Clinic, Jammu and Kashmir, India

Received: 01 November 2021

Revised: 11 November 2021

Accepted: 12 November 2021

*Correspondence:

Dr. Amit Kumar,

E-mail: amitsharma88513@gmail.com

Copyright: © the author(s), publisher and licensee Medip Academy. This is an open-access article distributed under the terms of the Creative Commons Attribution Non-Commercial License, which permits unrestricted non-commercial use, distribution, and reproduction in any medium, provided the original work is properly cited.

ABSTRACT

Background: Metacarpal fractures comprise approximately 35.5% of cases in daily emergencies, mostly due to road traffic accidents, fall, and assault. The main goal of treatment is to achieve the strong bony union without any functional disability. Aim of the study was evaluation of functional outcome of metacarpal fractures managed by operative techniques and to compare the efficacy of different operative techniques.

Methods: A total of 50 patients managed by various operative techniques by using k-wires, screws and plates. Functional outcome was assessed by using total active movement (TAM) and disabilities of the arm, shoulder and hand (DASH) scoring system at 6th week, 3rd month and at 6th month.

Results: A total 47 fractures united and three fractures mal-united at the time of final assessment. Overall excellent and good results were achieved in 94% cases.

Conclusions: Our finding suggests that open reduction and internal fixation with k-wire is most preferable method among all other operative techniques.

Keywords: Metacarpal bones, TAM, DASH

INTRODUCTION

Hand is one of the most important part in the human body. Its anatomy is complex because it has multiple joints and different tendons and ligaments are attached to it.¹

Around 10% hand fractures of all the fractures reporting to the emergency room and outpatients department. Metacarpal fractures comprise between 18–44% of all hand fractures.² In most of the cases, metacarpal fractures are work related and commonly seen in younger age group.³ Proper management of metacarpal fractures are very important as any complication can result in functional deformity. These days various fixation techniques are in use like percutaneous pinning, cerclage wiring, plating, lag screws, tension band wires and external fixators. Out of these K-wire fixation is popular choice due to simplicity

of the procedure and the minimal soft tissue interference.⁴ The functional outcome and result of the management of hand fracture is of predominant importance, rather than fracture healing being the only isolated goal. The purpose of our prospective study is to evaluate the functional outcome of metacarpal fractures which are managed by different operative techniques like K-wires, plates and screws.

Aims and objectives

Aims and objectives of the study were: to evaluate the functional outcome of metacarpal fracture managed by operative methods; and to compare the efficacy of different operative techniques by k-wires, screws and plates in the management of metacarpal fractures.

METHODS

All the cases of metacarpal fracture admitted under department of orthopaedics in GMC, Jammu included in the study. This prospective study was conducted over a period of 12 months from November 2019 to October 2020. The data was analysed by using statistical package for the social sciences (SPSS) software program. A written informed consent taken from all the patients for their inclusion in the study.

Inclusion criteria

Patients with age >18 years, of both genders, and trauma to hand less than 2-weeks-old were included in the study.

Exclusion criteria

Patients not giving consent, patients reporting two weeks after trauma of hand, age <18 years, pathological fractures, and intra-articular fractures were excluded.

Operative management

Indications for operative management include: displaced irreducible fractures, shortening greater than 6 mm, angulation 30-40 degrees in small/ring finger or >10 degree in middle and index finger, malrotation, segmental fractures, and multiple metacarpal fracture.

Surgical techniques

Techniques like K-wires fixation, plate fixation, and screw fixation were used.

Post-operative care

Post-operative care like post-operative AP, lateral and oblique views were obtained to check the reduction and implant safety were included.

Follow up and rehabilitation protocols

Passive as well as active finger movements encouraged. Patient was recalled on 6 weeks to check for any kind of complications. Further post-operative visits were rescheduled on 3rd and 6th month. Functional outcome of the patient was evaluated by total active movement (TAM) and disabilities of the arm, shoulder and hand (DASH) scoring system.

Functional evaluation of outcome measured by TAM scoring system at 6 weeks, at 3 months and at 6 months.

TAM scoring system

Union of the fracture (5 points) assessed clinically as well as radiologically and 5 points is assigned to union. Zero points for points for non-union.

The functional status of the involved ray (finger) was assessed on the basis of TAM of the individual digits. TAM is the sum total of the active flexion range at the metacarpophalangeal, proximal interphalangeal and distal interphalangeal joints in one digit.

The functional results graded according to the following modification of the criteria laid down by the American society for surgery of the hand (Table 1).

Table 1: TAM scoring criteria by American Society for surgery of the hand.

TAM scoring	Criteria
TAM ≥2100	Excellent
TAM 1800-2100	Good
TAM 1500-1800	Fair
TAM <1500	Poor

RESULTS

Present study includes 50 patients managed by different operative methods like K-wires, screws and plates. Out of 50 patients 40 were males and 10 were females. Age of the patients involved in the study was above 18 years and maximum number of patients belong the age group 19-30 years (Figure 1).

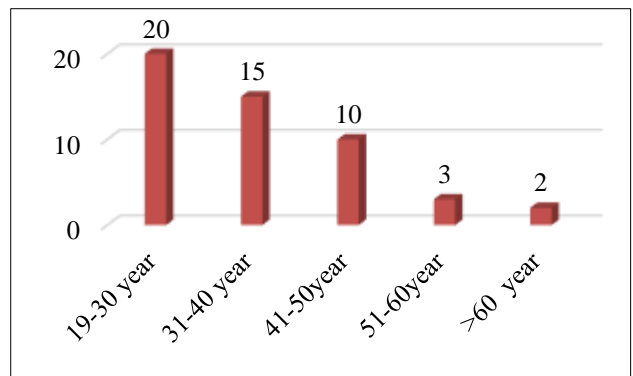


Figure 1: Age distribution of study participants.

Male dominated the study. (80% were male). In 56% cases right hand was involved. Most common mechanism of injury was road traffic accident and blunt trauma. Closed fracture cases (40 patients) were more as compare to open fracture (10 patients). 5th metacarpal (24 cases) was more commonly involved. Most common fracture pattern was transverse and shaft of metacarpal was most commonly involved. Out of 50 patients, 32 patients were treated with K-wires, 6 patients treated with screws and 12 patients treated with plates. 5th metacarpal was most commonly involved.

Final assessment was done at 6 months by assessing the patient clinically as well as radiographically. 47 fractures were united and 3 fractures mal-united at the time of assessment.

Functional outcome of the patient was evaluated by using TAM and DASH scoring system (Tables 2 and 3). None of the patient in this study had any neurovascular injury. Only 3 patients had associated tendon injuries which simultaneously repaired.

Table 2: Functional result by using TAM.

Grade	Tam score	No. of cases	%	Average TAM
Excellent (5 points)	>210 degree	30	60	240 degree
Good (3 points)	180-210 degree	16	32	196 degree
Fair (1 point)	150-180 degree	2	4	166 degree
Poor (0 point)	< 150 degree	2	4	100 degree
Total		50	100	

Table 3: Final result by DASH scoring system.

Quick DASH score	Number of patients	%
<20	28	56
21-25	15	30
26-30	5	10
>30	2	4
Total	50	100

All the patients showed complete radiological union at 6 months. None of the patient in our study had any neurological injury. Superficial infections was seen only in three patients which was managed by antibiotics and dressing.

DISCUSSION

Metacarpal injuries are so common and frequently encountered in the orthopedic outpatient department (OPD). These fractures should be treated with proper caution to prevent any kind of problem related to the normal function of hand. In most of the cases these fractures are managed by conservative method with plaster casting/ slab. In 1928, Lambotte first time described the details regarding surgical treatment of fractures of metacarpals and other fractures around hand.⁵ Early treatment options of metacarpal fractures were limited. It is only limited to closed reduction and its results were usually unsatisfactory. Due to open reduction and internal fixation by different methods leads to satisfactory results.⁶⁻⁸ Functional outcome of small bones of hand fracture depends on severity of injury and its management by proper technique.⁹ The functional outcome of hand is more important than only fracture healing.¹⁰

Shehadi et al reported that return in total range of motion can be achieved upto 100% of metacarpal fracture fixed with external fixator. This mode of fixation is useful in compound metacarpal fractures with bone loss. But the

routine use of external fixator is discouraged as there is loosening of construct following pin tract infection leading to loss of fixation and there is difficulty in constructing and applying the fixator.¹¹ In the study of 21 metacarpal fracture, a J shaped nail formed from a curved 2.0 mm diameter K-wire bent sharply at the proximal end was found to be useful in the neck or transverse shaft fracture of the metacarpals without concomitant injuries such as severe soft tissue damage.¹²

In a study of 52 consecutive closed, displaced, extra-articular metacarpal fractures, results of intramedullary nail (IMN) fixation were compared with those of plate screw (PS) fixation. No significant differences in clinical outcomes were found, but the incidence of loss of function, penetration to the metacarpal- phalangeal joint, and secondary surgery for hardware removal in the operating room were much higher in the IMN group.¹³

Earlier, these metacarpal fractures were managed only conservatively and surgical treatment were done only in unstable fracture cases because of limited treatment options. These days we can do surgical treatment with intramedullary K-wiring, transverse K-wiring, Bouquet techniques, cerclage, mini external fixators, screw fixation (lag principle) and fixation with plate and screws and many more.¹⁴

Number of studies have been done in an effort to provide optimal treatment option for unstable metacarpal fractures. The principal goal of the treatment is to achieve the rigid bony union and to improve the hand movement without any kind of stiffness. However clear cut indications for conservative or surgical treatment of metacarpal fractures are not defined in the literature. Surgery is usually indicated for the fractures that have significant hand functional disability or cosmetic issue.¹⁵ K-wiring is a popular method among orthopaedic surgeons worldwide for metacarpal bone fractures and using a K-wire has a benefit as it can be used as a joystick to help in reducing fracture intra-operatively, however if the K-wire is not rigid enough it may lead to loss of reduction subsequently and may be complicated by pin tract infection or pin breakage.¹⁶

Metacarpal screw fixation has been commonly used in the past but it does not produces satisfactory results in long oblique pattern of fracture or a fracture where gross comminution is there.¹⁷ Various studies have compared the functional outcome of metacarpal fractures treated by different methods. Hongyi et al when they compared results of plating versus K-wiring they reported that mean MHQ score was 96.7%.¹⁸

A study by Souer et al showed good functional outcome by total active motion more than 230 degree in 18 of 19 patients for whom plate fixation was done in closed unstable metacarpal fractures.¹⁹ Another study by Gupta et al showed excellent functional outcome with total active

movements more than 230 degree in all of his patients of unstable metacarpal fractures treated with plate fixation.²⁰

Many studies have shown the satisfactory result of metacarpal fracture managed by percutaneous K-wiring for fracture fixation. A study reported good functional outcomes for percutaneous pinning with no functional impairment in K-wire treated patients and our study showed the same results.²¹

Another study by Lee et al concluded that K-wires facilitate early hand mobilization, correct the deformity, and provide good clinical and radiographic outcomes.²²

As in our study, the functional outcome in terms of radiological union is better in plates and screws but in terms of hand movement is much better in K-wire patients. Another study by Kelsch and Ulrich showed that intramedullary K-wire for fixation is generally believed to be the least invasive technique with maximum long-term function.²³

Our study highlights the fact that average TAM score of metacarpal fracture is 225.4 degree. Overall functional results in our study based on TAM criteria of American society for surgery of hand is excellent in 60%, good in 32%, fair in 4% and poor in only 4% cases. The evidence of radiological union is better in case of patients treated plates and screws as compared to K-wire. When we compared the patients postoperatively treated with different methods, we found that range of motion was better in patients treated with K-wires.

Limitations

As in our study, few limitations are there because we have not divided the patients equally in each treatment modality, sample size was limited and no specific criteria for selecting the type of surgical technique.

CONCLUSION

We concluded that surgical treatment in case of unstable metacarpal fractures with screws and plates has less preferable method as compare to K-wire fixation. Open reduction and internal fixation with K-wire produces stable fixation and early mobilization of hand. It is easily available, cost effective and requires less operative time and finally has good functional outcome.

ACKNOWLEDGEMENTS

Authors would like to acknowledge the cooperation of the study participants for their participation in the study.

Funding: No funding sources

Conflict of interest: None declared

Ethical approval: The study was approved by the Institutional Ethics Committee

REFERENCES

1. Kandasamy AA, Pheroz M, Kumar A, Krishna LG, Jain A, Grower R. Fractures of metacarpal bone: evaluation of functional outcome of open reduction and internal fixation with mini locking plate: a hospital based study. *Int J Res Orthop.* 2019;5:519-25.
2. Hove LM. Fractures of the Hand. *Scandinavian J Plastic Reconstructive Surg Hand Surg.* 1993;27(4):317-9.
3. Chung KC, Spilson SV. The frequency and epidemiology of hand and forearm fractures in the United States. *J Hand Surg Am.* 2001;26(5):908-15.
4. Mohammed R, Farook MZ, Newman K. Percutaneous elastic intramedullary nailing of metacarpal fractures: surgical technique and clinical results study. *J Orthop Surg Res.* 2011;6:37.
5. Lambotte A. Contribution a la chirurgie conservatrice de la main doms les traumatismes. *Arch Franco Belges Chir.* 1928;31:759-61.
6. Amidio PC. Fractures of hand and the wrist .In: Jupiter JB (ed) Flynn's hand surgery. William & Wilkins, Baltimore. 1991;122-85.
7. Stern PJ. Fractures of the metacarpals and the phalanges. In: Green DP, editor. *Operative hand surgery, vol 1.* Churchill Livingstone, New York. 1999;711-71.
8. Barton NJ. Fractures of the hand. *J Bone Joint Surg Br.* 1984;66:159-67.
9. Drenth DJ, Klasen HJ. External fixation for phalangeal and metacarpal fractures. *J Bone Joint Surg Br* 1998;80:227-30.
10. Brenwald J. Bone healing in the hand. *Clin Orthop Relat Res.* 1987;214:710.
11. Shehadi SI. External fixation of metacarpal and phalangeal fractures. *J Hand Surg Am.* 1991;16(3):544-50.
12. Itadera E, Hiwatari R, Moriya H, Ono Y. Closed intramedullary fixation for metacarpal fractures using J shaped nail. *Hand Surg.* 2008;13(3):139-45.
13. Ozer K, Gillani S, William A. Comparison of intermedullary nailing versus plate screw fixation of extra articular metacarpal fractures. *J Hand Surg Am.* 2008;33(10):1724-31.
14. Lieber J, Harter B, Schmid E, Kirschner HJ, Schittenbecher PP. Elastic stable intramedullary nailing (ESIN) of pediatric metacarpal fractures: experiences with 66 cases. *European J Ped Surg.* 2012;22(04):305-10.
15. Blazar PE, Leven D. Intramedullary nail fixation for metacarpal fractures. *Hand Clinics.* 2010;26(3):321-5.
16. Hong SJ, Lee HJ, Kim JY, Eo SR, Cho SH. K wire breakage during metalware removal due to a defective K wire shaft. *Arch Plastic Surg.* 2013;40(5):655-7.
17. Crawford GP. Screw fixation for certain fractures of the phalangeal and metacarpal. *JBJS.* 1976;58(4)487-92.

18. Zhu H, Xu Z, Wei H, Zheng X. Locking Plate Alone versus in Combination with Two Crossed Kirschner Wires for Fifth Metacarpal Neck Fracture. *Scientific Rep.* 2017;7:46109.
19. Souer JS, Mudgal CS. Plate fixation in closed ipsilateral multiple metacarpal fractures. *J Hand Surg Eur.* 2008;33(6):740-4.
20. Gupta R, Singh R, Siwach RC, Sangwan SS. Evaluation of surgical stabilization of metacarpal and phalangeal fractures of hand. *Indian J Orthop.* 2007;41(3):224-9.
21. Greeven AP, Bezstarosti S, Krijnen P, Schipper IB. Open reduction and internal fixation versus percutaneous transverse Kirschner wire fixation for single, closed second to fifth metacarpal shaft fractures: a systematic review. *Eur J Trauma Emerg Surg.* 2016;42:169-75.
22. Lee SK, Kim KJ, Choy WS: Modified retrograde percutaneous intramedullary multiple Kirschner wire fixation for treatment of unstable displaced metacarpal neck and shaft fractures. *Eur J Orthop Surg Traumatol.* 2013;23:535-43.
23. Kelsch G, Ulrich C. Intramedullary k-wire fixation of metacarpal fractures. *Arch Orthop Trauma Surg.* 2004;124:523-6.

Cite this article as: Kumar A, Gupta S, Badyal V. Evaluation of functional outcome of metacarpal fractures managed by operative techniques: a hospital based study. *Int J Res Med Sci* 2021;9:3560-4.