

Research Article

Nail fold capillaroscopy in patients of systemic sclerosis and its association with disease severity as evidenced by high resolution computed tomography lung: a hospital based cross sectional study

Majid Jehangir¹, Seema Qayoom², Shazia Jeelani^{2*}, Rahil Yousuf¹

¹Department of Radiodiagnosis and Imaging, Government Medical College, Srinagar, J & K, India

²Department of Dermatology, STD & Leprosy, SKIMS Medical college hospital Bemina, Srinagar, J & K, India

Received: 30 October 2015

Accepted: 13 November 2015

*Correspondence:

Dr. Shazia Jeelani,

E-mail: shazia46@gmail.com

Copyright: © the author(s), publisher and licensee Medip Academy. This is an open-access article distributed under the terms of the Creative Commons Attribution Non-Commercial License, which permits unrestricted non-commercial use, distribution, and reproduction in any medium, provided the original work is properly cited.

ABSTRACT

Background: The specific nail fold capillary (NFC) pattern found in systemic sclerosis (SSc), can be examined using a dermascope, which can prove as a simple and cost effective procedure for early diagnosis and proper management of patients with SSc.

Methods: A case-control study was conducted on 65 subjects – 10 patients with primary raynauds phenomenon (RP), 40 patients with the SSc and 15 age and gender matched controls. Pattern of NFC using a dermascope was studied in all the subjects. HRCT lung was done in all the SSc patients and the findings were correlated with NFC pattern.

Results: Out of the 65 subjects under study, Nail Fold Capillary (NFC) pattern was abnormal in (40/65) 61.54%. NFC changes were seen in all the (100%) patients of SSc. None of the patients with primary raynauds phenomenon had any positive findings on NFC. High resolution computed tomography (HRCT) lung in patients of SSc when correlated with NFC pattern revealed that overall 20 patients (50%) had interstitial lung disease (ILD). Only one patient with early sclerodermoid pattern of NFC showed ILD whereas 55% and 100% of the patients with active and late pattern of NFC respectively showed ILD on HRCT lungs.

Conclusions: Our study serves to show that NFC pattern can be used as a screening tool in patients with history of RP for diagnosis of systemic sclerosis. The study has shown an association between advanced changes as observed in NFC pattern and systemic involvement in SSc patients as evidenced by HRCT lung.

Keywords: Nail Fold Capillaries, Dermascopy, Systemic sclerosis, High resolution computed tomography lung

INTRODUCTION

Systemic sclerosis (SSc) is a chronic multisystem disorder of small vessels and connective tissues that typically affects skin, lungs and esophagus. The disease has a 3:1 female predilection and typically occurs in third to fifth decades of life. Almost all the patients have skin involvement.¹ Raynaud's phenomenon (RP) is an early symptom in the course of SSc and has considerable clinical effect. However, the clinically obvious diagnosis

of RP is sometimes difficult to confirm by technical means and there are still no reliable diagnostic tests.²

Nailfold capillaroscopy using a digital dermascope is a non-invasive diagnostic tool that permits detection of the local microvascular changes in SSc, which are an expression of the systemic vascular changes that characterize the disease.³ Patients with SSc exhibit a typical pattern at NFC characterized by dilatation of

capillary loops, loss of capillaries, distortion and disruption of the orderly appearance of the capillary bed.⁴

Maricq et al, published the first article in arthritis and rheumatism, describing the specific capillaroscopic patterns in SSc as well as the modification of the capillary blood flow during cold exposure, both in primary and secondary RP.⁵ The peripheral microangiopathy in SSc patients may be well recognized and studied by nailfold capillaroscopy, a non-invasive and safe technique, which is well reported to have both diagnostic and prognostic values in the presence of RP.⁶⁻¹¹ Nowadays, abnormal nail fold capillaries has been accepted as the part of new classification criteria for SSc.¹²

Pulmonary involvement in SSc manifests itself as interstitial lung disease (ILD) and Pulmonary hypertension.¹³ About two-thirds of patients suffering from SSc develop scleroderma ILD (SILD).¹⁴ Chest radiography is highly insensitive in detecting and assessing the extent of lung involvement in SSc patients. HRCT has been shown to be more accurate, sensitive and non-invasive method than chest radiography in detecting and characterizing diffuse lung disease in SSc.¹⁵

This study was done to evaluate the NFC pattern in patients of SSc and the results were compared with patients of primary RP and healthy controls. The study also aimed to find any association with systemic disease severity in the ethnically different group of Kashmiri population by correlating the NFC pattern with the findings on HRCT lung.

METHODS

A case-control study was conducted in the departments of Dermatology and Radiodiagnosis of tertiary care teaching hospitals over a period of 18 months from December 2013 to May 2015 in which 40 patients with SSc diagnosed according to the ACR criteria were evaluated and pattern of nail fold capillaries using a dermascope was studied in them, which was compared with 10 patients of primary RP and 15 age- and gender- matched healthy controls. All the subjects were included in the study after an informed written consent and local ethical committee clearance. Inclusion criteria were age group between 15-45 years and subjects agreement to participate in the study. Exclusion criteria were patients of hypertension, diabetes mellitus, thyroid disorders, any malignancy, too young or old subjects and subject's refusal to participate in the study.

The patients were studied by means of a detailed medical history, physical examination, baseline investigations, serology and NFC study in all subjects and skin biopsy, pulmonary function test and pulmonary high resolution computed tomography (HRCT) were done when required. Based on clinical examination and investigations, patients were labelled as having primary

RP or SSc. All the fingers of 50 patients and 15 healthy controls were examined, after proper washing and application of immersion oil to improve visualization of capillaries. The patients were instructed not to remove their cuticles for one month to avoid microtrauma that could jeopardize the examination. The whole nail fold region including the edges was examined carefully with the help of a digital dermascope having the magnification power of 50X and the findings were noted down.

The nailfold capillary changes as detected by capillaroscopy in patients of SSc have been classified as:¹⁶

1. *Early sclerodermoid pattern:* few giant capillaries, few haemorrhages and well preserved capillary distribution.
2. *Active sclerodermoid pattern:* frequent giant capillaries, frequent haemorrhages, moderate loss of capillaries and mild disorganization of capillary architecture.
3. *Late sclerodermoid pattern:* irregular enlargement of capillaries, few or absent giant capillaries and haemorrhages, severe loss of capillaries with extensive avascular areas and disorganized capillary architecture.

HRCT lung was done in all the SSc patients. SILD manifests as ground glass changes, lung fibrosis and honey combing. Presence or absence of these changes was noted and correlated with pattern of NFC. Statistical analysis was done using chi-square test and p value <0.05 was considered statistically significant.

RESULTS

Table 1: Patient distribution of the study group.

Diagnosis	females	males
All subjects	58	7
SSc	37	3
pr. RP	9	1
Controls	12	3

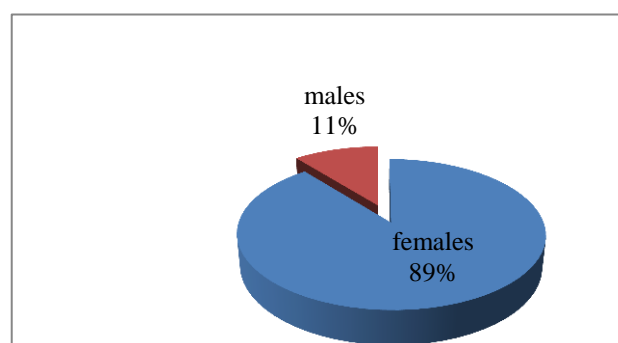


Figure 1: Sex distribution of the study group.

Table 2: NFC changes in subjects under study.

Diagnosis	No. of cases	RP	NFC changes	p value
Primary RP	10	10	0	0.01
SSc	40	37	40	
Controls	15	0	0	
Total	65	47	40	
Percentage (%)	100	72.3	61.54	

Chi-square, df =1

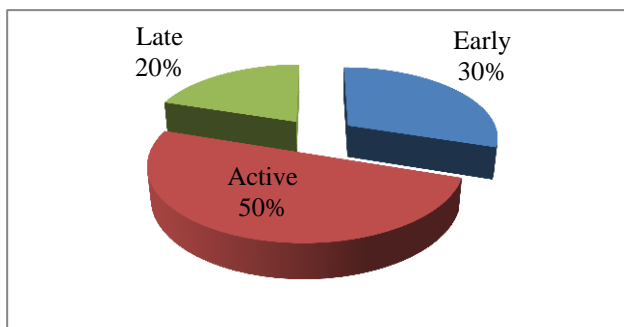


Figure 2: Percentage of different patterns of NFC changes seen in SSc patients.

A total of 65 subjects were seen over a period of 18 months. The study included 10 patients with primary raynauds phenomenon, 40 patients of SSc and 15 healthy controls (Table 1). Of the 40 patients with SSc, age of the patients ranged from 20-45 with the mean (SD) age of 36.22 (9.01). Duration of the disease ranged from 6 months to 9 years with the mean (SD) of 3.36 (2.13) years. Among the 40 SSc patients there were 37 females and 3 males. Figure 1 shows the sex distribution of the whole study group.

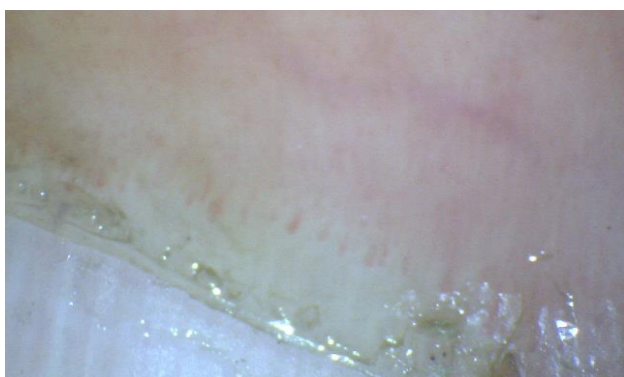


Figure 3: Few capillary haemorrhages, well preserved capillary distribution (Early SD pattern).

The presenting features included Raynaud’s phenomenon in 47 subjects (72.3%). Raynaud’s phenomenon was observed in 37/40 patients of SSc and was essentially absent in the control population. Nail fold capillary details were studied, using a digital dermatoscope and the findings were correlated with clinical diagnosis. The

results are depicted in the Table 2. We observed the specific nail fold capillary pattern of fingers in (40/40) 100% of SSc patients. None of the patients with primary raynauds phenomenon showed any abnormality in nail fold capillary pattern. All the healthy controls also had normal nailfold capillary morphologic features.

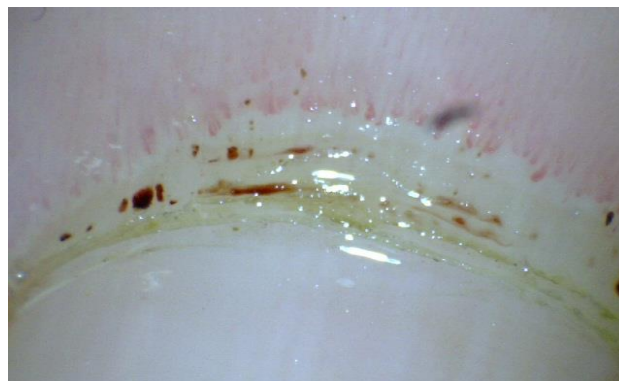


Figure 4: NFC showing frequent giant capillaries, haemorrhages and few capillary dropouts (Active SD Pattern).

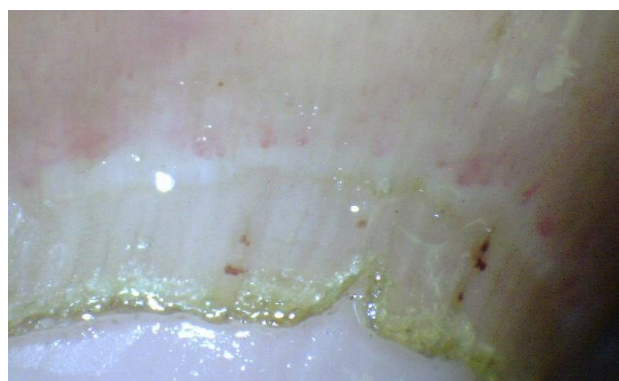
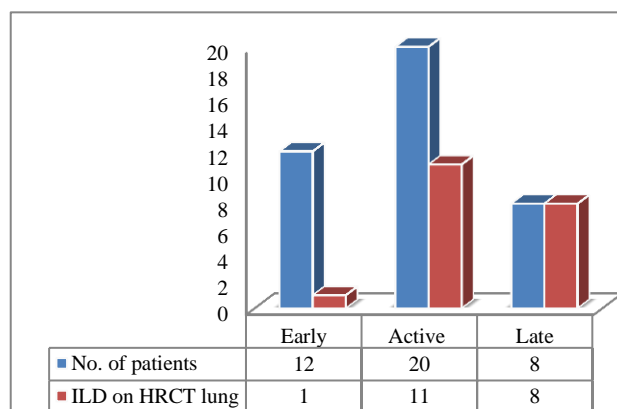


Figure 5: Severe loss of capillaries with extensive avascular areas, few giant capillaries and haemorrhages (Late SD Pattern).



Chi-square test; df = 2; p value = 0.05

Figure 6: Co-relation of pattern of NFC with ILD on HRCT lung in patients of SSc.

The various patterns of NFC changes observed in the patients of SSc are represented in the pie chart below (Figure 2). Figures 3, 4 and 5 show the various sclerodermoid patterns on NFC as seen by the digital dermascope in SSc patients.

In the patients with SSc, HRCT lung showed evidence of interstitial lung disease (SILD) in all the patients with late SD pattern on NFC. Among the patients having active SD pattern on NFC 55% had features suggestive of ILD on HRCT lung. However, among the patients with early SD changes only one had ILD on HRCT lung. Thus we found a positive correlation (p-value = 0.05) between pattern of NFC changes on digital dermoscopy and pulmonary involvement in the form of ILD in the patients of SSc (Figure 6).

DISCUSSION

SSc is characterized by autoimmune changes, microvascular abnormalities and fibrosis of the skin and internal organs. However, it is difficult to get the early diagnosis and assessment of the manifestations that indicate disease activity. NFC is a non-invasive method that allows the early detection of microvascular changes, characterized in 90% of the patients as the scleroderma pattern (SD-pattern).^{7,17} The SD-pattern is characterized by capillary dilation, haemorrhages and avascular areas (vascular deletion) resulting in a reduction in the number of capillaries.

Raynaud's phenomenon (RP) represents the most frequent clinical aspect of microvascular involvement and is a key feature of several autoimmune rheumatic diseases including SSc.¹⁸ In our study, Raynauds phenomenon (RP) was seen in 37/40 (92.5%) of SSc patients. Infact, RP is the most typical manifestation in greater than 90% of patients with SSc.¹⁹

In primary RP, the normal NFC pattern shows a regular disposition of the capillary loops along with the nailbed. On the contrary, in subjects suffering from secondary RP, one or more alterations of the capillaroscopic findings should alert the clinician of the possibility of a connective tissue disease not yet detected. In our study, we found that NFC changes were found in all the patients (40/40) of SSc and none of the patients with primary raynauds phenomenon. Hence, nailfold capillaroscopy can easily distinguish primary from secondary RP. Piotto DG et al have also found that all the patients with SSc had abnormal NFC pattern.²⁰ Similar results have been observed by other studies.^{7,21}

We observed that NFC changes also correlated significantly well (p=0.05) with the presence of lung involvement in SSc patients as evidenced by HRCT lung showing ILD in all the patients with late NFC patterns. Only 8.33% (1/12 SSc patients) and 55% (11/20 SSc patients) of early SD and active SD pattern respectively showed evidence of ILD on HRCT lung. Thus we found

a positive correlation between pattern of NFC changes on digital dermoscopy and pulmonary involvement in the form of ILD. Other studies by Lovy M et al and Sato LT et al have also shown a correlation between NFC abnormalities and cutaneous and visceral involvement in SSc patients.^{4,22} Recently, Corrado et al pointed out the differences in the nailfold pattern between ILD in SSc patients and idiopathic pulmonary fibrosis (IPF) SILD patients have typical capillary loop changes present also in the very early stages of disease, while IPF patients present only minimal capillary alterations.²³ The authors concluded that capillaroscopic changes in patients with lung fibrosis could indicate the first sign of a systemic disease involving the lungs and thus requiring the patient to have periodic checks to detect the appearance of immunological and clinical signs attributable to a connective tissue disorder.²³

CONCLUSION

Assessment of the nail-fold capillaries and of their organization can readily distinguish between a normal capillaroscopic pattern in primary RP and a specific sclerodermoid pattern in secondary RP carrying a very high risk of systemic sclerosis. NFC is easily performed, non-traumatic, and of low cost, being thus useful for the diagnosis and follow up of systemic sclerosis. Apart from its important role as a diagnostic tool for distinguishing between primary and secondary Raynaud phenomenon, NFC also predicts the prognosis of SSc, and also assess the disease severity and systemic involvement. In fact, it can be used as a basic screening tool in the patients of SSc and can readily serve as biomarker of ILD in such patients.

Funding: No funding sources

Conflict of interest: None declared

Ethical approval: The study was approved by the Institutional Ethics Committee

REFERENCES

1. Kreig T, Takehara K. Skin disease: a cardinal feature of systemic sclerosis. *Rheumatology (Oxford)*. 2009;48 (suppl 3):iii14-8.
2. Bergman R, Sharony L, Schapira D. The Handheld Dermatoscope as a Nailfold Capillaroscope instrument. *Arch Dermatol*. 2003;139:1027-30.
3. Fischer A, Meehan RT, Feghali-Bostwick CA, West SG, Brown KK. Unique characteristics of systemic sclerosis sine scleroderma-associated interstitial lung disease. *Chest*. 2006;130(4):976-81.
4. Sato LT, Kayser C, Andrade LE. Nailfold capillaroscopy abnormalities correlate with cutaneous and visceral involvement in systemic sclerosis patients. *Acta Reumatol Port*. 2009;34(2A):219-27.
5. Maricq HR, LeRoy EC. Patterns of finger capillary abnormalities in connective tissue disease by 'wide-

- field' microscopy. *Arthritis Rheum.* 1973;16:619-28.
6. Carpentier PH, Maricq HR. Microvasculature in systemic sclerosis. *Rheum Dis Clin North Am.* 1990;16:75-91.
 7. Maricq HR, LeRoy EC, D'Angelo WA, Medsger TA Jr, Rodnan GP, Sharp GC, et al. Diagnostic potential of in vivo capillary microscopy in scleroderma and related disorders. *Arthritis Rheum.* 1980;23(2):183-9.
 8. Blockmans D, Beyens G, Verhaeghe R. Predictive value of nailfold capillaroscopy in the diagnosis of connective tissue disease. *Clin Rheumatol.* 1996;15:148-53.
 9. Grassi W, Core P, Carlino G, Cervini C. Acute effects of single dose nifedipine on cold-induced changes of microvascular dynamics in systemic sclerosis. *Br J Rheumatol.* 1994;33:1154-61.
 10. Chandran G, Smith M, Ahern MJ, Roberts-Thomson PJ. A study of scleroderma in South Australia: prevalence, subset characteristics and nailfold capillaroscopy. *Aust NZJ Med.* 1995;25:688-94.
 11. Mannarino E, Pasqualini L, Fedeli F. Nailfold capillaroscopy in the screening and diagnosis of Raynaud's phenomenon. *Angiology.* 1994;45:37-42.
 12. Pope JE, Johnson SR. New Classification Criteria for Systemic Sclerosis (Scleroderma). *Rheum Dis Clin North Am.* 2015;41(3):383-98.
 13. Silver RM, Miller KS. Lung involvement in systemic sclerosis. *RheumDis Clin North Am.* 1990;16:199-216.
 14. Gilliland BC, et al. Systemic sclerosis (scleroderma) in: BraunwaldE, Fauci AS, Kasper DL, et al., editors. *Harrison's Principles of Internal Medicine.* New York:McGraw-Hill, 2001.
 15. Goldin JG, LynchDA, StrolloDC. High resolution CT findings in scleroderma-related lung diseases: findings from Scleroderma Lung Study. *Chest.* 2008;134:358-67.
 16. Cutolo M, Sulli A, Pizzorni C, Accardo S. Nailfold videocapillaroscopy assessment of microvascular damage in systemic sclerosis. *J Rheumatol.* 2000;27:155-60.
 17. Russo RA, Katsicas MM. Clinical characteristics of children with Juvenile Systemic Sclerosis: follow-up of 23 patients in a single tertiary center. *Pediatr Rheumatol Online J.* 2007;5:6.
 18. Cutolo M, Sulli A, Secchi ME, Paolino S, Pizzorni C. Nailfold capillaroscopy is useful for the diagnosis and follow-up of autoimmune rheumatic diseases. A future tool for the analysis of microvascular heart involvement? *Rheumatology.* 2006;45(suppl 4):iv43-6.
 19. Khan F. Vascular abnormalities in Raynaud's phenomenon. *Scott Med J.* 1999;44:4-6.
 20. Piotto DG, Len CA, Hilario MO, Terreri MT. Nailfold capillaroscopy in children and adolescents with rheumatic diseases. *Rev Bras Reumatol.* 2012;52(5):722-32.
 21. Nagy Z, Czirjak L. Nailfold digital capillaroscopy in 447 patients with connective tissue disease and Raynaud's disease. *J Eur Acad Dermatol Venereol.* 2004;18:62-8.
 22. Lovy M, Mac Carter D, Steigerwald JC. Relationship between nailfold capillary abnormalities and organ involvement in systemic sclerosis. *Arthritis Rheum.* 1985;28(5):496-501.
 23. Corrado A, Carpagnano GE, Gaudio A, Foschino-Barbaro MP, Cantatore FP. Nailfold capillaroscopic findings in systemic sclerosis related lung fibrosis and in idiopathic lung fibrosis. *Joint Bone Spine.* 2010;77(6):570-4.

Cite this article as: Jehangir M, Qayoom S, Jeelani S, Yousuf R. Nail fold capillaroscopy in patients of systemic sclerosis and its association with disease severity as evidenced by high resolution computed tomography lung: a hospital based cross sectional study. *Int J Res Med Sci* 2015;3:3485-9.