

Case Report

A case of endometrial tuberculosis complicated by Pott's spine with paraplegia

N. A. Wafai¹, Shikha Seth^{2*}, P. S. Singh¹

¹Department of Medicine, U.P. RIMS & R, Saifai, U. P., India

²Department of Obstetrics & Gynaecology, U.P. RIMS & R, Saifai, U. P., India

Received: 15 April 2014

Accepted: 4 May 2014

*Correspondence:

Dr. Shikha Seth,

E-mail: drseth_shikha@yahoo.com

© 2014 Wafai NA et al. This is an open-access article distributed under the terms of the Creative Commons Attribution Non-Commercial License, which permits unrestricted non-commercial use, distribution, and reproduction in any medium, provided the original work is properly cited.

ABSTRACT

Extra-pulmonary tuberculosis has shown an increasing trend in developing countries and accounts for 15-20% of total tuberculosis cases in India. Extra-pulmonary cases are usually diagnosed late due to vague and subtle signs & symptoms at a stage when major irreversible tissue damage had occurred. Tuberculosis is a chronic disease with infection remaining dormant for years in body to get activated whenever the immunity decreases. Spinal and cranial TB has the gravest manifestations, while the abdominal, female genital or pelvic TB poses a challenge because of lack of specific diagnostic tests. Here we are reporting a case of endometrial tuberculosis which was diagnosed very late, followed by treatment default and finally got complicated with Pott's spine with paraplegia due to haematogenous spread. Timely intervention and anti-tubercular treatment improved the symptoms. It stresses on keeping the high suspicion of tuberculosis in unresponsive and persistent general symptoms.

Keywords: Tubercular endometritis, Pott's spine, Non-caseating granuloma, Vaginal discharge

INTRODUCTION

Pulmonary Tuberculosis (TB) is the primary and most common presentation, but extra-pulmonary tuberculosis has shown an increase in developing countries like India even after years of Revised National Tuberculosis Control Programme (RNTCP). Extra-pulmonary TB accounts for 15-20% of the total tuberculosis cases in India (Figure 1). This is commonly due to ignorance about the disease and its complications, free availability of treatment, illiteracy, social taboos, and poor coverage of programs in rural areas due to lack of medical facilities. Among extra-pulmonary cases spinal and cranial TB has the gravest manifestations, while the abdominal, female genital or pelvic TB poses a challenge because of lack of specific diagnostic tests. It is a chronic disease which can disseminate to any organ of the body by direct, haematogenous or lymphatic route, if not detected and treated in early stages, even after years of

primary infection. This report presents a case of paraplegia due to Pott's spine in a postmenopausal woman, secondary to dissemination from undiagnosed chronic tubercular endometritis because of delayed diagnosis and incomplete treatment: a challenging situation in developing countries.

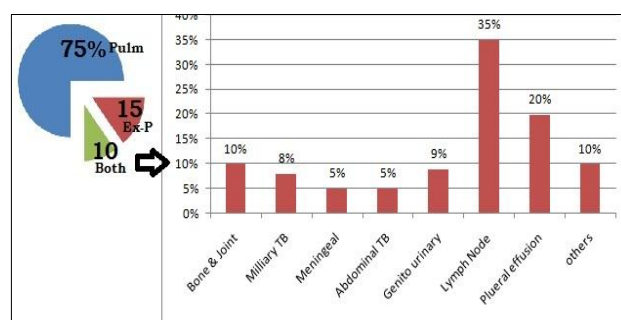


Figure 1: Burden of tuberculosis.

CASE REPORT

A 40 year old P5L5, postmenopausal female got admitted to U. P. RIMS & R with chief complaints of fever, fatigue, severe backache, vaginal discharge and weakness in both of the lower limbs since last 2 weeks.

On evaluation it was found that she was suffering from chronic low back pain, low grade fever, abdominal discomfort and persistent vaginal discharge since last 5-6 months for which she consulted the gynaecologist and orthopedician who did her baseline investigations including lumbo-sacral spine X-ray, which were within normal limits four months back and prescribed antibiotics and analgesics for symptomatic relief. Symptoms persisted and she developed supra-pubic tenderness on deep palpation. On vaginal examination uterine and adnexal tenderness was assessed while pelvic sonography showed collection in uterine cavity with thickened endometrium with few calcified foci. Her Haemoglobin was 9.7 gm% TLC - 13200, DLC - N63 L33, E4 and ESR - 60 mm, RBS - 92 mg%, and liver and kidney functions were within normal limits at that time. In lieu of her symptoms, signs and the sonographic findings she was subjected to endometrial biopsy to rule out the uterine malignancy common in post-menopausal females. Histopathology showed foci of histiocytes, lymphocytes, giant cells, dilated endometrial glands highly suggestive of tubercular endometritis (Figure 2). She was referred to DOTS Centre, where category-I Anti-Tubercular Treatment (ATT) was started. Patient left the treatment after two weeks due to some inadvertent initial symptoms and lost to follow up and reported now with paraplegia.

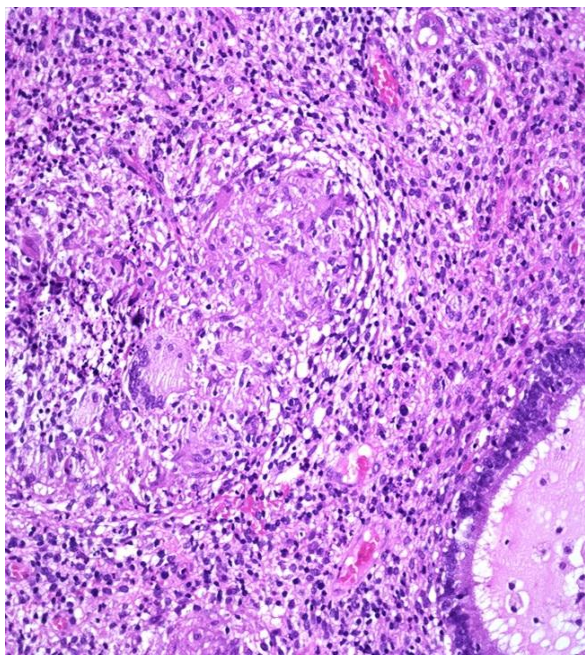


Figure 2: Histology: Non-caseating granuloma, lymphocytic infiltrate, few giant cells and dilated endometrial gland suggestive of chronic tubercular endometritis.

Now during the present admission, she was found sick, pale and febrile but chest, cardiovascular and abdomen were normal on examination. There was significant tenderness in lower dorsal spine but without any gibbus. Neurological examination showed normal higher functions and cranial nerves but both the lower limbs had grade-II power only. There was hypotonia, absent Deep tendon reflexes, non-responding planters along with a sensory level around D10-D12 region. Further investigations showed blood sugar in diabetic range, haemoglobin 6.6 gm% with normocytic normochromic picture with normal liver and renal functions. There was no evidence of retinopathy and 24 hour urine protein was nil.

X-ray imaging showed destruction of D11 and D12 vertebra (Figure 3), which was confirmed on spinal MRI. Neurosurgeon's opinion was taken who later operated on her and laminectomy at D11-D12 and L1 with pedicle screw fixation was done successfully. Per operatively a lot of granulation tissue and extra-medullary pus were found which on histology showed smear of bone with inflammatory cell infiltrate along with epithelioid cells and necrosis highly suggestive of Pott's spine. After surgery lower limb power improved to grade-III and she was again started on anti-tubercular treatment category-II Ante-Tubercular Therapy (ATT) in a fairly good condition.

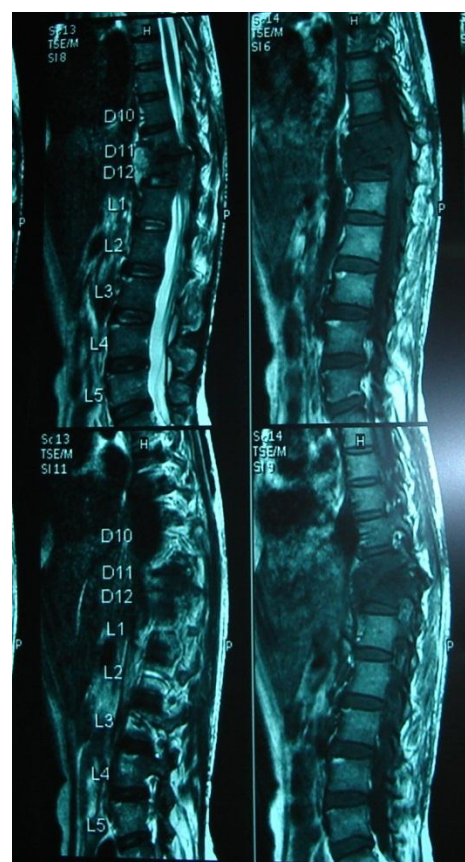

Figure 3: Spinal imaging (MRI) showing vertebral destruction at D11-12.

DISCUSSION

Uro-genital tuberculosis accounts for around 9% of extra-pulmonary tuberculosis in India. Female genital tuberculosis is an uncommon disease in developed countries but still a frequent cause of Pelvic inflammatory disease (PID) in underdeveloped world, which is usually, treated with broad spectrum antibiotics. Pelvic TB develops in approximately 5% of patients of pulmonary TB and is more prevalent in child bearing age. Kajal B Punyashetty et al.² had reported proportion of Tubercular endometritis was 3.8% in his study which was comparable with study of Vishnu Gopal M.³ Fallopian tube is the commonest site of genital tuberculosis leading to infertility in young population but it is difficult to take sample from tubes without damaging them for diagnosis.

Endometrial tuberculosis has various presentations from menorrhagia, irregular menstruation, hypomenorrhoea to amenorrhoea as described by Mukerjee K et al.⁴ and Sathe A et al.⁵ Mondal SK et al.⁶ in their 10 year clinic-pathological study of female genital tuberculosis reported that genital tuberculosis is usually a silent infection however, some symptoms include abdominal discomfort, low backache, pelvic pain, vaginal discharge, irregular menses, menorrhagia and infertility. Later on endometrium lining is destroyed and patient develops secondary amenorrhea due to caseation, improper healing, scarring, fibrosis and adhesions formation within uterine cavity (Asherman's syndrome). Early menopause around 36 years of age in our case may be due to long standing chronic endometritis which was not diagnosed in time and later disseminated to the spine probably haematogenously to present with Pott's spine and paraplegia with the loss of body immune power with age.

Endometrial tuberculosis possess a diagnostic dilemma as cytology and cultures are usually negative due to paucibacillary nature and characteristic granuloma takes up to two weeks to develop and since endometrium is shed every four weeks, the granulomas are poorly formed and often difficult to identify. Novak and Weidroff⁷ suggests that granulomatous endometritis with inflammatory cell infiltration is generally accepted as tubercular origin even in absence of Acid Fast Bacilli (AFB) on cytology or culture negatives. Typical histological feature is non-caseating granulomas composed of epithelioid cells, Langhan's giant cells and peripherally bounded by lymphocytes. Menstrual blood or endometrial tissue N-PCR although costly but a better option for diagnosis of genital tuberculosis as it has 30% sensitivity compared to 5.1% by AFB cytology, 4.2% by culture and 2.4% only by histology.

Bone and joint tuberculosis accounts for around 10% of extra-pulmonary tuberculosis spread haematogenously from the primary site commonly lungs. In our case it probably spread from the prolonged and mistreated genital tuberculosis in the perimenopausal age group due to reduced immunity and association of diabetes mellitus,

ultimately landing into paraplegia which required neurosurgery.

Early diagnosis and complete course under DOTs can provide cure from the tuberculosis but delay in diagnosis and treatment can lead to complete organ damage whether it is reproductive system (tubes and endometrium) leading to infertility and secondary amenorrhoea or the bone. One should not ignore the general symptoms like persistent backache, abdominal discomfort, fever, and discharge per vaginum and consult the physician for complete diagnostic workup. Tuberculosis can affect any organ at any age with subtle symptoms.

CONCLUSION

Pelvic and genital tuberculosis is still a concern in our country which remains under-diagnosed due to nonspecific occult symptomatology and lack of diagnostic tests and generally treated on the lines of chronic Pelvic inflammatory disease. Young infertile cases, persistent or recurrent PID and vaginal discharge despite antibiotics, should be specifically investigated for pelvic tuberculosis and common primary at lungs. Public awareness and high degree of suspicion on clinical findings in TB endemic areas is the key for early detection and to avoid complications.

ACKNOWLEDGEMENTS

We thank all the staff of department of medicine and obstetrics & gynaecology for support and co-operation. Special thanks to Dr. Pinki Pandey, dept. of pathology for histological examination and Dr. Maurya, Neurosurgeon for helping in the management of case.

Funding: No funding sources

Conflict of interest: None declared

Ethical approval: Not required

REFERENCES

1. Niblock AL. Recurrent neck abscesses due to cervical tuberculosis lymphadenopathy in elderly postmenopausal woman post splenectomy: a rare case report. *J Med Case Rep.* 2011;5(1):584.
2. Kajal B Punyashetty, Annand AS, Trupti Vyasrao. Tuberculous endometritis: a worrying recrudescence for fertility. *Int J Biol Med Res.* 2012;3(2):1708-11.
3. Vishnu Gopal M, Raj Baveja, Vatsala Somant. Tuberculous endometritis. *J Obstet Gynaecol India.* 1971;21(1-3):72-3.
4. Mukerjee K, Wagh KV, Agarwal S. Tubercular endometritis in primary sterility. *J Obstet Gynaecol India.* 1967;17:619.
5. Sathe A, Vaidya P, Deshmukh M, Montashow N. Endometrial tuberculosis. *J Obstet Gynaecol India.* 1979;29:199.

6. Mondal SK, Dutta TK. A 10 year clinic-pathological study of female genital tuberculosis and its impact on fertility. *J Nepal Med Assoc.* 2009 Jan-Mar;48(173):52-7.
7. Emil Novak, Edmund R. Novak, James Donald Woodruff. Granulomatous endometritis. In: Emil Novak, Edmund R. Novak, James Donald

Woodruff, eds. *Novak's Gynaecological and Obstetric Pathology.* 13th ed. Philadelphia: Saunders; 2002: 973-1067.

DOI: 10.5455/2320-6012.ijrms20140810

Cite this article as: Wafai NA, Seth S, Singh PS. A case of endometrial tuberculosis complicated by Pott's spine with paraplegia. *Int J Res Med Sci* 2014;2:1157-60.