

Case Report

Unusual branching pattern of external carotid artery in the left carotid triangle

Gangadhara^{1,*}, Shakuntala Rao N², Manivannan K³, Krishna Rao H R⁴

¹Associate Professor of Anatomy, ²Professor of Anatomy, ³Assistant Professor of Anatomy, ⁴Professor & HOD of Anatomy, PES Institute of Medical Sciences and Research, Kuppam, Andhra Pradesh, India

Received: 22 August 2014

Accepted: 6 September 2014

***Correspondence:**

Dr. Gangadhara,

E-mail: drganga1980@gmail.com

Copyright: © the author(s), publisher and licensee Medip Academy. This is an open-access article distributed under the terms of the Creative Commons Attribution Non-Commercial License, which permits unrestricted non-commercial use, distribution, and reproduction in any medium, provided the original work is properly cited.

ABSTRACT

During the routine dissection of the neck for the first MBBS students, we have found the abnormal branching of the external carotid artery in the carotid triangle. The external carotid artery is a terminal branch of the common carotid artery arises at the level of superior border of the thyroid cartilage in the carotid triangle. It supplies the structures of head and neck regions by its eight branches. The knowledge of variations is very important for the general, head & neck, ENT and oncosurgeons, to avoid unforeseen complication in the form of bleeding by injuring the abnormal arteries. It is also important for the vascular surgeons and radiologists while performing the procedures on the arteries.

Keywords: External carotid artery, Superior laryngeal artery, Thyrolingualfacial trunk, Superior thyroid artery

INTRODUCTION

Common carotid artery divides into external and internal carotid arteries at the level of upper border of the thyroid cartilage; corresponding vertebral level is C3-C4 junction. This bifurcation can sometimes be at a higher level. At its origin the external carotid artery is in the carotid triangle and lies anteromedial to the internal carotid artery and has eight named branches distributed to the head and neck, among which five branches arise in the carotid triangle namely ascending pharyngeal artery, superior thyroid artery, lingual artery, occipital artery and facial artery. Occasionally superior thyroid artery may arise directly from the common carotid. Lingual artery provides the chief blood supply to the tongue and the floor of the mouth. It often arises with the facial; or less often, with the superior thyroid artery. Facial artery supplies few structures in the submandibular region and mainly face. Superior laryngeal artery is normally derived from the superior thyroid artery. However sometimes it arises directly from the external carotid artery and supplies the larynx from the tip of the epiglottis down to the inferior margin of thyroarytenoid.¹

The structures of Head and neck region are majorly supplied by the external carotid artery and their branches. The variations in the branching pattern are very important to note for the general surgeons, ENT surgeons, Oncosurgeons vascular surgeons and radiologist for the diagnosis and interventions.

CASE REPORT

During routine academic dissection of around 65 year old female Indian cadaver, well embalmed by formalin fixation method, used for teaching of first year MBBS students in the department of anatomy of our college, we have found the variation in the branching pattern carotid arterial system in the carotid triangle on the left side. The carotid triangle was meticulously dissected and traced the variant arteries for further course and distribution and documented by taking photographs immediately.

The left common carotid artery was dividing into external and internal carotid arteries as terminal branches. The division was around 2 cms above the usual level of termination i.e. above the level of superior border of the thyroid cartilage of larynx.

The superior laryngeal artery was arising from the external carotid artery immediately above the origin of external carotid artery. It was slightly tortuous and was coursing forwards and downwards and medially, and accompanied with the internal laryngeal nerve after a short course, finally both the structures have pierced the thyrohyoid membrane and entered the larynx.

The superior thyroid, lingual and facial arteries were arising together by forming the common trunk called thyrolinguofacial trunk, which was arising from the external carotid artery anteromedially about 1cm above the bifurcation of common carotid artery at the level of tip of the greater cornua of hyoid bone. The superior thyroid artery was arising as a first branch of the common trunk above the level of greater cornua of hyoid bone which was very thin and had a long course with variable relation with external laryngeal nerve to reach the thyroid gland.

The common trunk was measuring around 16mm and coursing upwards and anteriorly. It was ending by dividing in to lingual artery and facial artery medial to the digastric muscle and loop of hypoglossal nerve. The lingual immediately after its origin, it had a course of downward loop, the convexity was facing down wards. Then it ran upwards and entered in to the submandibular region. Further course and branching was normal. The facial artery was directed upwards and reached the posterior end of submandibular gland. Further course and branching of facial artery was normal.

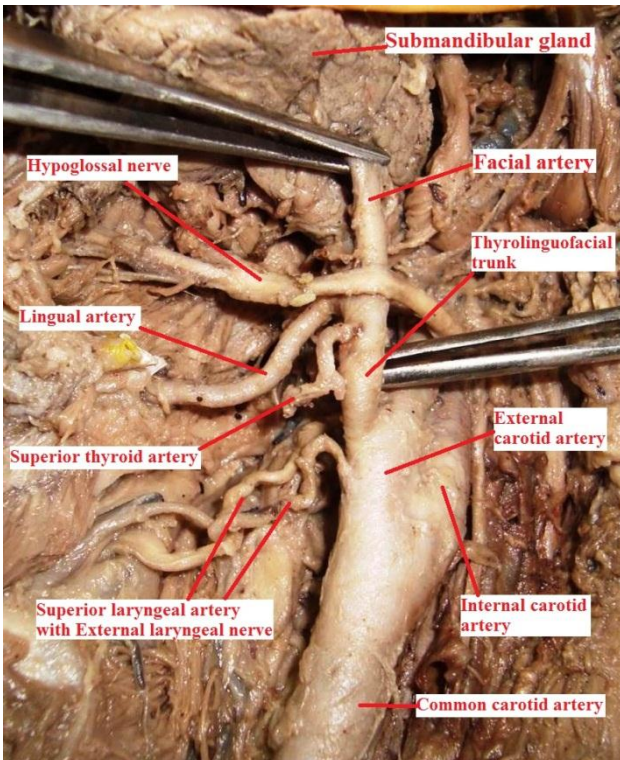


Figure 1: Showing the branching pattern of the external carotid artery in the carotid triangle.

DISCUSSION

Common carotid artery divides into external and internal carotid arteries at the level of upper border of the thyroid cartilage; corresponding vertebral level is C3-C4 junction. This bifurcation can sometimes be at a higher level.¹ Lucev et al. conducted a study to assess the normal level of carotid bifurcation and concluded that in 50% of cases the level of the bifurcation corresponded to the superior border of the thyroid cartilage. Carotid bifurcation occurred in 25% at the level of the inferior border of the hyoid bone. A higher level of bifurcation, opposite the superior border of the hyoid bone was found in 12.5%. Bifurcation appeared at the level of the inferior border of the thyroid cartilage in 12.5%.² Sanjeev et al. have found the higher division of common carotid artery (16.22% cases) & Lower division of common carotid artery (27.02% cases).³

Variations in the branches of external carotid artery are very common. Because of high probability of variations in the arteries of carotid and digastric triangles, a number of studies have been carried out on these arteries and a wide range of variations have been reported. Zümre O et al conducted a study on the distribution of the external carotid artery trunks in human foetuses showed a linguofacial trunk in 20%, thyrolingual trunk in 2.5% and a thyrolinguofacial trunk in 2.5% of the cases.⁴ Jitendra P Patel et al have recorded one case of thyrolinguofacial trunk (1%) arises from anterior surface of external carotid artery on left side & three cases of thyrolingual trunk (3%) origin from anterior surface of external carotid artery.⁵ Livini observed the origin of superior thyroid artery in common with facial and lingual artery in 1.5% of cadavers.⁶ Porwal SATISHKUMAR S et al have found the external carotid artery giving a common trunk at the level of tip of greater horn of hyoid bone, which later divided into superior thyroid artery, lingual artery and facial artery after a short course.⁷ Takkallapalli Anitha et al have observed the thyrolinguofacial trunk in 2% of the cadavers.⁸ Vishnu Gupta et al have found thyrolinguofacial trunk in one cadaver and linguofacial trunk in 3 cadavers, out of 30 cadavers (3.3%).⁹ Ozgur et.al. classified the origin of these arteries which were arises from the external carotid artery in four types and reported their incidences. The separate origins of the arteries were defined type 1 (in 90% of the cases), the lingual facial trunk as type 2 (7.5%), thyrolingual trunk as a type 3 (2.5%) and thyrolinguofacial trunk as type 4 (2.5%).¹⁰

Superior laryngeal artery usually arises from the superior thyroid artery but sometimes it takes direct origin from external carotid artery in 32% of cases.¹¹ Soubhagya R. Nayak et al have studied the origin of superior laryngeal artery and classified the pattern in to four types in which the type III is Superior Laryngeal Artery originates directly from the external carotid artery (12.1%).¹² Lang et al have found that the superior laryngeal artery was a branch from the external carotid artery only in 6.8% of

cases.¹³ Harsha. B. R et al have reported the bilateral origin of superior laryngeal artery from the external carotid artery.¹⁴ Other authors also have found the superior laryngeal artery arising from the external carotid artery.¹⁵ Dr. Padmalatha K et al have found the Superior laryngeal artery taking origin from the main trunk of external carotid artery between superior thyroid artery and common linguofacial trunk similar to our case.¹⁶

The bulk of the blood to the human larynx is delivered via the superior laryngeal artery. The variation in the superior laryngeal artery origin and morphology is important during the partial laryngectomy and reconstruction surgery of the larynx, laryngeal transplantation.

The knowledge of variations in the branching of external carotid artery and their identification is very important for the procedures like carotid catheterization, reconstruction of aneurysms, carotid endoplasty, carotid endarterectomies and diagnostic carotid angiograms. Surgeons should aware of these abnormal branching of external carotid artery while performing radical neck dissections, thyroidectomy, laryngectomy, glossectomy and ligation of external carotid artery during uncontrollable epistaxis. We the anatomists feel proud to add the additional information to the existing knowledge in the text books which helps surgeons mainly.

Funding: No funding sources

Conflict of interest: None declared

Ethical approval: Not required

REFERENCES

1. Susan Standring. Gray's anatomy: anatomical basis of clinical practice 40th edition, Churchill Livingstone Elsevier; 2008: 444-447.
2. Lucev N, Bobinac D, Maric I, Drescik I. Variations of the great arteries in the carotid triangle. Otolaryngol Head Neck Surg 2000; 122: 590-1.
3. Sanjeev IK, Anita H, Ashwini M, Mahesh U, Rairam GB. Branching pattern of external carotid artery in human cadavers. J Clin Diagn Res. 2010; 4: 3128-3133.
4. Zümre O, Salbacak A, Çiçekcibai AE, Tuncer I, Seker M. Investigation of the bifurcation level of the common carotid artery and variations of the branches of the external carotid artery in human fetuses. Ann Anat 2005; 187: 361-9.
5. Jitendra P Patel , Rashmikant V Dave , Ritesh K Shah , Sanjay D Kanani , Ashok B Nirvan A Study Of Superior Thyroid Artery In 50 Cadavers Int J Biol Med Res. 2013; 4(1): 2875-2878.
6. Livini studio morfologicadelle arteria tiroidee sperm. Arg Biel Norma Patol; 1900; 34; 42, 129.
7. Porwal SATISHKUMAR S, Bidwe ARCHANA S, Joshi DEEPAK S. Variant formation of external jugular vein and branching pattern of external carotid artery. International Journal of Anatomical Variations (2013) 6: 140-142.
8. Takkallapalli Anitha, Dattatray Dombe, Krishnamurthy Asha, Sanjay Kalbande. Clinically relevant variations of the superior thyroid artery: An anatomic guide for neck surgeries Int J Pharm Biomed Sci 2011, 2(2), 51-54.
9. Vishnu Gupta1, Rakesh Agarwal2. Anomalous Branching Pattern of the External Carotid Artery in Cadavers. International Journal of Scientific Study April 2014;2.
10. Ozgur Z, Govsa F, Ozgrs T. Assessment of origin of characteristics of the front branches of ECA. J Cranio Fac Surg. 2008, 19, 1159-1166.
11. Ronald A Bergman; Compendium of Human anatomic variations; Urban & Schwarzenberg; Baltimore; 1988 ; 65.
12. Soubhagya R. Nayak, Ashwin Krishnamurthy, Latha V. Prabhu, Bhagath Kumar Potu, Ishwar B. Bagoji, Jiji PJ and Ganesh Kumar Chettiar. Variable Origin of the Superior Laryngeal Artery and Its Clinical Significance Al Ame en J Med S c i (2 011)4 (1):6 9-74.
13. Lang J, Nachbaur S, Fischer K, Vogel E. The superior laryngeal nerve and the superior laryngeal artery. Acta Anat (Basel) 1987; 130:309-318.
14. Harsha. B. R, Dakshayani. K.R A Bilateral Anomalous Origin of Superior Laryngeal Artery from External Carotid Artery. Anatomica Karnataka, Vol-6, (3), Page 94-97 (2012).
15. Rao Mohandas K.G. and Rao Asutosh S. Unusual Origin of the Arteries in the Carotid Triangle of the Neck: A Case Report and Literature Review The Open Anatomy Journal, 2009, Volume 1 24-27.
16. Padmalatha K., Prakash S., Balachandra N., Mamatha Y., B.R. Rarnesh. Multiple variations in the branching pattern of external carotid artery. Case report Anatomica Karnataka:50-5.

DOI: 10.5455/2320-6012.ijrms20141199

Cite this article as: Gangadhara, Shakuntala Rao N, Manivannan K, Krishna Rao HR. Unusual branching pattern of external carotid artery in the left carotid triangle. Int J Res Med Sci 2014;2:1743-5.