

## Original Research Article

# Medical thoracoscopy- an experience

Naveed Nazir Shah, Nazia Mehfooz\*, Syed Suraya Farooq,  
Khurshid A. Dar, Shumayl, Tariq

Department of Chest Disease, GMC, Srinagar, Jammu Kashmir, India

**Received:** 13 March 2017

**Accepted:** 04 April 2017

**\*Correspondence:**

Dr. Nazia Mehfooz,

E-mail: Dr\_suhail\_jnmc@yahoo.co.in

**Copyright:** © the author(s), publisher and licensee Medip Academy. This is an open-access article distributed under the terms of the Creative Commons Attribution Non-Commercial License, which permits unrestricted non-commercial use, distribution, and reproduction in any medium, provided the original work is properly cited.

### ABSTRACT

**Background:** Medical thoracoscopy is a minimally invasive procedure for diagnosing and treating pleural diseases especially undiagnosed exudative pleural effusion. It is cost effective and safe. The diagnostic yield in undiagnosed pleural effusion is excellent.

**Methods:** This prospective observational study was done in Government Chest Disease hospital of Government Medical College, Srinagar during the period between December 2015 to Dec 2016. Thirty undiagnosed pleural effusion patients after thoracocentesis and who fulfilled inclusion and exclusion criteria's were included in the study.

Medical thoracoscopy using rigid thoracoscope was started for the first time in our hospital and was done in these enrolled patients. Clinical, Thoracoscopic findings and histopathological data of the patients were collected prospectively and analysed.

**Results:** Maximum patients were in the age group of 41-50 years. Most common Thoracoscopic finding was multiple nodules (40%) followed by sago grain infiltration (33.4%). Malignancy was the most common HPE finding of pleural biopsy (46.6%) followed by TB (33.3%). All nodules (13) turned out to be malignant while all sago grain appearance pleura (10) turned out to be TB. The overall diagnostic yield is 80% as a whole and 96% among patients who had thoracoscopic pleural findings.

**Conclusions:** Medical Thoracoscopy is a safe and easy outpatient procedure and an excellent diagnostic tool for undiagnosed exudative pleural effusion. The diagnostic yield is quite high and complications of procedure are negligible.

**Keywords:** HPE, Pleural biopsy TB, Thoracoscopic, Thoracocentesis

### INTRODUCTION

Pulmonologist commonly encounter patients with pleural disease like pleural effusion, pneumothorax, pleural wall thickening and pleural mass. Pleural fluid aspirate for biochemical, cytological and microbiological analysis is the initial investigation to diagnose the etiology of effusion. Blind pleural biopsies may help in additional cases but complications like bleeding and pneumothorax are common. Undiagnosis even after these two procedures is seen in 25-40% of

effusions.<sup>1,2</sup> Medical thoracoscopy remains the gold standard procedure for diagnosing these patients.<sup>3</sup> The first thoracoscopy was performed using a cystoscope in 1866 by F.R. Cruise in Ireland.<sup>4</sup> It was followed subsequently by a paper by H.C. Jacobaeus in 1910.<sup>5</sup>

Medical thoracoscopy also known as pleuroscopy is a safe and minimally invasive procedure in trained hands of pulmonologist which can be performed under local anaesthesia in an endoscopy suite. It allows pulmonologist to enter the pleural space, inspect it and

perform limited diagnostic and therapeutic procedures like taking pleural biopsy from suspicious areas, adhesinolysis and chemical pleurodesis.<sup>6</sup> Surgical Thoracoscopy or VATS unlike medical thoracoscopy is done under GA with single lung ventilation.

Both rigid and semi rigid thoroscopes remain valuable in the evaluation and management of pleural disease but majority of centers use a rigid thoracoscope as this allows excellent visualization and inspection of thoracic cavity and permits adequate sized biopsies to be obtained.<sup>7</sup> Semi flexible thoroscopes are bit similar to bronchoscope and pulmonologist find them easy to handle, but the potential disadvantage is that working channel is narrower which permits only smaller biopsies from pleural cavity.<sup>7</sup>

Majority of thoracoscopy is done via single port but on occasional circumstances, one more port may be made for taking biopsies.<sup>7</sup>

Medical thoracoscopic guided pleural biopsy from suspicious sites under direct vision allows diagnosis of TB in 99% of patients as against 51% patients using closed pleural biopsy. Diagnosis of malignant pleural effusion can be achieved in 95% of patients with thoracoscopy.<sup>8</sup> Complications in medical thoracoscopy are rare, although occasional surgical emphysema, minor bleeding and infection can be seen.

The present study was aimed to report our first preliminary experience from Kashmir valley of using thoracoscope in undiagnosed exudative pleural effusions in terms of Clinical characteristics of patients, complications, thoracoscopic and Histopathological findings.

## METHODS

This prospective observational study was conducted in Chest Disease Hospital of Government Medical College, Srinagar. This hospital is the tertiary care hospital for all TB and Respiratory disease patients and is the only center in Kashmir valley where medical thoracoscopy is done. This study was done over a period of one year from December 2015 to December 2016.

Total number of patients enrolled in the study were 30 and were chosen from the patients admitted in the ward with undiagnosed exudative pleural effusion.

Undiagnosed pleural effusion was defined as failure to achieve diagnosis by microbiological, biochemistry and cytological analysis of pleural fluid. Pleural fluid was considered as an exudate if one or more of the following Light's criteria were met

- Pleural fluid protein/serum protein -  $>0.5$
- Pleural fluid LDH/serum LDH -  $>0.6$

- Pleural fluid LDH more than two-thirds of the upper limit of normal serum LDH.

We performed medical thoracoscopy with rigid thoracoscope under local anesthesia in these patients who met the following Inclusion and exclusion criteria as under;

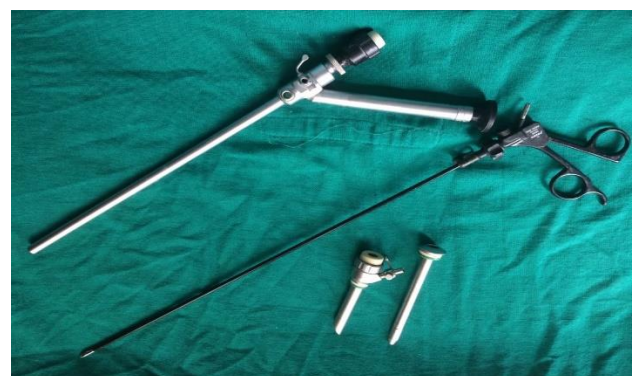### Inclusion criteria

- Massive to moderate pleural effusion on CT.
- Patients having pleural effusion with exudative nature on analysis.
- Lymphocyte predominant
- ADA levels must be less than 70 IU/L
- Negative M cells on cytology of pleural fluid
- Endobronchial lesion detected on FOB
- No known underlying lung pathology causing pleural effusion like pulmonary tuberculosis or malignancy.

### Exclusion criteria

- Mild effusion on CT
- Transudative effusion
- Paediatric patients below 12 years of age
- High ADA levels
- Endobronchial growth
- Neutrophil predominant exudative pleural effusion as per Light's criteria
- Pleural fluid ADA levels more than 70 IU/L
- Smear positive pulmonary tuberculosis
- Known primary malignancy
- Surgically unfit
- Patients with bleeding diathesis.

Medical Thoracoscopy was done in these enrolled patients using Karl storz rigid thoracoscope (Figure 1) and endoscopy system under local anesthesia in endoscopy room.



**Figure 1: Karl storz rigid thoracoscope, trocars and biopsy forcep.**

Pleural cavity was inspected for any nodules, mass or any other abnormality. Pleural biopsies were taken in

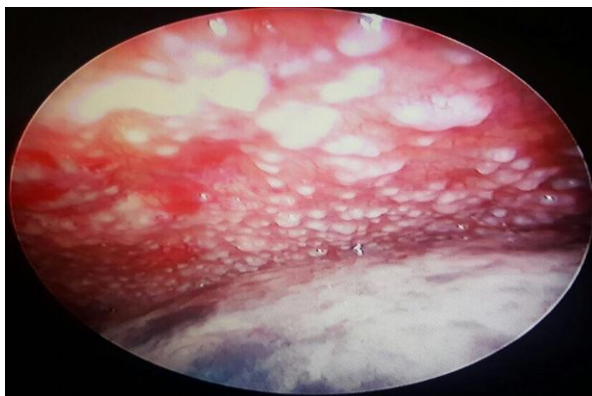all patients from suspicious areas and send for HPE even in those patients who had apparently normal looking pleura. Details of each of these patients were also noted in terms of Demographic characteristics, thorascopic findings and complications. Results were analysed and are summarized in table.

**RESULTS**

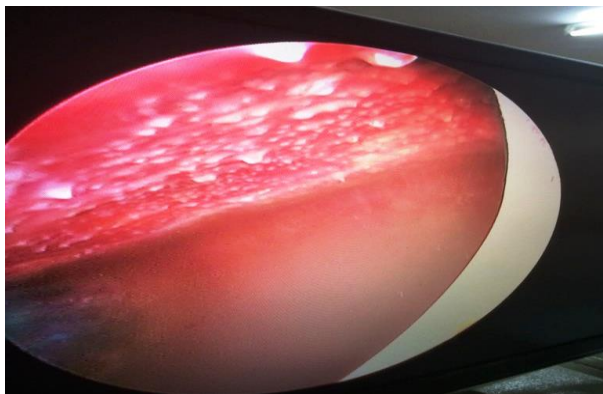
Maximum patients were in the age group of 41-50 years. Maximum males and females were also seen in the same age group. Male to female ratio was 1:1. The youngest was 25 years and oldest 74 years (Table 1).

**Table 1: Age and sex distribution of cases.**

Age groups	No of patients		
	Male	Female	Total
20-30	1	1	2
31-40	4	2	6
41-50	5	6	11
51-60	3	4	7
61-70	1	1	2
71-80	1	1	2
<b>Total</b>	<b>15</b>	<b>15</b>	<b>30</b>



**Figure 2: Multiple nodules seen on thorascopy.**

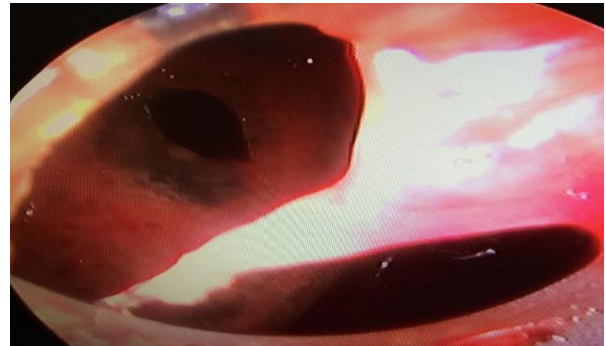

**Figure 3: Sago grain infiltraion on thorascopy.**

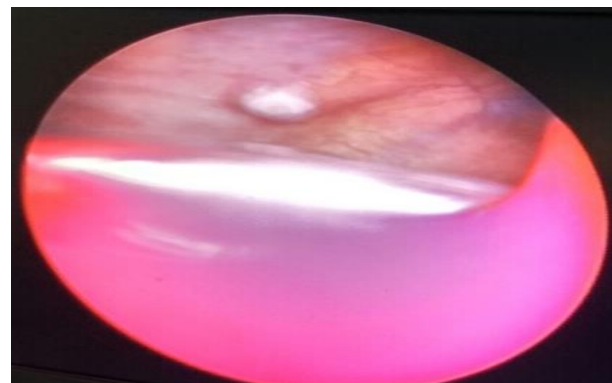
Most common Thorascopic findings were multiple nodules (40%) (Figure 2) followed by sago grain

infiltration (33.4%) (Figure 3), adhesions (6.6%) (Figure 4).

Normal pleuron was seen in 16.7 %. Single nodule (Figure5) was found in 1 patient (3.3%) (Table 2).



**Figure 4: Adhesions on thorascopy.**



**Figure 5: Adhesions on thorascopy.**

Malignancy was the most common HPE finding of pleural biopsy (46.6%) followed by TB (33.3%), Nonspecific (20%) (Table3).

**Table 2: Thorascopic findings in study group.**

Findings	Number	Percentage
Multiple Nodules	12	40
Single nodule	1	3.3
Adhesions	2	6.6
Sago grain infiltration.	10	33.4
Normal Pleura	5	16.7

Only two types of malignant lesion were seen in our patients. Adenocarcinoma was the most common (57%) while malignant mesothelioma was seen in (43%). (Table 4).

All nodules were seen in malignant group while all sago grain appearance pleura turned out of to be TB.<sup>10,13</sup>

Out of 2 adhesions, one was malignant while the other was nonspecific findings.

**Table 3: Histopathology results from pleural biopsy.**

Findings	No of patients	No. of patients
TB	10	33.3
Malignancy	14	46.6%
Nonspecific	6	20.1

No specific diagnosis was offered to 6 patients who had nonspecific findings on HPE making and out of which 5 had normal looking pleura.

**Table 4: Typing of malignant lesions.**

Type of lesion	No of patients	Percentage
Adenocarcinoma	8	57
Malignant mesothelioma	6	43

The overall diagnostic yield is 80% as a whole and 96% among patients who had thoracoscopic pleural findings (Table 5).

**Table 5: Correlation of HPE findings and thoracoscopic findings.**

Thoracoscopic Findings	Malignancy	TB	Nonspecific
Nodules	13		
Adhesions	1		1
Sago grain appearance		10	
Normal pleural			5

Complications were seen in 2 patients, one had empyema while other had subcutaneous emphysema (Table 6).

**Table 6: Complications.**

Nature of complications	No of patients
Empyema	1
Subcutaneous emphysema	1
None	28

Hemorrhagic fluid was seen in 16 patients (53%), out of which 14 had malignancy while 2 had TB. Straw colour fluid was seen in 8 patients (26%) and all of them had TB.

**Table 7: Nature and colour of pleural effusion**

Type/Colour	Malignant	Nonspecific	TB
Haemorrhagic	14		2
Straw			8
yellow		6	

Yellow coloured fluid was seen in 6 patients (21%) and had nonspecific HPE findings. In 80% of TB, colour of fluid was straw (Table 7).

## DISCUSSION

Pleural effusion remains undiagnosed in significant number of patients even after routine pleural fluid analysis and blind core biopsy. Medical thoracoscopy is a safe and valuable tool for diagnosis in such undiagnosed pleural effusions, particularly for patients with high probability of malignancy. The cost effectiveness of thoracoscopy is better in view of its better yield and lesser duration of hospital stay.

Pleural effusion of undetermined etiology has been noted in all age groups in the present study, the age of the patients ranged from 25-74years. The youngest patient's age was 25 and the oldest patient's age was 80 years. This is similar to studies by Shaheen et al where youngest and oldest patient was 26 and 72-year-old respectively.<sup>9</sup>

The maximum numbers of patients were from age group 41-50 years and the mean age was 49.7. years. Mean age was found to be, 49 year, 48.68 year 51.3 year in similar studies by Prabhu and Narasimhan, Mootha et al, and Helala et al respectively.<sup>10-12</sup>

In this study, males and females are equal in number which is in contrast to many studies where male predominance is seen.<sup>11, 12</sup> Most common Thoracoscopic findings were multiple nodules (40%) followed by sago grain infiltration (33.4%) Helala et al and Prabhu and Narasimhan found nodules in 77% and 48.5% respectively while Sago grain appearance was seen in 12.5% &12% respectively in their studies.<sup>10, 12</sup>

Normal appearing pleura was seen in 16.7 % of our patients which is quite high in comparison to other studies where it was seen to be 2.5%, 1.5% and 8%. The probable reason may be that since the procedure was started first time in Kashmir in our hospital, there is a possibility we missed findings and labeled them as normal pleura.<sup>10,12,13</sup> Adhesions were seen in 6.6% of our study patients which is similar to a study which found it in 7.5% while in contrast two studies found it in 18% and 38%.<sup>10,12,13</sup>

Malignancy was the most common HPE finding of pleural biopsy (46.6%) followed by TB (33.3%), Nonspecific (20%). Helala et.al, Haung et.al., Tscheikuna et al and Prabhu and Narasimhan found malignancy in 70%, 44.7%, 45.35% and 35% respectively.<sup>10,12,14,15</sup> Helala et.al, Haung et.al. and Prabhu and Narasimhan found TB in 22.5%, 36.2% and 23.5% respectively.<sup>10,12,14</sup>

Only two types of malignant lesion were seen in our patients. Adenocarcinoma was the most common (57%) while malignant mesothelioma was seen in (43%). Our findings are in accordance to Helela et.al who found malignant pleural mesothelioma in (53.6%) of malignant patients and Abdollah et al who found malignant pleural mesothelioma in (47.06%) of malignant patients.<sup>12</sup>

The results of our study contradict the results of Prabhu and Narasimhan who found malignant pleural mesothelioma in 12.5% of their malignant patients and Abhishek agarwal et. al who found malignant pleural mesothelioma in 7.6% of patients. Nonetheless, in a study by Asmita M et al., mesothelioma was not reported.<sup>10, 20</sup> Adenocarcinoma was seen in 62.5% of patients in study of Prabhu and Narishman (10) and in 76.9% in study of Abhishek Agarwal et.al.<sup>21</sup>

All patients with nodules (100%) turned out to be malignant. Helala et.al. found that 92.9% of patients who had nodules had malignant pleural effusion while Prabhu and Narasimhan found that >70% of patients who had nodules had malignant lesion.<sup>12, 10</sup> All sago grain appearance pleura (100%) turned out to be TB which is exactly similar to what Helala et.al. and Prabhu and Narishman et.al. reported.<sup>12, 10</sup> Out of 2 adhesions, one was malignant while the other was nonspecific findings. Helala et.al. reported 100% of patients who had adhesion had non-malignant lesion while Prabhu and Narishman reported >96% of patients who had adhesion had chronic or sub-acute inflammation (non-malignant lesion).<sup>12, 10</sup>

Pleural fluid cytology and closed pleural biopsy are the two commonly applied procedures for the diagnosis of pleural effusion before thoracoscopy is performed.<sup>13</sup> The diagnostic yield of cytology in malignant pleural effusion varies between 30% and 80% (13). Closed pleural biopsy increases the yield by about 10% and 40% in malignant and tuberculous pleural effusions, respectively.<sup>13</sup> However, the diagnostic yield of thoracoscopy is about 93% in both malignant and tuberculous pleural effusions.<sup>13</sup> Hence, thoracoscopy is an excellent diagnostic procedure and besides this it provides the direct visualization of biopsied areas, which in turn increases the diagnostic yield.<sup>13</sup> No specific diagnosis was offered to 6 patients (20%) who had nonspecific findings on HPE and out of which 5 had normal looking pleura.

The overall diagnostic yield in our study was 80% as a whole and 96% among patients who had thoracoscopic pleural findings. Similar low diagnostic yield were reported by Law et al, Ng et al and Thangakunam et al as 66.7%, 79%, and 45.5% respectively.<sup>16-18</sup> In contrast high diagnostic yield were reported by many studies like Prabhu and Narasimhan, Helela et.al and Haung et.al and Wang et al as 97%, 95%, 93.6% and 93% respectively.<sup>10, 12, 14, 19</sup>

There are probably many reasons for low diagnostic yield in our study as compared to others; In some studies, they have included a category of nonspecific inflammation as one diagnosis but we included all nonspecific inflammation as Non-diagnostic category; The other reason may be due to insufficient pleural biopsy samples; Also being new to thoracoscopic procedures, we may have missed some significant pleura findings and labeled them incorrectly as normal pleura and took biopsy from normal pleura and it could also reflect the learning curve for the pulmonologists

Serious complications following thoracoscopy are rare. The procedure is generally considered to be safe and well-tolerated, especially with semi-rigid instruments with no reported mortality to date. We did not have any mortality with use of rigid thoracoscope but Mortality rates with rigid instruments are reported to be between 0.09% and 0.24%.<sup>22, 23, 24</sup>

Our Complication rate was 6.6 % ( 2 patients), one patient had empyema while the other had surgical emphysema. Similar complication rates and complications were seen in other studies like Helela et.al where 4 patients developed complications, one developed surgical emphysema and the other three transient pain and In Prabhu and Narasimhan series only 4 patients (5.8%) had minor complications like subcutaneous emphysema. This low rate of complication was also comparable with most other studies like studies by Munavvar et al. and Mehta et al.<sup>10, 12, 25, 26</sup> Hemorrhagic fluid was seen in 16 patients (53%), out of which 14 (87.5%) had malignancy while 2 had TB. Straw colour fluid was seen in 8 patients (26%) and all of them had TB. Yellow coloured fluid was seen in 6 patients (21%) and had nonspecific HPE findings. In 80% of TB, colour of fluid was straw. Our findings were similar to in a study by Shaheen et al [44] in which hemorrhagic pleural effusion was seen in (47.5%) but different to it in relation to straw colour because it was seen in 20 patients (50%) and one (2.5%) presented with green colored pleural effusion. The majority of patient in our study (87.5%) and in their study (79%) of patients with hemorrhagic effusions were finally diagnosed as malignant.

## CONCLUSION

With our Limited first experience from valley, we believe medical thoracoscopy should be performed in patients with exudative pleural effusion who cannot be diagnosed by thoracentesis. Closed biopsy in view of high complications and safety of thoracoscopy, should be avoided. Thoracoscopy enables the clinician to sample the pleura while inspecting the pleural cavity. It has a high diagnostic yield and almost negligible morbidity and mortality rates. Malignant pleural effusion and TB forms the bulk of the undiagnosed pleural exudative effusion.

*Funding: No funding sources*

*Conflict of interest: None declared*

*Ethical approval: The study was approved by the Institutional Ethics Committee*

## REFERENCES

1. Light RW. Clinical practice. Pleural effusion. *N Engl J Med.* 2002;346:1971-77.
2. Poe RH, Israel RH, Utell MJ, Hall WJ, Greenblatt DW, Kallay MC. Sensitivity, specificity, and predictive values of closed pleural biopsy. *Archives of internal medicine.* 1984;144(2):325-8.
3. Noppen M. The utility of thoracoscopy in the diagnosis and management of pleural disease. *Semin Respir Crit Care Med.* 2010;31:751-59.
4. Hokschi B, Birken-Bertsch H, Mýller JM. Thoracoscopy before Jacobaeus. *Ann Thorac Surg.* 2002;74:1288-90.
5. Jacobaeus HC. ýber die Mýglichkeit, die Zystoskopie bei Untersuchung serýser Hýhlungen anzuwenden. *Munch Med Wochenschr* 1910;57:2090-92.
6. Loddenkemper R. Thoracoscopy--state of the art. - *ErroEur Respir J.* 1998;11:213-21.
7. Maurya V, Khanna P, Kalra S, Nayar S. Medical Thoracoscopy: A Wonderful Tool in the Hands of Respiratory Physician: An Indian Experience *EC Pulmonology and Respiratory Medicine.* 2017;3(2):50-5.
8. Loddenkemper R, Grosser H, Gabler A, Mai J, Preussler H, Brandt HJ. Prospective evaluation of biopsy methods in the diagnosis of malignant pleural effusions-inpatient comparison between pleural fluid cytology, blind needle-biopsy and thoracoscopy. In *American Review of Respiratory Disease.* 1983;127:114-4.
9. Shaheen MM, Shaaban AY, Mahmoud MI, Shaaban AA, Sweed RA. The diagnostic role of thoracoscope in undiagnosed pleural effusion: Rigid versus flexible. *Egy J Chest Dise Tuberculosis.* 2014;63:635-42.
10. Prabhu VG, Narasimhan R. The role of pleuroscopy in undiagnosed exudative pleural effusion. *Lung India.* 2012;29:128-30.
11. Mootha VK, Agarwal R, Singh N, Aggarwal AN, Gupta D, et al. Medical Thoracoscopy for Undiagnosed Pleural Effusions: Experience from a Tertiary Care Hospital in North India. *Indian J Chest Dis Allied Sci.* 2011;53:21-4.
12. Helala LA, El-Assal GM, Farghally AA, Abd El Rady MM. Diagnostic yield of medical thoracoscopy in cases of undiagnosed pleural effusion in Kobri El-Kobba Military Hospital. *Egy J Chest Dise Tuber.* 2014;63:629-34.
13. Sodhi R, Sindhwani G, Nadia S, Kumar S, Jethani V, Khanduri S. A Three-Year Experience of Medical Thoracoscopy at A Tertiary Care Center of Himalayan Region. *J Cardiothorac Med.* 2016;4(1):397-402.
14. Huang G, Cheng Y, Su J, Liu A, Yu W, Wu Y, Luo Y, et al. Application of flexirigid thoracoscopy in the diagnosis of pleural disease with unknown etiology, *Nan Fang Yi Ke Da Xue Xue Bao.* 2011;3(4):669-73.
15. Tscheikuna J, Silairatana S, Sangkeaw S, Nana A. Outcome of medical thoracoscopy. *J Med Assoc Thai.* 2009;92:S19-23.
16. Law WL, Chan J, Lee S, Ng CK, Lo CK, Ng WK, et al. Pleuroscopy: our initial experience in Hong Kong. *Hong Kong Med J.* 2008;14:178-84.
17. Ng TH, How SH, Kuan YC, Hasmah H, Norra H, et al. Medical thoracoscopy: Pahang experience. *Med J Malaysia.* 2008;63:298-301.
18. Thangakunam B, Christopher DJ, James P, Gupta R. Semi-rigid thoracoscopy: initial experience from a tertiary care hospital. *Indian J Chest Dis Allied Sci.* 2010;52:25-27.
19. Wang Z, Tong ZH, Li HJ, Zhao TT, Li XY, et al. Semi-rigid thoracoscopy for undiagnosed exudative pleural effusions: a comparative study. *Chin Med J (Engl).* 2008;121:1384-89.
20. Asmita M, Rajesh V, Vishwam D, Babu S, Patel V, Lakshmanan H, et al. Value of semi rigid thoracoscopy in pleural effusion. *Pulmon.* 2010; 12:43-5.
21. Agarwal A, Prasad R, Garg R, Verma SK, Singh A, Husain N. Medical thoracoscopy: a useful diagnostic tool for undiagnosed pleural effusion. *Indian J Chest Dis Allied Sci.* 2014;56(4):217-0.
22. Rodríguez-Panadero F. Medical thoracoscopy. *Respiration.* 2008;76(4):363-72.
23. Casal R, Eapen G, Morice R. Medical thoracoscopy, *Curr.Opin. Pulm. Med.* 2009;15:313-20.
24. Medford A, Bennett J, Free C. Current status of medical pleuroscopy, *Clin. Chest Med.* 2010;31:165-72.
25. Munavvar M, Khan M, Edwards J, Waqaruddin Z, Mills J. The autoclavable semirigid thoracoscope: the way forward in pleural disease? *Eur Respir J.* 2007;29:571-74.
26. Mehta A, Patel M, Soni A, Patel T, Parmar S, Dumra S, et al. Investigation into role of medical pleuroscopy in the diagnosis and management of patients with pleural diseases, *Indian J. Thorac. Cardiovasc. Surg.* 2012;28(2) :120-6.

**Cite this article as:** Shah NN, Mehfooz N, Farooq SS, Dar KA, Shumayl, Tariq. Medical thoracoscopy-an experience. *Int J Res Med Sci* 2017;5:2176-81.