

## Original Research Article

# Variations, relations and clinical significance of carotid arterial system in anterior neck: a cadaveric study

Anasuya Ghosh\*, Subhramoy Chaudhury, Atin Datta

Department of Anatomy, Medical University of the Americas, Charlestown, Nevis, Saint Kitts and Nevis

**Received:** 30 January 2019

**Accepted:** 01 March 2019

### \*Correspondence:

Dr. Anasuya Ghosh,

E-mail: [dranasuya7@gmail.com](mailto:dranasuya7@gmail.com)

**Copyright:** © the author(s), publisher and licensee Medip Academy. This is an open-access article distributed under the terms of the Creative Commons Attribution Non-Commercial License, which permits unrestricted non-commercial use, distribution, and reproduction in any medium, provided the original work is properly cited.

## ABSTRACT

**Background:** The common carotid, internal and external carotid arteries and their branches serve as major source of blood supply in head-neck region of human and are often encountered during numerous surgical and clinical interventions of neck.

**Methods:** We dissected and examined both sides of neck in 49 well embalmed cadavers (98 sides). We recorded the following anatomical parameters of carotid arterial system-level of bifurcation, the relation between internal and external carotid arteries, branching pattern of anterior branches of external carotid artery, tortuosity in carotid arterial system, and relation of hypoglossal nerve with the carotid arteries.

**Results:** In 56.16 % cases, the common carotid arterial bifurcation took place at the upper border of thyroid cartilage though high bifurcation was quite common (43.88%). The external carotid artery was located antero-medial to internal carotid artery in most cases (93.87%). Abnormal tortuosity of carotid arterial system was detected in 2.04% cases only. In 86.73% cases, the hypoglossal nerve crossed the internal and external carotid artery superior to carotid bifurcation above the level of hyoid bone while in 1 case it crossed immediately inferior to carotid bifurcation. In branching pattern, following variations were observed- linguo-facial trunk in 15.3% cases, thyro-lingual trunk in 5.1% cases, origin of superior thyroid artery from common carotid in 10.02% cases and origin of superior thyroid from internal carotid in one case (1.02%).

**Conclusions:** The carotid arterial system has complex and variable anatomy in neck and this information should be kept in mind to avoid unwanted damage during surgical procedures of neck.

**Keywords:** Carotid bifurcation and hypoglossal nerve, Carotid tortuosity, External carotid branching variation, Internal and external carotid relation

## INTRODUCTION

The common carotid arterial system serves as the major source of arterial supply in the head and neck region. The common carotid artery (CCA) usually bifurcates into external carotid artery (ECA) and internal carotid artery (ICA) at the level of upper border of thyroid cartilage or at C3-C4 or C4-C5 intervertebral disc though the bifurcation may vary.<sup>1-8</sup> Description of carotid bifurcation

in relation to anterior anatomic landmarks like hyoid bone (HB) or thyroid cartilage (TC) are more useful as during neck surgeries the vertebrae are not usually accessible.<sup>9</sup> The ECA most commonly lies anteromedial to ICA, again variations has been reported.<sup>1,2,10-12</sup> The hypoglossal nerve crosses the ECA and ICA at variable distances rostral to the carotid bifurcation.<sup>13-15</sup> The branching pattern of CCA shows variability and has been reported in literature, however, in most cases, the

superior thyroid artery (STA), lingual artery (LA) and facial artery (FA) arise directly from front of ECA within anterior triangle of neck.<sup>1,2,4,5,9,10,12,16-23</sup> These branches arising from front of ECA are especially important during chemoembolization and neck reconstruction surgeries during surgical management of head-neck tumors.<sup>9</sup>

Neck has a complex and variable anatomical relationship between many important structures and these knowledge is crucial in numerous surgical interventions including carotid endarterectomy, carotid stenting, vascular embolization, neck tumor surgeries, plastic reconstruction of neck following removal of large mass, radical neck dissections, carotid sinus baroreceptor stimulation to avoid unwanted structural damage and related complications.<sup>9,18,22,24</sup> Moreover, the anatomy and geometry of CCA may influence the carotid atherosclerosis which is a leading cause of death and disability.<sup>9,25,26</sup>

The objective of this study was to re-explore the detailed anatomical relations of carotid artery within the anterior triangle of neck focusing on the bifurcation level of common carotid artery and its relation to hypoglossal nerve, branching pattern of front branches of ECA, relation between ECA and ICA and unusual tortuosity in carotid arterial system if any.

## METHODS

We have dissected and examined 98 sides of 49 well embalmed cadavers (22 male, 27 female) at gross anatomy lab of the institution over a period of 2 years and 4 months (July 2016 to November 2018). The mean age of cadavers varied from 64-87 years.

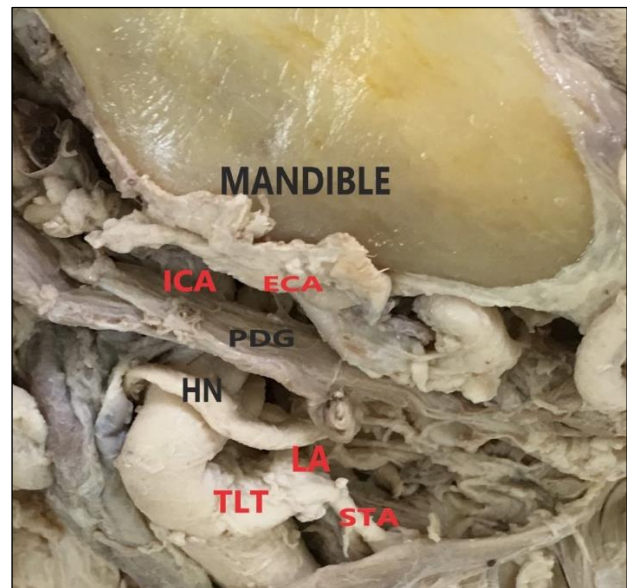
All the cadavers were placed in supine position, the neck was extended by placing blocks underneath and while examining a particular side, the head was tilted towards opposite side for better exposure and to mimic surgical positions. All the cadavers were partly dissected by medical students as a part of their gross anatomy practical course under guidance of anatomy instructors. Those cadavers with considerable damage to common carotid arterial system were excluded from the study beforehand. The incision line extended along the lower border of body of mandible, the midline of the neck and the anterior border of sternocleidomastoid muscle to fully expose the anterior triangle of neck. The superficial fascia with platysma and connective tissue were dissected.

We examined the structures within carotid triangle especially the carotid artery and its relations and variation. We recorded the bifurcation level of CCA in respect to hyoid bone and thyroid cartilage (anterior landmarks of neck) and the location of hypoglossal nerve in relation to hyoid bone and carotid arterial bifurcation. We observed the origin of the anterior branches of ECA including STA, LA and FA within carotid triangle of neck.

## RESULTS

In all cases the common carotid arteries were located within anterior triangle of neck medial to internal jugular vein and within carotid triangle. The vagus nerve was found in between the CCA and internal jugular vein in a deeper plane.

The CC bifurcation took place in between the greater horn of hyoid bone and upper border of thyroid cartilage in 37 cases, at the level of greater horn of hyoid bone in 5 cases, at upper border of thyroid cartilage in 55 cases and above the greater horn of hyoid bone in only 1 case (Figure 1).



ICA- Internal carotid artery, ECA- external carotid artery, PDG- posterior belly of digastric muscle, HN- Hypoglossal nerve (crossed caudal to carotid bifurcation), TLT- thyro-lingual trunk, STA- Superior Thyroid artery, LA- lingual artery.

**Figure 1: High carotid bifurcation inferior to angle of mandible.**

We regarded the upper border of thyroid cartilage as the standard bifurcation point of CCA (1-5) and any bifurcation noted above this level was regarded as high bifurcation. Carotid bifurcation at or below the body of TC was recorded as low bifurcation. We found high CC bifurcation in 43 cases and standard CC bifurcation in 55 cases. We did not find any low CC bifurcation (Table 1).

We founded the location of external carotid artery antero-medial to internal carotid artery in 92 cases, postero-medial to internal carotid in two cases and just medial to internal carotid in 4 cases. We found abnormal tortuosity of internal carotid in 1 case and tortuous ECA and ICA including CC bifurcation in 1 case only.

The hypoglossal nerve was found to cross the ICA and ECA at variable distances form the point of CC bifurcation and rostral to the bifurcation in 97 cases. It

crossed immediately caudal to CC bifurcation in only 1 case. It crossed ICA and ECA rostral to the level of hyoid bone in 85 cases and at the level of hyoid bone in 13 cases. We did not find any hypoglossal nerve crossing below the level of hyoid bone. In all cases, the hypoglossal nerve was closely related to the lower border of posterior belly of digastric muscle (Table 2).

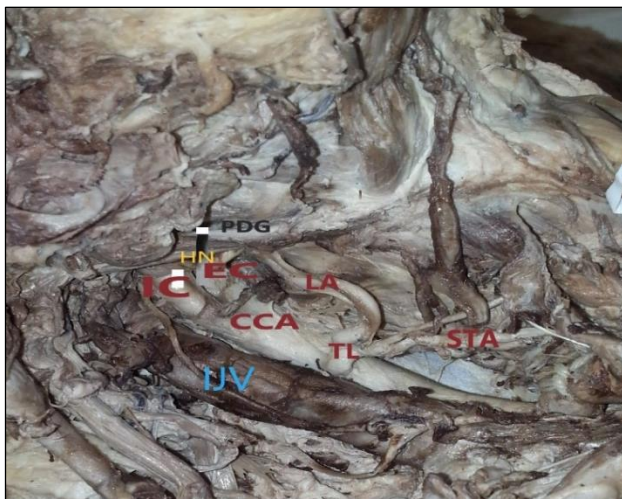
**Table 1: The bifurcation pattern of common carotid artery.**

Anatomical Landmark	Percentage
High bifurcation	43.88%
Above hyoid bone	0.01%
At the level of hyoid bone	0.05%
Between HB <sup>1</sup> and TC <sup>2</sup>	37.76%
Standard bifurcation	56.12%
At upper border of TC	
Low bifurcation	0
At body of TC or below	

<sup>1</sup>Hyoid bone, <sup>2</sup>Thyroid cartilage.

**Table 2: Anatomical levels of hypoglossal nerve crossing the internal and external carotid artery.**

Landmark	Percentage
Above hyoid bone	86.73%
At the level of hyoid bone	13.27%
Below hyoid bone	0

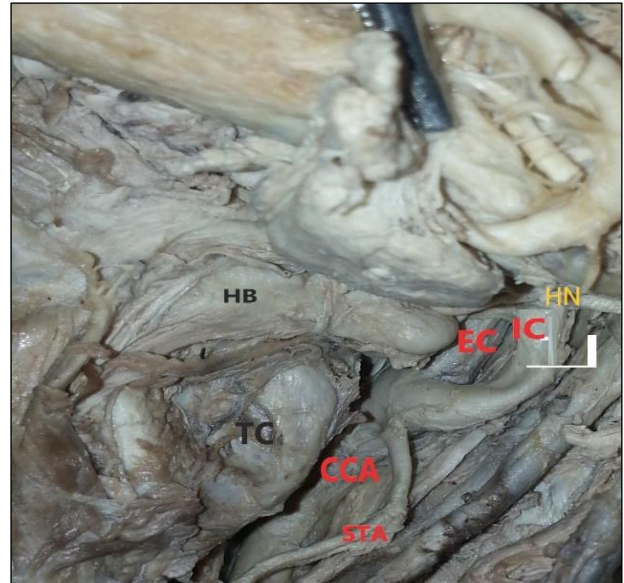


ECA- external carotid artery, PDG- posterior belly of digastric muscle, HN- Hypoglossal nerve (crossing EC at the level of hyoid bone), HB- hyoid bone, LA- lingual artery, STA- Superior thyroid artery, IJV- internal Jugular vein, PDG- posterior belly of digastric muscle.

**Figure 2: Thyro-lingual trunk arising from common carotid artery.**

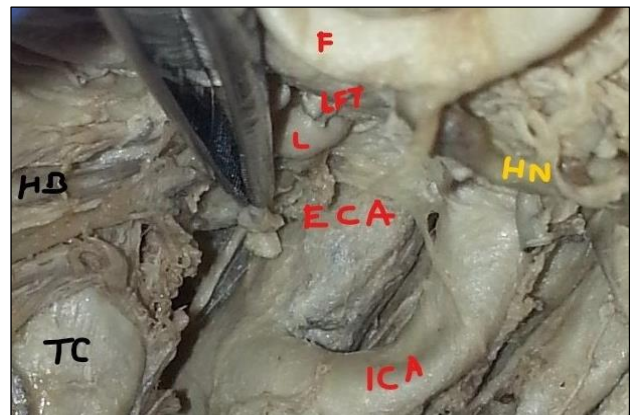
We found the origin of superior thyroid artery (STA) directly from ECA in 82 cases and STA arising from Thyro-lingual trunk (Figure 2) in 5 cases (Thyro-lingual trunk again originated from ECA in 1 case and from CCA

in 4 cases). Again, STA directly arose from CCA in 10 cases and from internal carotid artery at the level of CC bifurcation in 1 case (Figure 3).



CCA- Common carotid artery, IC- Internal carotid artery (has a curved course), EC- external carotid artery, HN- Hypoglossal nerve (crossing ECA and ICA above the level of hyoid bone), HB – hyoid bone, TC- thyroid cartilage.

**Figure 3: Superior thyroid artery arising from internal carotid artery at carotid bifurcation.**



LFT- Linguo-facial trunk, F- facial artery, L- lingual artery, ICA- Internal carotid artery, ECA- external carotid artery, HN- Hypoglossal nerve ( crossing over the linguo-facial trunk), HB- hyoid bone, TC- Thyroid cartilage.

**Figure 4: Linguo-facial trunk.**

We found the origin of Lingual artery directly from ECA in 78 cases, from Thyro-lingual trunk in 5 cases and from Linguo- facial trunk in 15 cases.

The origin of facial artery was found directly from the external carotid artery in 83 cases and from Linguo-facial trunk (Figure 4) in 15 cases. All the variations were asymmetrical (Table 3).



**Table 3: The variation patterns of external carotid artery branches.**

Variant patterns	Percentage
Linguo-facial trunk	15.30%
Thyro-lingual trunk	5.1%
Thyro-Lingual trunk from CCA <sup>1</sup>	4.08%
Thyro-lingual trunk from ECA <sup>2</sup>	1.02%
STA <sup>3</sup> arising from CCA	10.20%
STA arising from ICA <sup>4</sup>	1.02%

<sup>1</sup>Common carotid artery, <sup>2</sup>External carotid artery, <sup>3</sup>Superior thyroid artery, <sup>4</sup>Internal carotid arteries.

## DISCUSSION

This cadaveric study focused on several aspects of complex anatomical relations in neck including CCA bifurcation level and its relation to hypoglossal nerve, ECA branching pattern, relation between ECA and ICA and tortuosity of carotid arterial system if any.

We found that the commonest bifurcation level of CCA was at upper border of thyroid cartilage (56.12%) while high bifurcation was quite common. Low bifurcation of CC was not observed in this study. The term high bifurcation lacks precise definition across literature mentioned as any point above upper border of thyroid cartilage (TC) or any point above greater horn of hyoid bone (HB).<sup>9</sup> The previous studies supported the observation that upper border of TC is the commonest bifurcation level and high bifurcations are more common than low bifurcation.<sup>1,3,5,7,16,19,27,28</sup> Absence of low bifurcation was also reported by another study.<sup>7</sup> We found significantly high bifurcation in only one case with other unusual features it was located inferior to the angle of mandible at the level of posterior belly of digastric muscle, it was crossed by hypoglossal nerve immediately caudal to the CC bifurcation level, both ICA and ECA showed curved course cranial to CC bifurcation and the ECA was located postero-medial to ICA.

A high bifurcation should be treated cautiously by surgeons due to its close neighborhood to hypoglossal nerve and difficulties in approach.<sup>6,29</sup> Strover S et al, reported higher incidences of vascular trauma possible in high CC bifurcations during penetrating neck injuries.<sup>30</sup>

In this study, in 93.87% cases the ECA was located antero-medial to ICA. Previous studies reported this standard position in 50% of cases to 70% cases.<sup>1,11,12,19</sup> We did not find any reversal of position of ICA and ECA though such case has been reported in literature.<sup>12</sup> In a doppler scan based study by Prendes JL et al, posrtero-lateral position of the ECA was noted in 5.3% of whereas in this study, it was found only in 2 cases (2.04%).<sup>31</sup> Previous researchers recommended the CT angiography in both lateral and antero-posterior views to be performed before head-neck surgical procedures to avoid confusion in variant structure identification or unwanted injuries.<sup>32-34</sup>

The abnormal tortuosity in relation to CCA, ECA or ICA was observed very rarely (2.04%) in current study while Lo A et al, reported 26% abnormal curvature and 6% kinking in CCA.<sup>8</sup> A previous study suggested tortuosity or kinking of internal carotid artery is not related to ischemic stroke.<sup>35</sup> Dangas G et al, recommended carotid stenting over carotid endarterectomy in cases of marked tortuosity.<sup>36</sup>

The current study reported rostral to body of hyoid bone was the commonest (86.73%) area where the hypoglossal nerve crossed both ICA and ECA. Previous studies reported the distance of hypoglossal nerve from CC bifurcation was variable ranging from immediately above the bifurcation to anterior belly of digastric or rarely directly overlying the bifurcation.<sup>13-15</sup>

The variable intimate relationship of this nerve to carotid arterial system makes it vulnerable to damage during carotid endarterectomy, different neck surgeries including anterior approaches to cervical vertebrae or cranio-vertebral structures.<sup>13-15</sup>

We found the variation of anterior branches of ECA was quite common (26.53%) among which the linguo-facial trunk was the commonest (15.3%). Anangwe D et al, reported ECA branching variation in 9% cases only where linguo-facial trunk was the commonest (7%) like this study.<sup>19</sup> Troupis TG et al, reported the incidence of linguo-facial trunk to be 6%.<sup>18</sup> However, Zumre O et al, reported 20% incidence of linguo-facial trunk which was close to our findings.<sup>28</sup>

Current study detected STA originated directly from ECA in 85.41% cases while the incidence was 80% in Al Rafiah A et al, study.<sup>1</sup> Lucev V et al, reported this standard origin of STA in 30% of cases and Ozgur Z et al, detected this in 40% cases.<sup>16,37</sup>

As the cadavers were Caucasoid, these findings were supported by Toni R et al, that in Caucasoid, STA more commonly originates from ECA.<sup>17</sup>

We observed Thyro-lingual trunk in 5.1% cases while 1.7% such cases were detected by Al-Rafiah A et al, and 2.5% cases by Zumre O et al.<sup>1,28</sup> We observed STA arose from the CCA in 10.2% cases while this incidence was 18.3% in Al Rafiah A et al, study.<sup>1</sup>

We found an extremely rare variation where STA took origin from ICA at CC bifurcation and such variation was not reported by any previous study to the knowledge. Current study is unique one to report multiple aspects of anatomical relations of carotid artery and their variations in neck which are immensely important in general surgery, plastic surgery, spine surgery, vascular surgery, maxillofacial surgery and oncologic procedures related to neck. This information is also valuable for clinical examination and radiological interpretation of neck structures.<sup>27</sup> One of the drawbacks of this study was-

exact measurement of the distance of hypoglossal nerve in relation to CC bifurcation and hyoid bone was not recorded.

## CONCLUSION

We confirmed carotid arterial system had variable branching pattern and variable relation to hypoglossal nerve in neck and all the variations were asymmetrical. High bifurcation of common carotid artery was quite common and hypoglossal nerve commonly crossed the internal and external carotid artery rostral to the level of hyoid bone.

The external carotid was mostly antero-medial to internal carotid, low carotid bifurcation was not found, and unusual tortuosity of carotid artery was extremely less in this study population. This information should be kept in mind during surgical procedures to prevent unwanted complications.

## ACKNOWLEDGEMENTS

We would like to thank all who donated their bodies and students for participating in the cadaveric dissection process.

*Funding: No funding sources*

*Conflict of interest: None declared*

*Ethical approval: The study was approved by the Institutional Ethics Committee*

## REFERENCES

- Al-Rafiah A, El-Haggagy AA, Aal IH, Zaki AI. Anatomical study of the carotid bifurcation and origin variations of the ascending pharyngeal and superior thyroid arteries. *Folia Morphol.* 2011;70(1):47-55.
- Standring S. Gray's anatomy: the anatomical basis of clinical practice. 39th Ed. Elsevier, Churchill Livingstone, New York; 2015.
- Radha K. Bifurcation levels of the common carotid arteries: a cadaveric study in south Indian population. *Int J Anat Res.* 2014;2(3):511-14.
- Vinaitha D, Anandhi KS, Saran RS, Ramanathan L, Subramaniam A. High bifurcation of the common carotid artery and looping of the external carotid artery-a case report. *J Clin Diagn Res.* 2012;6(3):462-4.
- Anu VR, Pai MM, Rajalakshmi R, Latha VP, Rajanigandha V, D Costa S. Clinically-relevant variations of the carotid arterial system. *Singapore Med J.* 2007;48(6):566.
- Kurkuoglu A, Aytekin C, Oktem H, Pelin C. Morphological variation of carotid artery bifurcation level in digital angiography. *Folia Morphol.* 2015;74(2):206-11.
- Woldeyes DH. Anatomical variations of the common carotid artery bifurcations in relation to the cervical vertebrae in Ethiopia. *Anatomy Physiol.* 2014;4:2161-0940.
- Lo A, Oehley M, Bartlett A, Adams D, Blyth P, Al-Ali S. Anatomical variations of the common carotid artery bifurcation. *ANZ J Surg.* 2006;76(11):970-2.
- Michalinos A, Chatzimarkos M, Arkadopoulos N, Safioleas M, Troupis T. Anatomical considerations on surgical anatomy of the carotid bifurcation. *Anatomy Res Int.* 2016;1-8.
- Brash JA. Cunningham's Manual of practical anatomy, Head, neck and brain. 12th Ed. Oxford University: New York; 1958.
- Trigaux JP, Delchambre F, Van Beers B. Anatomical variations of the carotid bifurcation: implications for digital subtraction angiography and ultrasonography. *Brit J Radiol.* 1990;63(747):181-5.
- Ito H, Mataga I, Kageyama I, Kobayashi K. Clinical anatomy in the neck region. *Okajimas Folia Anatomica Jap.* 2006;82(4):157-68.
- Kim T, Chung S, Lanzino G. Carotid artery-hypoglossal nerve relationships in the neck: an anatomical work. *Neurol Res.* 2009;31(9):895-9.
- Imparato AM, Bracco A, Kim GE, Bergmann L. The hypoglossal nerve in carotid arterial reconstructions. *Stroke.* 1972;3(5):576-85.
- Salame K, Masharawi Y, Rochkind S, Arensburg B. Surgical anatomy of the cervical segment of the hypoglossal nerve. *Clin Anatomy.* 2006;19(1):37-43.
- Lučev N, Bobinac D, Marić I, Dreščik I. Variations of the great arteries in the carotid triangle. *Otolaryngol Head Neck Surg.* 2000;122(4):590-1.
- Toni R, Della Casa C, Castorina S, Malaguti A, Mosca S, et al. A meta-analysis of superior thyroid artery variations in different human groups and their clinical implications. *Ann Anatomy Anatomischer Anzeiger.* 2004;186(3):255-62.
- Troupis TG, Dimitroulis D, Paraschos A, Michalinos A, Protogerou V, Vlasis K, et al. Lingual and facial arteries arising from the external carotid artery in a common trunk. *Am Surg.* 2011;77(2):151-4.
- Anangwe D, Saidi H, Ogeng'o J, Awori KO. Anatomical variations of the carotid arteries in adult Kenyans. *East Afr Med J.* 2008;85(5):244-7.
- Lemaire V, Jacquemin G, Medot M, Fissette J. Thyrolingual trunk arising from the common carotid artery a case report. *Surg Radiol Anatomy.* 2001;23(2):135-7.
- Hayashi N, Hori E, Ohtani Y, Ohtani O, Kuwayama N, Endo S. Surgical anatomy of the cervical carotid artery for carotid endarterectomy. *Neurol Med Chirurgica.* 2005;45(1):25-30.
- Chan YC, Wong WH, Cheng SW. Successful carotid endarterectomy in a patient with an aberrant branch from the common carotid artery. *Ann Royal Coll Surg Eng.* 2013;95(2):e17-9.
- Kaneko K, Akita M, Murata E, Imai M, Sowa K. Unilateral anomalous left common carotid artery; a

- case report. *Ann Anatomy Anatomischer Anzeiger.* 1996;178(5):477-80.
24. Kurkcuoglu A, Aytekin C, Oktem H, Pelin C. Morphological variation of carotid artery bifurcation level in digital angiography. *Folia Morphol.* 2015;74(2):206-11.
  25. Phan TG, Beare RJ, Jolley D, Das G, Ren M, Wong K, et al. Carotid artery anatomy and geometry as risk factors for carotid atherosclerotic disease. *Stroke.* 2012;43(6):1596-601.
  26. Yang X, Jin J, Xu M, Wu H, He W, Yuchi M, et al. Ultrasound common carotid artery segmentation based on active shape model. *Computational Mathematical Methods Med.* 2013;2013.
  27. Klosek SK, Rungruang T. Topography of carotid bifurcation: considerations for neck examination. *Surg Radiol Anatomy.* 2008;30(5):383-7.
  28. Zümre Ö, Salbacak A, Çiçekcibaşı AE, Tuncer I, Seker M. Investigation of the bifurcation level of the common carotid artery and variations of the branches of the external carotid artery in human fetuses. *Ann Anatomy Anatomischer Anzeiger.* 2005;187(4):361-9.
  29. McNamara JR, Fulton GJ, Manning BJ. Three-dimensional computed tomographic reconstruction of the carotid artery: identifying high bifurcation. *Euro J Vascul Endovasc Surg.* 2015;49(2):147-53.
  30. Stover S, Holtzman RB, Lottenberg L, Bass TL. Blunt innominate artery injury. *Am Surg.* 2001;67(8):757.
  31. Prendes JL, McKinney WM, Buonanno FS, Jones AM. Anatomic variations of the carotid bifurcation affecting Doppler scan interpretation. *J Clin Ultrasound.* 1980;8(2):147-50.
  32. Kaseff LG. Positional variations of the common carotid artery bifurcation: implications for digital subtraction angiography. *Radiol.* 1982;145(2):377-8.
  33. Link J, Brossmann J, Penselin V, Glüer CC, Heller M. Common carotid artery bifurcation: preliminary results of CT angiography and color-coded duplex sonography compared with digital subtraction angiography. *AJR. Am J Roentgenol.* 1997;168(2):361-5.
  34. Schwartz RB, Jones KM, Chernoff DM, Mukherji SK, Khorasani R, Tice HM, et al. Common carotid artery bifurcation: evaluation with spiral CT. *Work in progress. Radiol.* 1992;185(2):513-9.
  35. Togay-Isikay C, Kim J, Betterman K, Andrews C, Meads D, Tesh P, Tegeler C, et al. Carotid artery tortuosity, kinking, coiling: stroke risk factor, marker, or curiosity?. *Acta Neurol Belgica.* 2005;105(2):68.
  36. Dangas G, Laird Jr JR, Mehran R, Satler LF, Lansky AJ, Mintz G, et al. Carotid artery stenting in patients with high-risk anatomy for carotid endarterectomy. *J Endovascular Therapy.* 2001;8(1):39-43.
  37. Ozgur Z, Govsa F, Ozgur T. Anatomic evaluation of the carotid artery bifurcation in cadavers: implications for open and endovascular therapy. *Surg Radiol Anatomy.* 2008;30(6):475.

**Cite this article as:** Ghosh A, Chaudhury S, Datta A. Variations, relations and clinical significance of carotid arterial system in anterior neck: a cadaveric study. *Int J Res Med Sci* 2019;7:1127-32.