

## Original Research Article

# Unusual complications of hypospadias repair: diagnosis and management

Rama Kishan Saran<sup>1</sup>, Kiran Mirdha<sup>2\*</sup>, Sanya Saran<sup>3</sup>, Rajendra Prasad Takhar<sup>4</sup>

<sup>1</sup>Department of Surgery, Dr. S. N. Medical College, Jodhpur, Rajasthan, India

<sup>2</sup>Department of Gynaecology and Obstetrics, Umaid Hospital and Dr. S. N. Medical College, Jodhpur, Rajasthan, India

<sup>3</sup>Student, Geetanjali Medical College and Hospital, Udaipur, Rajasthan, India

<sup>4</sup>Department of Respiratory Medicine, Government Medical College, Kota, Rajasthan, India

**Received:** 06 July 2019

**Revised:** 03 August 2019

**Accepted:** 08 August 2019

### \*Correspondence:

Dr. Kiran Mirdha,

E-mail: 9414803205k@gmail.com

**Copyright:** © the author(s), publisher and licensee Medip Academy. This is an open-access article distributed under the terms of the Creative Commons Attribution Non-Commercial License, which permits unrestricted non-commercial use, distribution, and reproduction in any medium, provided the original work is properly cited.

## ABSTRACT

**Background:** Epidermal inclusion cyst, smegma stones and urethral calculi of the penis are rare and may result as a late complication of hypospadias repair. This study reported the presentation and management of these late complications.

**Methods:** A prospective observational study included male patients aged more than 6 years of age, who had undergone hypospadias repair 3-15 years back and presented with slow growing, non-tender, mobile, firm to hard swelling. Histopathological and radiographic examination were done and surgery was used for management of epidermal inclusion cyst, urethral calculi and smegma stone. Patients were followed up for one year, postoperatively.

**Results:** Out of 15 patients, two (13.3%), four (26.7%) and nine (60%) patients were diagnosed with smegma stones, epidermal inclusion cyst and urethral calculi, respectively. The median (range) age of patients was 17 (8-30) years. Patients were presented with slow growing, non-tender, mobile swelling measuring from 1 cm x 3 cm to 2 cm x 1.5 cm. The average size of epidermal inclusion cyst, and urethral calculi was 2 cm x 2.5 cm x 1.5 cm, and 2 cm x 3 cm, respectively. Treatment were complete excision of cyst and removal of smegma stones by surgery and urethral calculi by dorsal urethrotomy. All patients had an uneventful postoperative period and were asymptomatic up to one year of follow-up.

**Conclusion:** Results suggest that these complications can be managed with complete excision and surgical removal and care must be taken while performing the hypospadias repair to avoid these unusual late complications in patients.

**Keywords:** Epidermal inclusion cyst, penile swelling, smegma stone, urethral calculi

## INTRODUCTION

Epidermal inclusion cyst or epidermoid cyst is a cutaneous lesion which develops out of the ectodermal tissue and can develop on any part of the body. However, the penile localization of this cyst is very rare.<sup>1-3</sup>

Epidermal inclusion cyst is mostly reported as a congenital or idiopathic finding diagnosed during childhood but there are very limited reports of development of epidermal inclusion cyst as a complication of hypospadias repair.

Additionally, smegma stones and urethral calculi are uncommon complications of hypospadias repair. These occur either by rolling in the epidermis at the time of hypospadias surgery or possibly by implantation of smegma in the surgical wound. The urethral diverticulum may cause stasis of urine, and infection leading to the development of urethral calculi.<sup>4,5</sup>

The present study aimed to report the presentation and management of uncommon late complications (smegma stones, urethral calculi and epidermal inclusion cyst) of hypospadias repair in patients with history of hypospadias repair.

**METHODS**

A prospective observational study was conducted in the Department of Surgery, Dr. S. N. Medical College, Jodhpur, Rajasthan, India between December 2016 and December 2018.

All male patients aged more than 6 years of age, who had undergone hypospadias repair 3-15 years back, with slow growing, non-tender, mobile, firm to hard swelling measuring from 1 cm x 3 cm to 2 cm x 1.5 cm size were included in the study. Histopathological examination was carried out for diagnosis of epidermal inclusion cyst. Urethral calculi and smegma stone of distal penile shaft were diagnosed with radiographic examination. Epidermal inclusion cyst and smegma stone were removed with surgery while urethral stones were removed with dorsal urethrotomy. Patients were followed up for one year, postoperatively.

**RESULTS**

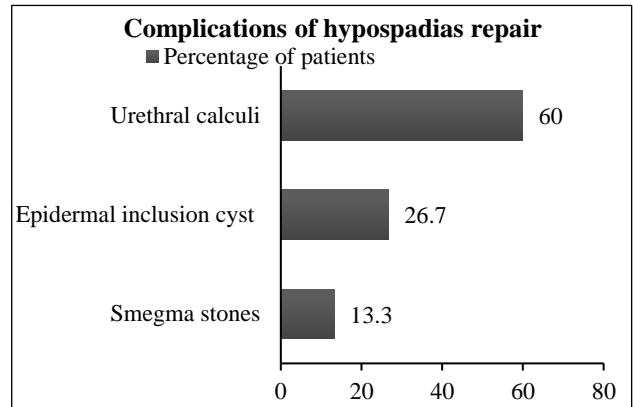
Total of 15 male patients who had undergone hypospadias repair 3-15 years back and presented with slow growing, non-tender, mobile, firm to hard swelling measuring from 1 cm x 3 cm to 2 cm x 1.5 cm size were included in the study. The median (range) age of patients was 17 (8-30) years (Table 1).

**Table 1: Baseline characteristics of patients with hypospadias repair.**

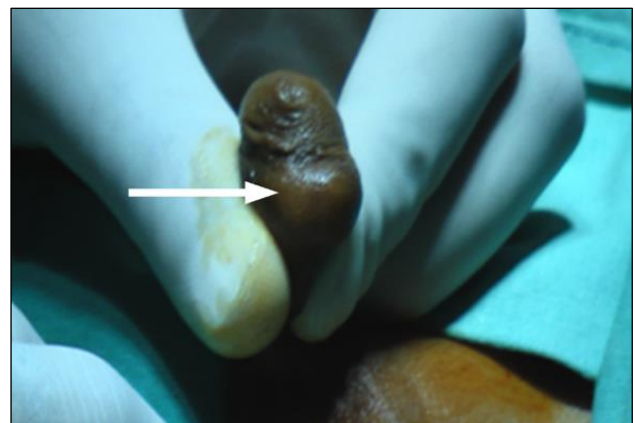
Patient's characteristics	N=15
Median age in years (range)	17 (8-30)
Diagnosis of complications	Histopathological examination
Epidermal inclusion cyst	Radiographic examination
Smegma stones	Radiographic examination
Urethral calculi	Radiographic examination
Range of size of swelling (cm)	(1 cm x 3 cm) - (2 cm x 1.5 cm)

Out of 15 patients, four (26.7%) patients had one-year history of oval shape swelling in the penile skin at the

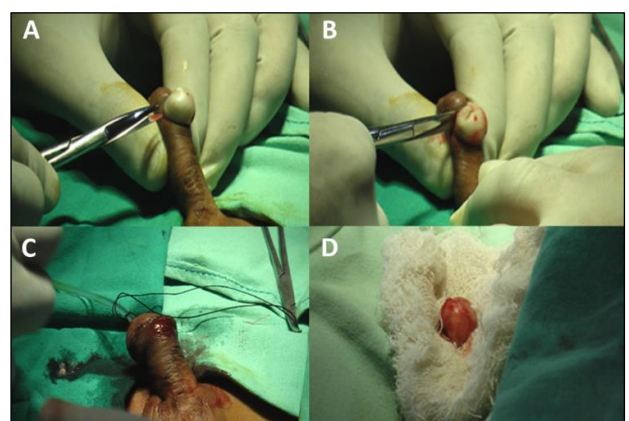
dorsolateral aspect of left side just proximal to coronaglandis along the hypospadias scar (Figure 1).



**Figure 1: Complications in patients with hypospadias repair.**



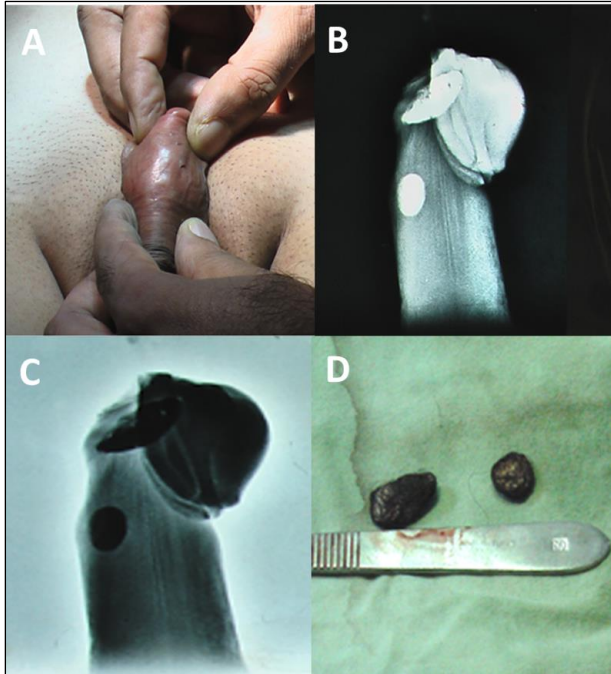
**Figure 2. A representative photo of patient present with cystic swelling of penis distal shaft of penis**



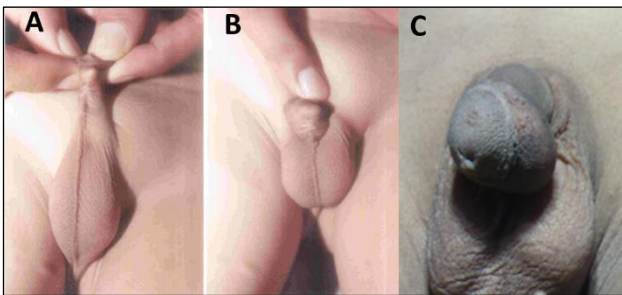
**Figure 3. Operative photo: (A and B) excision of epidermal cyst, (C) repair of surgical wound with Vicryl 4-0 suture and (D) pathological specimen of epidermal inclusion cyst.**

They had painless slow growing penile swelling. Clinical and physical examination showed non-tender, mobile

swelling of average size of 2 cm x 2.5 cm x 1.5 cm (Figure 2). Surgical excision of the swellings was performed which were provisionally diagnosed as epidermal inclusion cysts. Histopathological examination of the excised cysts confirmed diagnosis of epidermal inclusion cyst (Figure 3A-D).



**Figure 4. (A) Urethral stone in the distal part of penile urethra, (B and C) X-ray of shaft tissues of penis showing urethral calculi [one at distal part of shaft and other at corona-glandis], and (D) two urethral stone with hairs post-surgery.**



**Figure 5. Photographs of smegma stone in (A) patient 3, (B) patient 4, and (C) patient 5.**

Other nine (60%) patients had a history of splaying and weak urinary stream, gradually increasing painless penile swelling at the distal part of the penile shaft (Figure 1). They had undergone repair of congenital mid penile hypospadias 5-15 years back. Clinical and physical examination showed hard penile lumps, average 2 cm x 3 cm in size, non-tender, mobile swelling on the ventral aspect of distal part of the penis (Figure 4A). Radiographic examination showed two radio-opaque shadows in the distal part of the penis and were

diagnosed as urethral calculi. These patients underwent dorsal urethrotomy for the removal of urethral calculi with hairs (Figure 4B-D).

Remaining two (13.3%) patients were presented with gradual increasing painless, non-tender swelling of distal penile (Figure 1; Figure 5A-C) and had history of repair of congenital hypospadias. Radiographic examination reported diagnosis of smegma stone of distal penile shaft and were surgically removed.

All patients had an uneventful postoperative period. Patients were discharged from hospital after first dressing between second to fifth postoperative day. All were asymptomatic up to one year of follow-up. Passage of urine in good stream and wounds were healthy.

## DISCUSSION

Epidermal inclusion cyst, smegma stone, and urethral stone are rare and can occur after a minor surgical operation like circumcision or hypospadias repair and penile reconstructive surgery. Several mechanisms have been put forward to explain the development of epidermal inclusion cyst in patients with hypospadias repair. These mechanisms include: implantation and proliferation of epidermal element in the dermis; epidermal tissue could have been implantation during the procedure; sequestration of epidermal rests during embryonic life; occlusion of the pilosebaceous unit, or it could be the result of traumatic implantation of epithelial elements.<sup>4,5</sup> Clinically, these cysts are generally small, slow growing, soft, freely movable.

In the present study, size of penile swelling was measuring from 1 cm x 3 cm to 2 cm x 1.5 cm. The epidermal cyst generally has no symptoms and patient may seek medical advice only in case of any complications or difficulty in having sexual intercourse. The diagnosis of epidermal inclusion cyst primarily depends on clinical evaluation and ultrasound or computed tomography (CT) examinations.

In the present study, patients had a history of hypospadias repair in the past which could be the causes of inclusion cyst, urethral stone and smegma stone. The diagnosis was confirmed by history, clinical examination, X-ray of penile soft tissues; however, we did not perform the ultrasound or CT examination.

In all these patients, surgical excision and removal is the treatment of choice. There is a rare possibility of malignancy in these patients and the differentiation from congenital swelling of the penis must also be considered. Size of the swelling, the rate of growth, the potential for urethral obstruction, and difficulty in sexual intercourse are indications for surgical excision.<sup>6-9</sup> In this study, the epidermal inclusion cysts were treated with complete excision. However, urethral calculi and smegma stones were managed by surgically removing these stones. It has

been demonstrated that complete excision, removal and, careful follow-up is enough to manage this type of cases.<sup>10,11</sup> Other treatment modalities like aspiration or drainage of epidermal inclusion cyst may not be effective and may increase the risk of recurrence.

A previous study by Howe et al. reported their experience of management of 220 adolescents and adults with complications of hypospadias repair during childhood. They concluded that complications of childhood hypospadias repair may present later in life as some urethroplasties deteriorate with time and suggested that parents of children with repaired proximal hypospadias should come for follow-up as their child transitions to adolescence.<sup>12</sup>

A case report by Giambanco et al. suggested surgical excision of epidermal inclusion cyst after urethroplasty must be performed as quickly as possible to avoid occurrence of postoperative complications.<sup>13</sup> Another very recent case report by Gular et al. concluded that epidermal inclusion cyst as a complication of hypospadias surgery is a very rare situation and histopathological diagnosis and surgical excision is sufficient for treatment.<sup>14</sup> The present study results corroborate these findings.

The key limitation of the present study is its very small sample size.

## CONCLUSION

Epidermal inclusion cyst, smegma stones, and urethral stones are unusual complications of hypospadias repair. Care must be taken while performing hypospadias repair to avoid these complications.

*Funding: No funding sources*

*Conflict of interest: None declared*

*Ethical approval: The study was approved by the Institutional Ethics Committee*

## REFERENCES

1. Suwa M, Takeda M, Bilim V, Takahashi K. Epidermoid cyst of the penis: a case report and review of the literature. *Int J Urol.* 2000;7(11):431-3.
2. Unsal A, Cimentepe E, Saglam R. Penile epidermoid cyst in an elderly patient. *Int Urol Nephrol.* 2002;34(2):229-30.

3. Kinebuchi Y, Nakayama T, Fujiwara M, Yoneyama T. Epidermoid cyst of the penis: a case report. *Nippon Hinyokika Gakkai Zasshi.* 2003;94:452-5.
4. Saini P, Mansoor MN, Jalali S, Sharma A. Penile epidermal inclusion cyst. *Indian J Pediatr.* 2010; 77(7):815-6.
5. Okeke LI. Epidermal inclusion cyst as a rare complication of neonatal male circumcision: a case report. *J Med Case Rep.* 2009;3(1):7321.
6. Park HJ, Park NC, Park SW, Jern TK, Choi KU. Penile epidermal inclusion cyst: a late complication of penile girth enhancement surgery. *J Sex Med.* 2008;5(9):2238-40.
7. Hayashi Y, Yasui T, Kojima Y, Maruyama T, Tozawa K, Kohn K. Management of urethral calculi associated with hairballs after urethroplasty for severe hypospadias. *Int J Urol.* 2007;14(2):161-3.
8. Ozgok Y, Seckin B, Demirci S, Harmankaya C, Erduran D, Sinav A. Surgical treatment of urethral diverticula in men. *Scand J Urol Nephrol.* 1994; 28(2):207-10.
9. Singh V, Singh KM, Sinha RJ. Tricholithobozoar: an unusual long-term complication of hypospadias surgery. *Urol J.* 2010;7(1):15.
10. Kaviani A, Hosseini J, Vazirmia AR. A huge penile mass which turned out to be an epidermoid inclusion cyst. *Urol J.* 2009;6(2):135-7.
11. Papali AC, Alpert SA, Edmondson JD, Maizels M, Yerkes E, Hagerty J, et al. A review of pediatric glans malformations: a handy clinical reference. *J Urol.* 2008;180(4S):1737-42.
12. Howe AS, Hanna MK. Management of 220 adolescents and adults with complications of hypospadias repair during childhood. *Asian J Urol.* 2017;4(1):14-7.
13. Giambanco A, Pensabene M, Giuffrè M, Cimador M. Epidermal inclusion cyst of the penis after urethroplasty causing an urethro-cutaneous fistula: a first case report. *Pediatr Med Chir.* 2013;35:288-9.
14. Guler Y, Tatar Z, Ucpinar B, Erbin A. An epidermal cyst of the penis after distal hypospadias surgery: a case report. *J Med Case Rep.* 2018; 12(1):378.

**Cite this article as:** Saran RK, Mirdha K, Saran S, Takhar RP. Unusual complications of hypospadias repair: diagnosis and management. *Int J Res Med Sci* 2019;7:3440-3.