

Case Report

Management mature sacrococcygeal teratoma: a case report

Budiman Ritonga, Kadek Deddy Ariyanta*, I. Made Darmajaya

Department of General Surgery, Sanglah Hospital, Faculty of Medicine Udayana University, Denpasar, Bali, Indonesia

Received: 28 August 2019

Revised: 04 September 2019

Accepted: 07 September 2019

***Correspondence:**

Dr. Kadek Deddy Ariyanta,

E-mail: deddyariyanta@yahoo.com

Copyright: © the author(s), publisher and licensee Medip Academy. This is an open-access article distributed under the terms of the Creative Commons Attribution Non-Commercial License, which permits unrestricted non-commercial use, distribution, and reproduction in any medium, provided the original work is properly cited.

ABSTRACT

Mature sacrococcygeal teratoma (SCT) are uncommon neoplasm comprised of mixed elements derived from three germ layers. They attract attention because of their gross appearance and bizarre histology. Tumor of the sacrococcygeal region, referred to as sacrococcygeal teratomas (SCTs) in most reports, generally present in two distinct fashions: neonates with large predominately external lesions, which are detected in utero or at birth and are rarely malignant; and older infants and children who present with primarily hidden pelvic tumors with a much higher rate of malignancy. Sacrococcygeal teratomas are the most common extragonadal tumor in neonates, accounting for up to 70% of all teratomas in childhood. A 3 to 4:1 female to male ratio is generally reported. Surgical resection remains the mainstay of therapy and recurrence is rare following complete excision. A 14 years old girl was presented to us by her parents with a mass at the buttock since birth. She was delivered at home by traditional midwife after a term, unsupervised pregnancy to a 35 years old woman. Both pregnancy and delivery were uneventful. Direct rectal examination revealed a mass has displaced the recto-sigmoid anteriorly. The CT scan revealed a heterogenous mass with a solid, cystic, and multiple classification density at the anterior of coccygeus bone, and push the coccygeus to the posterior. The mass infiltrated the subcutis, and attached to the posterior aspect of rectum. A 14 years old girl presented by mature SCT since newborn comprising ectoderm, mesoderm, and endoderm tissue. She had a complete surgical excision (including coccygectomy) with primary wound closure. A complete surgical excision remains the mainstay of therapy of mature SCT.

Keywords: Childhood, Neoplasm, Sacrococcygeal teratoma, Surgical excision

INTRODUCTION

Tumors of the sacrococcygeal region, referred as sacrococcygeal teratomas (SCTs) in most reports, generally present in two distinct fashions: neonates with large predominantly external lesions, which are detected in utero or at birth and are rarely malignant; and older infants and children who present with primarily hidden pelvic tumors with a much higher rate of malignancy.¹ Sacrococcygeal teratomas are the most common extragonadal tumor in neonates, accounting for up to 70% of all teratomas in childhood. A 3 to 4:1 female to male ratio is generally reported.² Surgical resection

remains the mainstay of therapy and recurrence is rare following complete excision.

CASE REPORT

A 14 years old girl was presented to us by her parents with a mass at the buttock since birth. She was delivered at home by traditional midwife after a term, unsupervised pregnancy to a 35 years old woman. Both pregnancy and delivery were uneventful. On clinical examination the girl was active, healthy children with a mass attached to the sacrococcygeal region (Figure 1, Figure 2, Figure 3).



Figure 1: 12 year old girl with a mature sacrococcygeal teratoma.

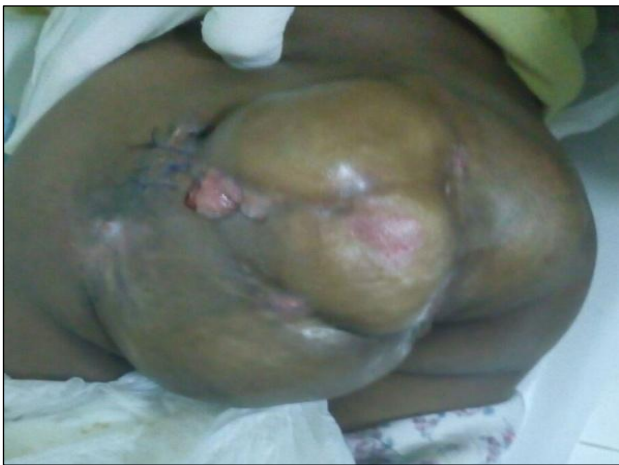

Figure 2: 12 year old girl with a mature sacrococcygeal teratoma: closer view.

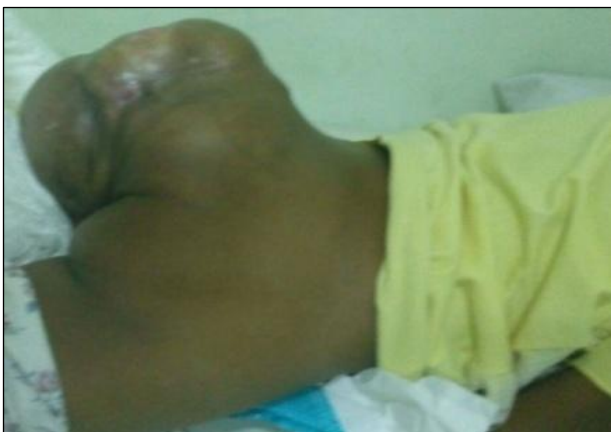

Figure 3: 12-year-old girl with a mature sacrococcygeal teratoma: a lateral view.

There was no evidence of any neurological deficit. The mass consist of solid and cystic lesion. Digital examination revealed normal anal sphincteric tone and has displaced the recto-sigmoid anteriorly.

The relevant hematological and biochemical investigation were within normal limits. A plain radiography of lumbosacral region revealed a clear demarcation between the limb and the spine (Figure 4, Figure 5).

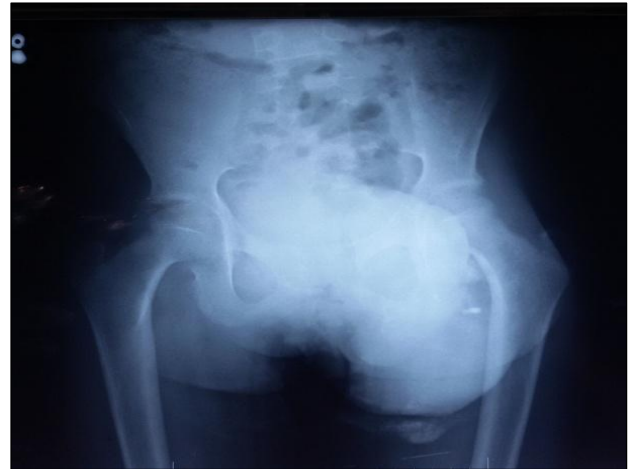

Figure 4: a plain radiography (anteroposterior view)

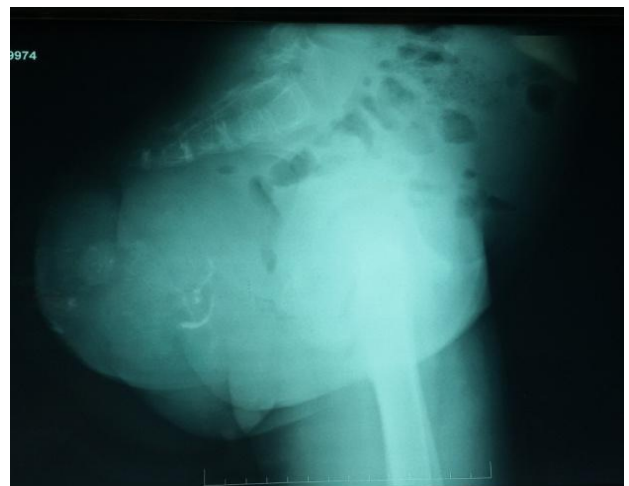

Figure 5: a plain radiography: a lateral view.

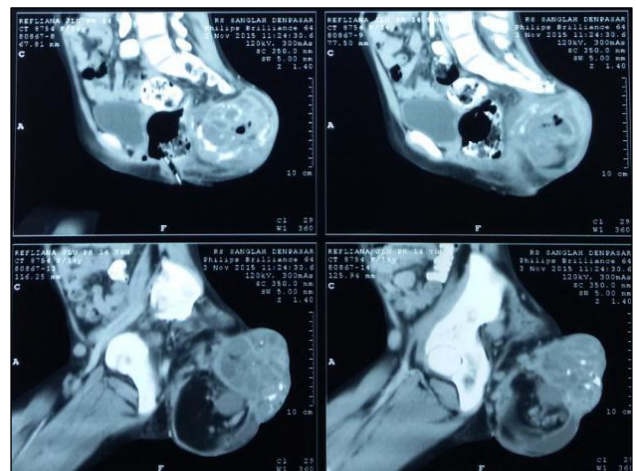


Figure 6: A sagittal view of the CT scan.

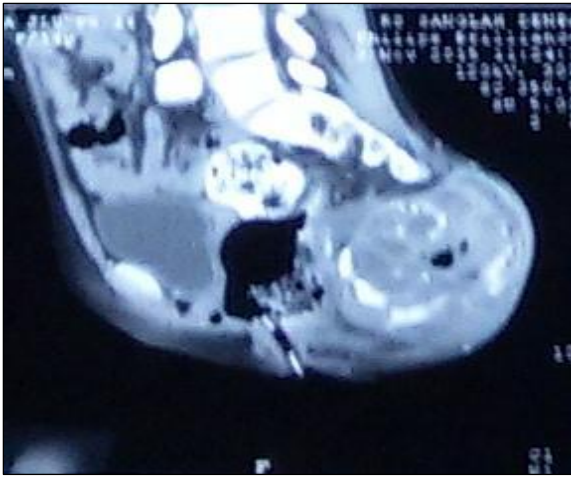


Figure 7: A sagittal view of the CT scan (single).

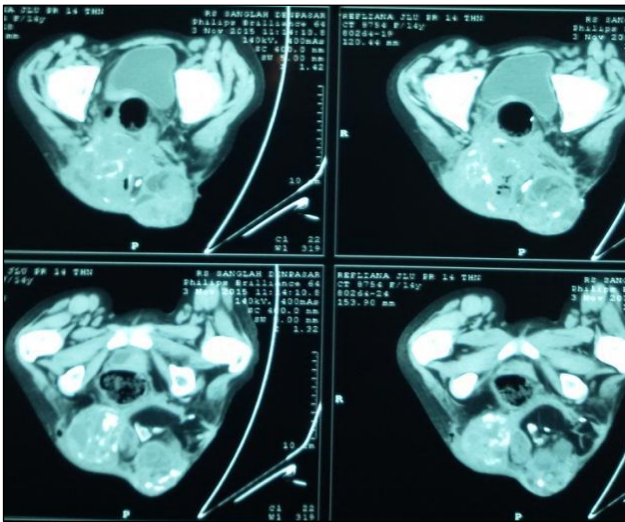


Figure 8: an axial view of the CT scan.

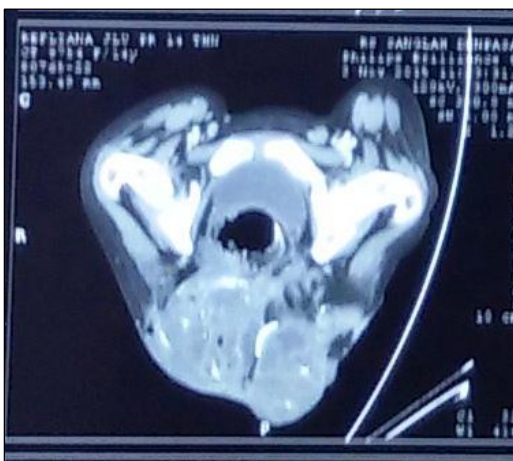

Figure 9: an axial view of the CT scan (single).

Her alpha-feto protein level (5 ng/mL) were in the normal range. The CT scan revealed a heterogenous mass with a solid, cystic, with multiple calcification density at the

anterior of coccygeus bone and push the coccygeus to the posterior (Figure 6, Figure 7, Figure 8, Figure 9). The mass has infiltrated the subcutaneous and attached to the posterior aspect of rectum.

Surgical intervention

The patient was operated in the prone position. The sacrococcygeal region was opened by plastic surgical principles. After an informed consent, surgical excision (including coccygectomy), the tumor tissue and the surrounding tissues to which it adhered were dissected from the rectum. The tumor was totally removed. The defect was closed accomplished via a flap (Figure 10).

Histological examination of the excised tissue was consistent with mature SCT (with no evidence of malignancy).

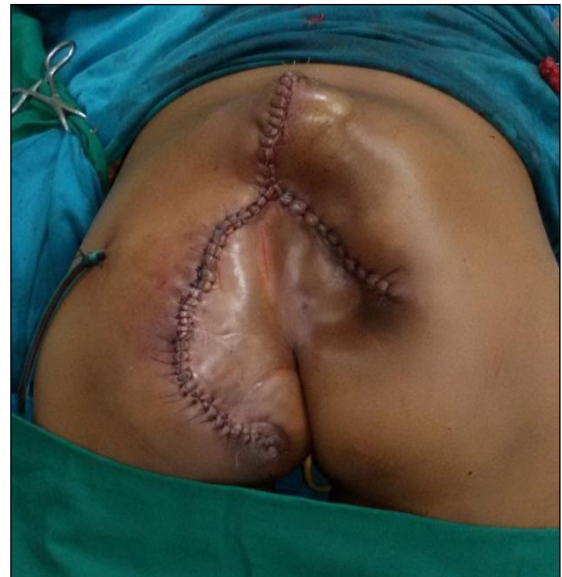

Figure 10: immediate post-operative view of mature sacrococcygeal teratoma.

DISCUSSION

Complete resection of the tumor as early as possible is essential. The rectum and genital structures are often distorted by tumor, but usually can be preserved in the course of resection.^{1,2} Vaseline packing in the rectum facilitates its identification throughout the procedure. En bloc excision, including the coccyx is preferable.³ Failure to remove the coccyx is associated with a high recurrence rate.⁴ An acceptable gluteal crease and perineum is formed by appropriate positioning of the perianal musculature. The used of plastic surgical principles to close the skin improved the cosmetic appearance of the scar.²

Later complications of the mass effect and/or surgery may include neurogenic bladder, other forms of urinary incontinence, fecal incontinence, and other chronic

problems resulting from accidental damage to or sacrifice of nerves and muscles within the pelvis.³

The recurrence rate of sacrococcygeal teratomas varies between 7.5% and 22%.⁴ In contrast to previous reports, Bilik et al. found a higher recurrence rate for primary sacrococcygeal teratomas with larger mean diameters (11.1 (3.2) cm with recurrences 7.9 (4.4) cm with no recurrence (mean (SD)); $p = 0.07$).⁵

CONCLUSION

Early management of mature sacrococcygeal is important to prevent malignancy and the tumor attachment to another surrounding vital tissue.

A complete surgical excision remains the mainstay of therapy of mature SCT.

Funding: No funding sources

Conflict of interest: None declared

Ethical approval: Not required

REFERENCES

1. Martin LJ, Puligandla PS, Kenneth S. Teratomas, Dermoids and other Soft Tissue Tumor. *Aschraft Pediatr Surg.* 2005;70:920.
2. Rescorla FJ. Teratoma and Other Germ Cell Tumors. *Coran Pediatric Surgery.* 2006;37:507-15.
3. Bittmann S, Bittmann V. Surgical experience and cosmetic outcomes in children with sacrococcygeal teratoma. *Curr Surg.* 2006;63(1):51-4.
4. Dewan PA, Davidson PM, Campbell PE, Tiedemann K, Jones PG. Sacrococcygeal teratoma: has chemotherapy improved survival? *J Pediatr Surg.* 1987;22(3):274-7.
5. Bilik R, Shandling B, Pope M, Thorner P, Weitzman S, Ein SH. Malignant benign neonatal sacrococcygeal teratoma. *J Pediatr Surg.* 1993 Sep 1;28(9):1158-60.

Cite this article as: Ritonga B, Ariyanta KD, Darmajaya IM. Management mature sacrococcygeal teratoma: a case report. *Int J Res Med Sci* 2019;7:3891-4.