

## Case Report

# A rare case of isolated gall bladder perforation in blunt trauma abdomen: a case report

Omesh K. Meena\*, Monish Raj

Department of General Surgery, VMMC and Safdarjung Hospital, New Delhi, India

**Received:** 11 November 2019

**Revised:** 19 December 2019

**Accepted:** 27 December 2019

### \*Correspondence:

Dr. Omesh K. Meena,

E-mail: [omeshmeena@gmail.com](mailto:omeshmeena@gmail.com)

**Copyright:** © the author(s), publisher and licensee Medip Academy. This is an open-access article distributed under the terms of the Creative Commons Attribution Non-Commercial License, which permits unrestricted non-commercial use, distribution, and reproduction in any medium, provided the original work is properly cited.

## ABSTRACT

Blunt trauma abdomen leading to gallbladder perforation is a rare event usually recognized on evaluation and treatment of other visceral injuries during laparotomy. The gallbladder is relatively a well-protected organ. Isolated gallbladder perforation is extremely rare. The clinical presentation is variable, early diagnosis and treatment is of extreme importance to reduce morbidity and mortality associated with gallbladder perforation. We report a case of a patient who sustained isolated gallbladder injury following blunt trauma abdomen to emergency department in Safdarjung Hospital, New Delhi.

**Keywords:** Blunt trauma, Cholecystectomy, Gall Bladder, Perforation

## INTRODUCTION

Isolated gallbladder injuries are uncommon and difficult to diagnose.<sup>1</sup> The gallbladder is relatively a well-protected organ being surrounded by liver, omentum and intestine and shielded by rib cage.<sup>2,3</sup>

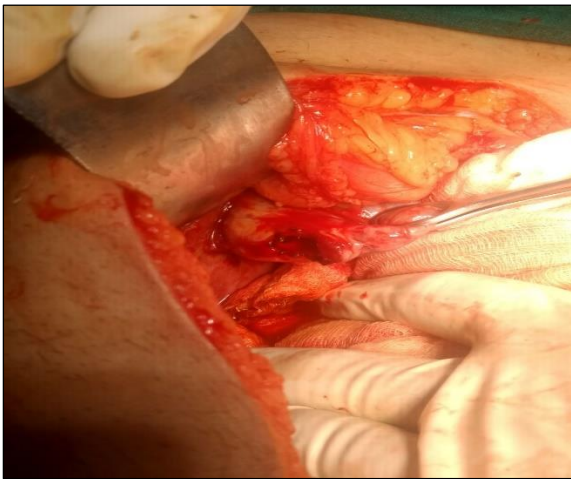
Gallbladder rupture following blunt trauma is rare and is usually associated with other visceral injuries and isolated gallbladder injury is even rarer.<sup>2-6</sup>

Gallbladder injury arises from compressive and shearing forces, most commonly in road traffic accidents. The spectrum of injuries includes contusion, laceration and avulsion.<sup>7</sup> Patients with isolated gallbladder injury are at increased risk for significant morbidity and mortality due to non-specific presentation leading to delay in diagnosis. Computed tomography is the investigation of choice for diagnosing gallbladder injury and treatment of choice is cholecystectomy.<sup>8</sup>

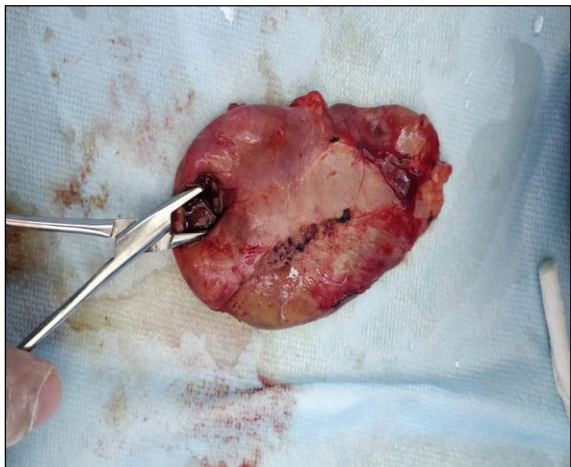
## CASE REPORT

A 38 years old male patient presented to surgical emergency, Safdarjung Hospital, New Delhi with alleged history of road traffic accident under influence of alcohol after 12 hours of injury with injuries sustained over right side of chest, abdomen and limbs. On examination he was conscious and oriented with breath smell of alcohol. Pulse rate was 107/minute and blood pressure was 108/74 mm Hg. Multiple abrasions and lacerated wounds were noted on right side of his head, thorax and abdomen. Bilateral air entry was equal with no evidence of tenderness, bony crepitus or subcutaneous emphysema. Abdomen was not distended, diffuse tenderness noted more on right side of the abdomen with guarding and no rigidity or rebound tenderness. Bowel sounds were present. Peripheral limb examination was within normal limits. Patient was managed on trauma protocol and investigated for injuries. Chest x ray revealed no rib fractures, hemothorax or pneumothorax. Ultrasound fast revealed moderate free fluid in abdomen with septations

in pelvis likely hemoperitoneum. NCCT head was within normal limits. Patient was initially managed conservatively with continuous monitoring. However, in view of developing hemodynamic instability, patient was taken up for exploratory laparotomy. Intraoperatively around 1.5 litre of bilious contamination noted in peritoneal cavity with 1\*1 cm perforation in gallbladder fundus (Figure 1 and 2). Rest of visceral organs were grossly normal for which cholecystectomy with subhepatic drain placement was done under anaesthesia. Post-operative period was uneventful, and patient was discharged on 4th post-operative day and followed up on outpatient basis.



**Figure 1: Intraoperative picture showing gall bladder perforation at fundus.**



**Figure 2: Gall bladder specimen showing perforation.**

## DISCUSSION

Injury to gallbladder following blunt trauma abdomen is rare and accounts for about 2% of all other abdominal injuries.<sup>2,3</sup> Isolated gallbladder injury is even rarer, gallbladder rupture occurs predominantly in males as was the case in this patient. Children especially are affected because of their increase vulnerability to direct

abdominal trauma and also because of poor anterior abdominal wall muscular development.<sup>2</sup>

Thin walled gallbladder is more prone than a diseased gallbladder which is thickened and fibrotic from chronic inflammation from blunt abdominal trauma.<sup>2,3</sup> Gallbladder distension is almost always present for perforation to occur, alcohol enhances gastrin and secretin secretions which stimulate bile flow and high serum alcohol levels as was in this patient elevates the common bile duct pressure by increasing sphincter of Oddi's tone.<sup>2,3</sup> The majority of gallbladder injuries occur following road traffic accidents, following significant falls and direct blow to abdomen.<sup>3,5</sup>

Several types of gallbladder injuries may result from blunt trauma to abdomen and are classified as contusion, avulsion, laceration and traumatic cholecystitis.<sup>2</sup> Laceration of gallbladder also termed perforation is the most common type of injury to gallbladder as was the case in this patient. Avulsion injury of gallbladder is the second most common type and has 3 subtypes: 1) partial avulsion- gallbladder is partially torn from liver bed, 2) complete avulsion- gallbladder is completely avulsed from liver bed but with intact cystic duct and artery, 3) total avulsion- also termed traumatic cholecystectomy where gallbladder lies free in the abdomen.<sup>9</sup> Delayed perforation can also occur, following hematoma of gallbladder wall developing into an area of necrosis, or blood clot occluding the cystic duct and precipitating infection, gangrene and late perforation.

Isolated gallbladder rupture due to blunt trauma abdomen though rare, can occur and may lead to diagnostic challenge especially with delayed presentation. Persistent bile leak causes sequestration of fluid. The clinical presentation is carried and nonspecific, resulting in delay in diagnosis. Damage to uninfected gallbladder leads to sterile bile in abdomen and may take up to 6 weeks to become apparent. Unless bacterial peritonitis supervenes, biliary peritonitis can be innocuous.<sup>10</sup> Diagnosis of gallbladder perforation is mostly incidental at laparotomy for evaluation and treatment of other visceral organ injuries. Bile stained aspirate with ultrasound report of normal spleen and liver should raise suspicion for possible biliary tract injury, although it is non-specific and may be from trauma to liver and upper gastrointestinal tract also.

Ultrasonography and computed tomography scans are found valuable when bile leak becomes encapsulated forming a mass, while Tc99m- HIDA cholecystoscintigraphy is more accurate means of detecting bile leak.<sup>9</sup> Magnetic resonance imaging and endoscopic retrograde cholangiopancreatography are other diagnostic modalities in blunt trauma abdomen.<sup>11</sup>

Various treatment modalities have been described for management of gallbladder injury: expectant observation, drainage, cholecystorrhaphy or cholecystostomy but

cholecystectomy is now the treatment of choice either open or laparoscopic.<sup>5-7,11</sup> In this case, exploratory laparotomy and cholecystectomy was conducted due to diagnostic uncertainty. High morbidity and mortality in gallbladder perforation patients are due to associated other visceral organ injuries.<sup>3-5,11</sup> However, no deaths have ever been reported in patients with isolated gallbladder perforation treated surgically. this patient did well postoperatively and was discharged on 4<sup>th</sup> post-operative day and followed up in outpatient basis.

*Funding: No funding sources*

*Conflict of interest: None declared*

*Ethical approval: Not required*

## REFERENCES

1. Liess BD, Awad ZT, Eubanks WS. Laparoscopic cholecystectomy for isolated traumatic rupture of the gallbladder following blunt abdominal injury. J Laparoendoscopic Advan Surg Techniq. 2006;16(6):623-5.
2. Soderstrom CA, Maekawa KA, DuPriest Jr RW, Cowley RA. Gallbladder injuries resulting from blunt abdominal trauma: an experience and review. Ann Surg. 1981;193(1):60.
3. Schachter P, Czerniak A, Shemesh E, Avigad I, Lotan G, Wolfstein I. Isolated gallbladder rupture due to blunt abdominal trauma. HPB Surg. 1989;1(4):359-62.
4. De Raet J, Lamote J, Delvaux G. Isolated traumatic gallbladder rupture. Acta Chirurgica Belgica. 2010;110(3):370-5.
5. Wiener I, Watson LC, Wolma FJ. Perforation of the gallbladder due to blunt abdominal trauma. Arch Surg. 1982;117(6):805-7.
6. Bainbridge J, Shaaban H, Kenefick N, Armstrong CP. Delayed presentation of an isolated gallbladder rupture following blunt abdominal trauma: a case report. J Med Case Reports. 2007;1(1):52.
7. Ameh EA. Cholecystitis in children in Zaria, Nigeria. Annals Trop Paediatr. 1999;19(2):205-9.
8. Salomão RM, Magalhães NC, Silva FV, Iglesias AC. Colecistite aguda decorrente de hemorragia intraluminal da vesícula biliar após trauma abdominal fechado. Rev Col Bras Cir. 2008;35(5):346-8.
9. Chen X, Talner LB, Jurkovich GJ. Gallbladder avulsion due to blunt trauma. Am J Roentgenol. 2001;177(4):822.
10. Sharma OM. Blunt gallbladder injuries: presentation of twenty-two cases with review of the literature. J Trauma Acute Care Surg. 1995;39(3):576-80.
11. Kohler R, Millin R, Bonner B, Louw A. Laparoscopic treatment of an isolated gallbladder rupture following blunt abdominal trauma in a schoolboy rugby player. Brit J Sports Med. 2002;36(5):378-9.

**Cite this article as:** Meena OK, Raj M. A rare case of isolated gall bladder perforation in blunt trauma abdomen: a case report. Int J Res Med Sci 2020;8:754-6.