

## Original Research Article

# Feasibility of minimally invasive management in patients with forgotten double J stent: a single centre experience

Mohd Hamid Shafique Ahmed, Harshad Toshniwal, Prakash W. Pawar\*, Ajit S. Sawant, Amandeep Arora, Syed Ali Abbas, Jitendra K. Sakharani, Neel Shah

Department of Urology, Lokmanya Tilak Municipal Medical College and General Hospital, Mumbai, Maharashtra, India

**Received:** 02 December 2019

**Accepted:** 06 December 2019

**\*Correspondence:**

Dr. Prakash W. Pawar,

E-mail: [praxpawar@gmail.com](mailto:praxpawar@gmail.com)

**Copyright:** © the author(s), publisher and licensee Medip Academy. This is an open-access article distributed under the terms of the Creative Commons Attribution Non-Commercial License, which permits unrestricted non-commercial use, distribution, and reproduction in any medium, provided the original work is properly cited.

### ABSTRACT

**Background:** aim of the study was to present the experience in managing forgotten/encrusted Double J (DJ) ureteral stents and to review the literature on the subject.

**Methods:** Author retrospectively studied patients presenting to the Outpatient Department from January 2016 to January 2019 with forgotten DJ stent(s) (six or more than six months after the insertion). Data was collected for age, gender, indication for DJ stenting, clinical features at presentation, radiological imaging and surgical procedure performed to extract the DJ stents. The post-operative stay, complications of the procedures and morbidity was also studied.

**Results:** During the study period, a total 32 patients reported to the department with history of forgotten DJ stents. Most common age group involved was 41-60 years. Most common presenting symptoms were lower urinary tract symptoms (LUTS) or dysuria. Duration of stent in-situ ranged from 6 month to 15 years. Most common sites of encrustations along the forgotten DJ stent were ureter and kidney followed by urinary bladder. Fluoroscopic guided DJ stent removal was done in 8 patients. A combination of Cystolithotripsy, URSL and PCNL was needed to clear the stone and extract the DJ stent in remaining patients.

**Conclusions:** Forgotten/encrusted DJ stent may lead to complications ranging from urinary tract infections to loss of renal function. They can be safely and successfully removed, and the renal function can be preserved. Endo-urological management of forgotten encrusted stents is highly successful and often avoids the need for open surgical techniques.

**Keywords:** Cystoscopy, Cystolithotripsy, Encrustation, Forgotten DJ stent, Percutaneous nephrolithotomy, Ureterorenoscopy

### INTRODUCTION

Ureteral stents are the mainstay of today's urological armamentarium. Since their introduction into clinical use, Double J (DJ) stents have been widely used in urological practice.<sup>1</sup> DJ stent has a J-shaped end at both ends which prevents migration of stent from kidney and urinary bladder. DJ stents are commonly used for treating ureteric obstruction due to stones and tumors.<sup>2-4</sup> Other uses include drainage after ureteric surgery and iatrogenic

injuries.<sup>5</sup> A DJ stent may also be prophylactically inserted to prevent ureteric injury during any complex abdominopelvic surgery.<sup>6,7</sup> Now-a-days, the use of DJ stent is common but it has various complications such as hematuria, urinary tract infection (UTI), abdominal pain, stent dysuria etc. A forgotten DJ stent may have severe complications like encrustation followed by stone formation, recurrent UTI, and sometime renal failure.<sup>8,9</sup> A report by el-Faqih et al, shows that stent encrustation rate increases from 9.2% for stent in-situ for less than 6 weeks

to 47.5% at 6 to 12 weeks to 76.3% at more than 12 weeks.<sup>10</sup> For the above reason it is advisable to change or remove DJ stent within 6 weeks to 12 weeks. A forgotten stent is very frequently complicated and poses a clinical and legal dilemma. The management of a forgotten DJ stent may be time consuming, difficult, complex, risky and expensive. Several urological procedures are often necessary to remove the severely encrusted DJ stent safely. The methodology depends on the clinical status and often comprises extracorporeal shock wave lithotripsy (ESWL), cystolithotripsy, uretero-rensoscopy (URS) and even percutaneous nephrolithotomy (PCNL).

This study was done with the aim to know the consequences, management and potential complications in cases of forgotten DJ stent. In this study three-year experience of patients with forgotten DJ stents and their management is shared.

## METHODS

This was a three-year retrospective study carried out at Lokmanya Tilak Municipal Medical College and General Hospital, Mumbai, Maharashtra, India, between January 2016 to January 2019.

### Inclusion criteria

- Patients who presented to the outpatient department with a forgotten DJ stent, six months or more after insertion, irrespective of age, sex and comorbidities.

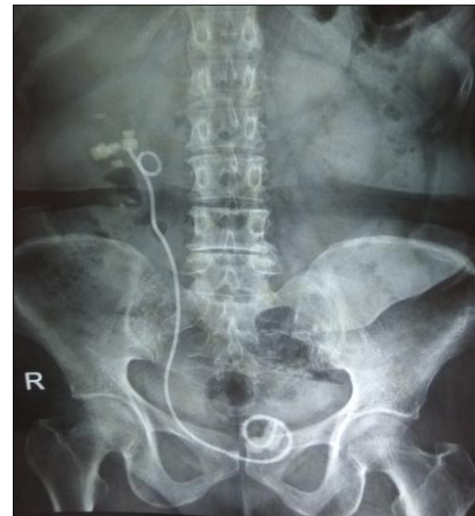### Exclusion criteria

- No patient with a forgotten DJ stent was excluded.

A DJ stent retained for 6 months or more was considered as a forgotten DJ stent. Age, gender, indication for DJ stent, duration of stent insertion, clinical features at presentation, radiological images and surgical procedures performed to extract the stents were noted. Post-operative stay, complications of the procedures and morbidity were also recorded.

The pre-operative evaluation consisted of a urine analysis, serum creatinine level, complete blood count, urine culture and antibiotic sensitivity. X ray KUB (kidney ureter bladder) and Ultra sonography KUB was also done in all the patients (Figure 1). CT (Computed tomography) urography was done in patients with serum creatinine level of 1.4 mg/dl or less. In patients with serum creatinine level of more than 1.4 mg/dl, NCCT (non-contrast computed tomography) KUB followed by renal scintigraphy (DTPA scan / EC scan) was done to know the functional status of the kidney. The patients' anatomy, stent encrustation, associated stone burden and degree of complexity of the situation such as broken or migrated stents, were evaluated with above mentioned imaging. Treatment decisions were made on the basis of imaging findings and the clinical presentation.

Nephrectomy was considered if the stented kidney was non-functional.



**Figure 1: X-Ray KUB showing Stone along the DJ stent.**

Intervention was performed after antibiotic treatment in patients with a positive urine culture. All patients received antibiotics prophylaxis preoperatively. Endourological procedures under general or local anaesthesia in one or more session were required. Various combinations of the following were used to remove the stent and related stone burden: Simple cystoscopic stent removal, cystolithotripsy, uretero-rensoscopy and percutaneous nephrolithotomy (PCNL). Holmium laser lithotripter or pneumatic lithotriper was used as intracorporeal lithotripter during above mentioned procedures.

X ray KUB and Ultrasonography KUB was used to evaluate the post-operative residual stone burden. Patients suspected of having residual stone or persistent hydronephrosis were evaluated by NCCT KUB. Patients were considered stone-free if the postoperative imaging studies revealed no stones greater than 3mm. This study was approved by Institutional Ethics Committee.

## RESULTS

In this retrospective study of 32 patients with forgotten DJ stent, there were 19 (59.3%) males and 13(40.7%) females, with a male to female ratio of 1.46:1. Amongst the studied cases, most common age group (Table 1) involved was 41-60 years (46.6%) followed by 21-40 years. Most of the patients presented with Lower urinary tract symptoms (LUTS) or dysuria, a few patients presented with hematuria (Table 2). Stent related duration of symptoms upto 6 months were in 23 patients, whereas 9 patients had duration of symptoms for more than 6 months. Duration of stent in-situ ranged from 6 months to 15 years (Table 3).

**Table 1: Age incidence.**

| Age group (Year) | No of patients | Percentage % |
|------------------|----------------|--------------|
| 1-20             | 6              | 18.75        |
| 21-40            | 7              | 21.87        |
| 41-60            | 15             | 46.87        |
| 61-80            | 4              | 12.5         |

**Table 2: Clinical presentation.**

| Presentation | No of cases | Percentage % |
|--------------|-------------|--------------|
| LUTS         | 18          | 56.25        |
| Dysuria      | 17          | 53.12        |
| Flank pain   | 10          | 31.25        |
| hematuria    | 2           | 6.25         |

**Table 3: Duration of Stent in situ.**

| Duration (year) | No of cases |
|-----------------|-------------|
| 0.5 - 1         | 4           |
| >1 - 2          | 7           |
| >2 - 3          | 3           |
| >3 - 4          | 6           |
| >4 - 5          | 4           |
| >5 - 6          | 2           |
| >6              | 6           |

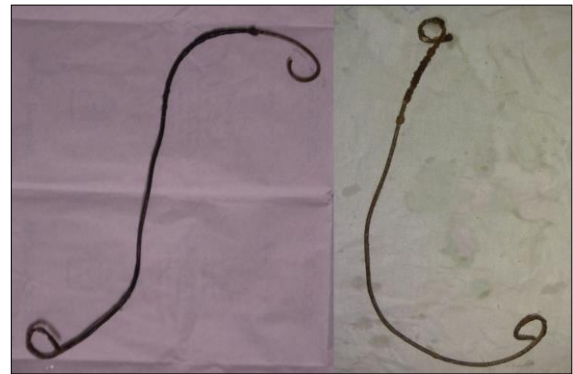Table 4 shows the initial indications for the DJ stenting. The most common indications were URSL followed by PCNL, 18 patients had forgotten DJ stent on left site, 12 on the right site whereas 2 patients had bilateral stents. Serum creatinine levels were more than 1.4 mg/dl in 4 patients.

**Table 4: Initial indications for DJ stenting.**

| Indication                    | No. of cases |
|-------------------------------|--------------|
| URSL                          | 8            |
| PCNL                          | 6            |
| Obstructive uropathy          | 4            |
| Pyelolithotomy                | 4            |
| Ureterolithotomy              | 4            |
| Post hysterectomy             | 2            |
| Vesico-vaginal fistula repair | 2            |
| Pre ESWL                      | 1            |
| Genitourinary tuberculosis    | 1            |

Table 5 shows the location of encrustations. Most common site of encrustations (Figure 2) along the stent was ureter and kidney followed by urinary bladder. More than one site of encrustation was present in seven patients. Three patients had no encrustations along the DJ stent. All the procedures for treatment was done under anaesthesia of which 13 patients received spinal anaesthesia and 19 patients received general anaesthesia. 8 patients in whom encrustations were either absent or minimal required DJ stent removal under fluoroscopy

guidance. Other patients underwent procedures such as Cystolithotripsy, URSL and PCNL (Table 6).



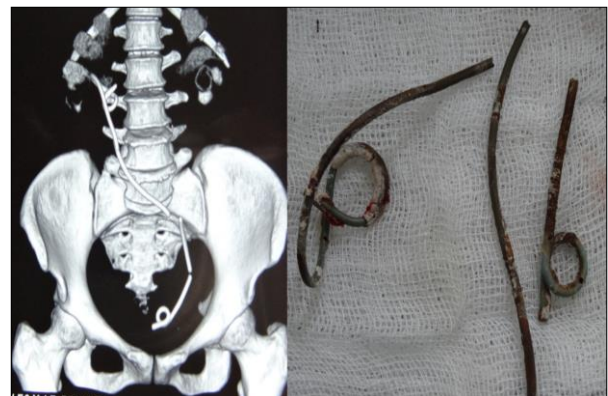
**Figure 2: Encrusted DJ stent.**

**Table 5: Location of Encrustation / Stone.**

| Location                  | No of cases |
|---------------------------|-------------|
| Kidney                    | 8           |
| Ureter                    | 9           |
| Bladder                   | 5           |
| Kidney + Bladder          | 4           |
| Kidney + Ureter           | 1           |
| Ureter + Bladder          | 1           |
| Kidney + Ureter + Bladder | 1           |
| No Encrustation           | 3           |

**Table 6: Procedures.**

| Procedure                            | No of cases |
|--------------------------------------|-------------|
| DJ stent removal under fluroguidance | 8           |
| URSL                                 | 6           |
| Cystolithotripsy                     | 5           |
| PCNL                                 | 4           |
| Cystolithotripsy + PCNL              | 5           |
| Cystolithotripsy + URSL              | 1           |
| URSL + PCNL                          | 1           |
| Bilateral PCNL                       | 1           |
| Cystolithotripsy + Nephrectomy       | 1           |



**Figure 3: Broken DJ stent.**

One patient underwent nephrectomy in view of non-functioning kidney. No intra-operative or post-operative complications occurred in any patient. All the stents were removed intact, except in 4 patients (Figure 3). Examination of the broken stents showed that break had occurred at points where the encrustation had made the stent very brittle. Mean hospital stay was 3 days. Patients in whom DJ stent were kept after stone clearance was removed 2 weeks after surgery. All the patients were followed up for six months.

## DISCUSSION

Double J stents are commonly placed for duration of 4 - 12 weeks with an intention to prevent or relieve upper urinary tract obstruction and following reconstructive surgeries.<sup>11</sup> Indwelling Double J stents may cause irritative urinary symptoms, flank pain, hematuria etc. Efforts have been made to avoid ureteric stent complications like encrustations and recurrent infections.

The encrustation of forgotten stents with a severe stone burden is a serious problem due to recurrent urinary tract infections, hematuria, urinary tract obstructions, and renal failure.<sup>12</sup> The etiology of encrustation is multifactorial. The risk factors are prolonged duration of stenting, urinary sepsis, history of or simultaneous occurrence of stone disease, metabolic abnormalities, congenital anomalies, chronic renal failure etc.<sup>13</sup> Conflicting reports suggest the effect of stent composition on the severity of encrustation. Tunney et al observed that the risk of encrustations dependent on the type of stent material.<sup>14</sup> Conversely, Wollin et al, reported that the types of stent material were not significantly co-related with the amount of encrustations.<sup>15</sup>

Lack of follow up with long term placement of DJ stent and poor compliance have been proposed as the common reasons for DJ stent retainment. The most prominent factors were the urolithiasis and prolonged duration of stenting. Kawahara et al, reported encrustation rates of 26.8% in <6 weeks, 56.9% at 6 to 12 weeks and 75.9% in >12 weeks of retained double J stents. They concluded that ureteral stent encrustation was related to the time in-situ. Heavily encrusted ureteral stents necessitated additional procedures for removal. The exact interval for removal of an indwelling ureteral stent to avoid additional procedures for removal is difficult to determine.<sup>16</sup> Bultitude et al, reported that 42.8% of the stents in their patients became difficult to remove cystoscopically within 4 months, and 14.3% at 2 months.<sup>13</sup> Okuda et al, reported on 15 irremovable ureteral stents in Japanese patients. The mean indwelling times of these stents was 20 months.<sup>17</sup>

The preoperative evaluation of patients with forgotten DJ stent is another important subject requiring discussion. Weedon et al, reported that NCCT estimated the actual stone burden of encrustation proximal to the stent more accurately when compared with X-ray KUB.<sup>18</sup> NCCT

identifies the localizations of stent encrustations more precisely, specially in cases of low burden of stone and radio-lucent stones.<sup>19</sup> It was recommended that all patients with forgotten stents be routinely evaluated by NCCT in the pre-operative period.

The management of forgotten and encrusted DJ stent is a challenging condition for the urologist. Multiple endourological procedures may often be required. Rarely open surgery may be necessary. If X ray KUB doesn't reveal any encrustation or minimal encrustation, stent can be cystoscopically removed using grasping forceps, under the guidance of fluoroscopy. The most important aspect of this procedure is the avoidance of excessive force, which may lead to serious complications such as ureteral injuries or avulsion. If encrustation is at the distal end of the stent, an attempt can be made to remove it by endoscopic Cystolithotripsy. Larger encrustations may need PCCL (percutaneous cystolithotripsy). When the stent cannot be removed by pulling gently with a grasping forceps, a semi rigid URS is introduced into the ureter between the stent and ureteral wall. If encrustation is only at the distal or middle portion, the stent is removed following fragmentation by laser lithotripsy. If the proximal part of the stent shows excessive encrustation and severe stone burden, a PCNL is done. Except for the nephrectomy case with non-functioning kidney, all cases were managed successfully endoscopically, without any complications, and without any open surgery.

To overcome the issues of forgotten stents, counseling of the patients and maintenance of stent registry has been suggested. Such a registry would help in maintaining data relating to the insertion and lifespan of ureteric stents. It could also be used to send automatic e-mail/mobile SMS reminders when the stents have reached a user defined 'end of life'. It could also help to track all the forgotten or lost stents electronically. Lynch et al, have described and analyzed a unique computerized system that tracks ureteral stents and automatically sends a notice by e-mail to clinical staff if a stent became overdue for removal.<sup>20</sup>

The system ensured improved patient safety with an element of protection from potential litigation. Sabharwal et al, evaluated the feasibility of a computer-based stent registry with patient-directed automated information system to prevent retained DJ stents and reported that it was feasible in a clinical setting.<sup>21</sup>

A prospective study was, however, needed for the evaluation of its efficacy in preventing retained stents. Patil et al, reported their experience in the management of forgotten stents and the role of stent registry in preventing DJ stent-related morbidity.<sup>22</sup> In addition to the retrospective design of study and small population size, another limitation was the inability to collect any data on the composition of stones of the patient with encrusted DJ stent. A large multicenter study is also needed for



computer-based registry to decrease the incidence of forgotten DJ stents.

## CONCLUSION

Forgotten/ encrusted DJS may lead to complications ranging from infections of the urinary tract to the loss of renal function. When a case with a forgotten DJS is admitted, it should be kept in mind that excessive encrustation may also be encountered, and combined endo-urologic methods may be necessary for management. Forgotten stents can be safely and successfully managed and renal function can be preserved by means of endo-urologic techniques.

*Funding: No funding sources*

*Conflict of interest: None declared*

*Ethical approval: The study was approved by the Institutional Ethics Committee*

## REFERENCES

1. Finney RP. Experience with new double J ureteral catheter stent. *J Urol.* 1978 Dec;120(6):678-81.
2. Saltzman B. Ureteral stents. Indications, variations, and complications. *Urol Clin North Am.* 1988 Aug;15(3):481-91.
3. Chew BH, Knudsen BE, Denstedt JD. The use of stents in contemporary urology. *Curr Opin Urol.* 2004 Mar 1;14(2):111-5.
4. Hepperlen TW, Mardis HK, Kammandel H. The pigtail ureteral stent in the cancer patient. *J Urol.* 1979 Jan 1;121(1):17-8.
5. Gogas, Christos Markopoulos, Efstratios Kouskos, Helen Gogas, Vasiliki Kiriakou J. Metastatic retroperitoneal and mediastinal fibrosis as first sign of recurrence of breast cancer. *Euro J Surg.* 2001 Sep 1;167(9):715-8.
6. Park DS, Park JH, Lee YT. Percutaneous nephrostomy versus indwelling ureteral stents in patients with bilateral nongenitourinary malignant extrinsic obstruction. *J Endourol.* 2002 Apr 1;16(3):153-4.
7. Kuno K, Menzin A, Kauder HH, Sison C, Gal D. Prophylactic ureteral catheterization in gynecologic surgery. *Urol.* 1998 Dec 1;52(6):1004-8.
8. Borboroglu PG, Kane CJ. Current management of severely encrusted ureteral stents with a large associated stone burden. *J Urol.* 2000 Sep;164(3 Part 1):648-50.
9. Mohan-Pillai K, Keeley Jr FX, Moussa SA, Smith G, Tolley DA. Endourological management of severely encrusted ureteral stents. *J Endourol.* 1999 Jun;13(5):377-9.
10. El-Faqih SR, Shamsuddin AB, Chakrabarti A, Atassi R, Kardar AH, Osman MK, Husain I. Polyurethane internal ureteral stents in treatment of stone patients: morbidity related to indwelling times. *J Urol.* 1991 Dec;146(6):1487-91.
11. Zimskind PD, Fetter TR, Wilkerson JL. Clinical use of long-term indwelling silicone rubber ureteral splints inserted cystoscopically. *J Urol.* 1967 May;97(5):840-4.
12. Singh V, Srinivastava A, Kapoor R, Kumar A. Can the complicated forgotten indwelling ureteric stents be lethal?. *Inter Urol Nephrol.* 2005 Sep 1;37(3):541-6.
13. Bultitude MF, Tiptaft RC, Glass JM, Dasgupta P. Management of encrusted ureteral stents impacted in upper tract. *Urol.* 2003 Oct 1;62(4):622-6.
14. Tunney MM, Keane PF, Jones DS, Gorman SP. Comparative assessment of ureteral stent biomaterial encrustation. *Biomaterials.* 1996 Jan 1;17(15):1541-6.
15. Wollin TA, Tieszer C, Riddell JV, Denstedt JD, Reid G. Bacterial biofilm formation, encrustation, and antibiotic adsorption to ureteral stents indwelling in humans. *J Endourol.* 1998 Apr;12(2):101-11.
16. Kawahara T, Ito H, Terao H, Yoshida M, Matsuzaki J. Ureteral stent encrustation, incrustation, and coloring: morbidity related to indwelling times. *J Endourol.* 2012 Feb 1;26(2):178-82.
17. Okuda H, Yamanaka M, Kimura T, Takeyama M. Case of multiple encrusted stones on the ureteral stent left for 7 years: the efficacy of extracting the ureteral stent on transurethral lithotripsy. *Nihon Hinyokika Gakkai zasshi. Japan J Urol.* 2009 Sep;100(6):635-9.
18. Weedon JW, Coburn M, Link RE. The impact of proximal stone burden on the management of encrusted and retained ureteral stents. *J Urol.* 2011 Feb;185(2):542-7.
19. Vanderbrink BA, Rastinehad AR, Ost MC, Smith AD. Encrusted urinary stents: evaluation and endourologic management. *J Endourol.* 2008 May 1;22(5):905-12.
20. Lynch MF, Ghani KR, Frost I, Anson KM. Preventing the forgotten ureteral stent: implementation of a web-based stent registry with automatic recall application. *Urol.* 2007 Sep 1;70(3):423-6.
21. Sabharwal S, Macaden AR, Abrol N, Mukha RP, Kekre NS. A novel computer based stent registry to prevent retained stents: Will patient directed automated short message service and letter generator help?. *Ind J Urol: IJU: J Urol Soc India.* 2014 Apr;30(2):150-2.
22. Patil SM, Magdum PV, Shete JS, Nerli RB, Hiremath MB. Forgotten DJ stent-A source of morbidity: Is stent registry a need of the hour. *Int J Recent Sci Res.* 2015;6:2674-6.

**Cite this article as:** Ahmed MHS, Toshniwal H, Pawar PW, Sawant AS, Arora A, Abbas SA, et al. Feasibility of minimally invasive management in patients with forgotten double J stent: a single centre experience. *Int J Res Med Sci* 2020;8:37-41.