

## Case Report

# Functional outcome after total hip replacement following 30 years neglected posterior hip dislocation: a rare case report

Ivander Purvance\*, Wayan Suryanto Dusak, Gusti Ngurah Putra Stanu,  
Ni Made Puspa Dewi Astawa

Department of Orthopaedic and Traumatology, Sanglah General Hospital, Udayana University, Bali, Indonesia

**Received:** 15 December 2019

**Revised:** 30 January 2020

**Accepted:** 04 February 2020

### \*Correspondence:

Dr. Ivander Purvance,

E-mail: [ivander\\_purvance@hotmail.com](mailto:ivander_purvance@hotmail.com)

**Copyright:** © the author(s), publisher and licensee Medip Academy. This is an open-access article distributed under the terms of the Creative Commons Attribution Non-Commercial License, which permits unrestricted non-commercial use, distribution, and reproduction in any medium, provided the original work is properly cited.

### ABSTRACT

Neglected traumatic dislocations of the hip is one of disabling condition in lower extremity which are seldom found in adults. However, in developing countries, neglected-unreduced traumatic dislocations are not uncommon. Total hip replacement (THR) still remains a recommendation for the treatment of neglected hip dislocation which occurs more than 3 months. A 45- years-old female came to the outpatient clinic complaining pain on her right hip with history of trauma 30 years before, but instead of seeking medical treatment, she went to bonesetter instead. On physical examination, there is 5 cm leg length discrepancy, and the patient walked with limping gait. Conventional x-ray confirmed persistent dislocation of the right hip. A soft tissue release procedure and femoral neck osteotomy with skeletal traction was done before, followed by delayed THR two months after. The patient's functional status was improved, and the HHS score increased from 48 to 87. The patient had no pain or significant complaints, except for a finding of mild residual Trendelenburg gait.

**Keywords:** Hip dislocation, Neglected, Total hip replacement

### INTRODUCTION

Neglected traumatic dislocations of the hip are seldom found in adults. However, in developing countries, unreduced traumatic dislocations are not uncommon<sup>1</sup>. Traumatic dislocation of the hip usually results from high-energy and high velocity trauma such as in motor vehicle accidents or falls from great heights and often associated with multiple trauma including head injury, ipsilateral or bilateral femoral fractures, and other injuries which may detract attention from the dislocation.<sup>1,2</sup> Ideally, dislocated hips are treated as emergency in developed countries and delayed treatment often associated with many complications including degenerative arthritis, ankylosis, and sciatic nerve injury, and avascular necrosis of femoral head.<sup>3</sup>

Early detection and prompt treatment are mandatory for a good and satisfactory clinical outcome.<sup>4</sup> However, particularly in developing countries, the patients is often reluctant to look after appropriate medical care and they prefer to attend traditional healers instead. Traditional healers, such as bonesetters, still have some role in management of musculoskeletal disease, especially in rural and developing countries.<sup>5</sup> These conditions lead to delay in adequate treatment and increase of morbidity. The dislocated hip joint can be neglected for a quite long time and when happened, the management is difficult because of the soft tissues contractures, adhesions, fibrofatty tissue filling of the acetabulum, and presence of myositis ossificans.<sup>4</sup> There are some options of surgical procedure that can be considered in neglected dislocations of the hip and among them, total hip replacement (THR) procedure is recommended by some

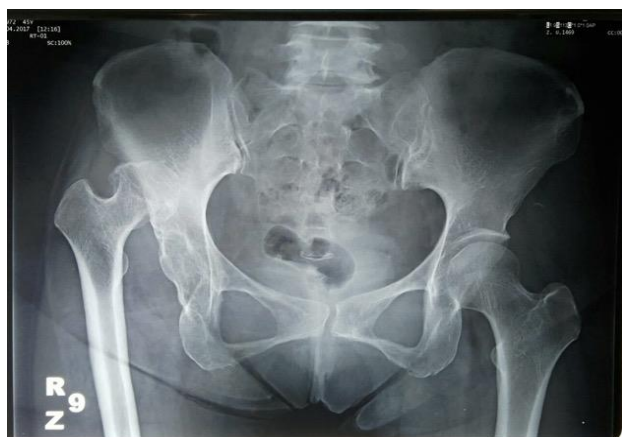authors.<sup>2,6</sup> A complete understanding about factors involved in the etiology of hip instability and a good knowledge about the treatment options are mandatory for the surgeon who takes care of this injury.

Authors presented a case of a 45 years old female complaining pain on her right hip since 3 months before the presentation with history of trauma 30 years before. Conventional x-ray confirmed persistent dislocation of the right hip. A soft tissue release procedure and femoral neck osteotomy with skeletal traction was done before, followed by delayed THR two months after. The patient's functional status was improved and the patient also had no pain or significant complaints, except for a finding of mild residual Trendelenburg gait.

### CASE REPORT

A 45-years-old female came to the outpatient clinic with chief complain of pain on her right hip since three months ago. Previously, patient had history of trauma 30 years ago due to motorcycle accident. During that time, she did not seek doctor/ medical care, instead she went to bonesetter to treat her condition. Several manipulations were done by the bonesetter and then, few months later, the patient was free from the pain, but she still walked in limping gait.

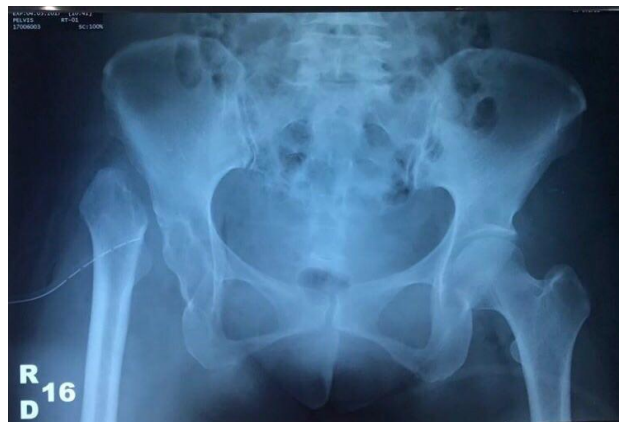Authors saw this patient 30 years after the initial injury, complaining of hip pain and limping gait. She was walking with antalgic gait and had a decreased range of motion of her right hip. She had a leg length discrepancy due to 5 cm shortening of right lower extremity. Her hip joint movements were restricted, but not painful. Radiographs confirmed a persistent dislocation of the right hip, with a pseudo-acetabulum in the right supra-acetabular region (Figure 1).



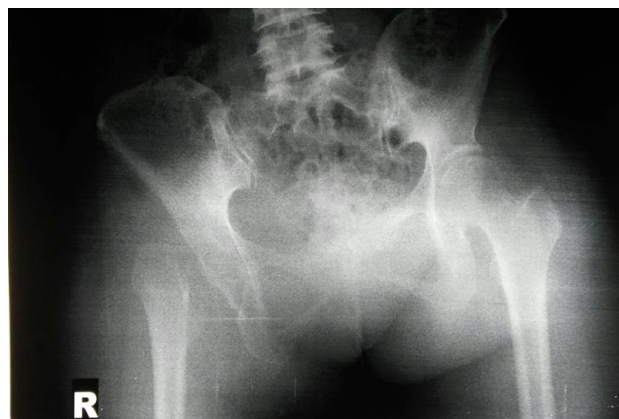
**Figure 1: Pre-operative x-ray of the pelvis, showing neglected right posterior hip dislocation.**

Initially, a soft tissue release procedure combined by femoral neck osteotomy and skeletal traction was done. The weight of the skeletal traction was increased gradually from 5 kg until 12 kg. The x-ray examination was performed at 8 kg skeletal traction (Figure 2). After

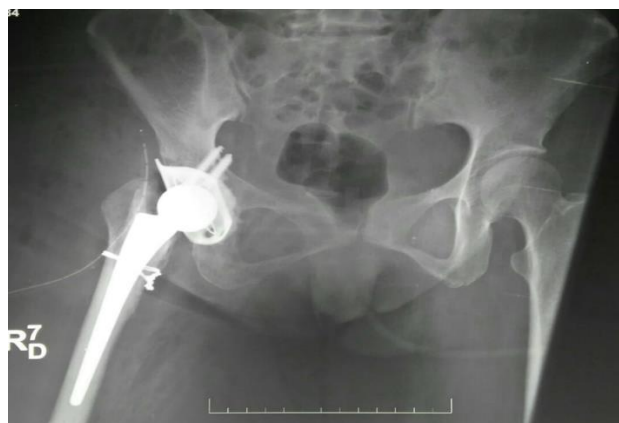one month of follow up, the second operation was done, which include further soft tissue release followed by skeletal traction. The weight of the skeletal traction was increased until 18 kg and the x-ray examination were performed (Figure 3).



**Figure 2: The x-ray of the pelvis after the first operation, showing post femoral neck osteotomy and skeletal traction with 8 kg load.**



**Figure 3: The x-ray of the pelvis after the second operation, showing post-further soft tissue release and skeletal traction with 17 kg load.**



**Figure 4: Post-operative pelvic X-Ray of the patient after total hip replacement.**

A delayed THR with a constrained acetabular insertion for stability was performed one month after the second operation. The leg length was equalized, and the postoperative recovery was uneventful. Pelvic x-ray showed satisfactory position and fitting of the prosthesis (Figure 4). Her physiotherapy was started soon postoperatively, and she was discharged on the 10<sup>th</sup> day after the last surgery. On every follow-up visitations, her functional status was improved and the HHS score increased from 48 to 87, indicating that the treatment was successful. She had no pain or significant complaints, except for a finding of mild residual Trendelenburg gait.

## DISCUSSION

Neglected dislocation of the hip is mainly precipitated by unwillingness or inability of the patients to look after appropriate medical care, especially in developing countries. Patients with dislocation of the hip is often reluctant to look after appropriate medical care and they prefer to attend traditional healers instead. This patient is a quite extreme case which the hip had been dislocated and neglected for 30 years. Traditional healers, such as bonesetters, still have some role in management of musculoskeletal disease, especially in rural and developing countries.<sup>5</sup> Aries et al, reported that patients who chose to attend to bonesetters for fracture treatment instead attend the hospital are influenced by severity of the fracture, availability of the service, their financial status and past experiences.<sup>5</sup> Beside that, the personal characteristic of the patients may also affect this condition, because neglected dislocation of the hip is usually found in patients with a high pain tolerance, patients with decreased cognitive ability to recognize or verbalize their pain, and patients with additional distracting injuries that are more obvious or life-threatening.<sup>1</sup>

The discussions for the best treatment option of neglected hip dislocation is still continuing and remains controversial. Among all of the procedure proposed, total hip replacement procedure is recommended by some authors for the treatment of neglected dislocation of the hip.<sup>2,6</sup> This procedure also remains a preferred option in case of neglected acetabular fractures with high risk of secondary post-traumatic arthritis.<sup>7</sup> In general, total hip replacement is a surgical procedure with a number of surgical approaches exist, each has unique advantages and disadvantages. The well-known approaches include the direct anterior, direct lateral, and posterior approach. A number of technical intricacies permit safe and efficient femoral and acetabular reconstruction when using each approach. The complication of THR includes hip dislocation, abductor insufficiency, fracture, and nerve injury, although their relative risk varies by approach.<sup>8</sup> And for unstable hips and recurrent dislocations, total hip replacement procedure with constrained acetabular component is a considerable option.<sup>9</sup>

In this report, the patient was treated by THR and preoperative traction. There are many studies and reports explaining about the recommendation of THR procedure for the management of neglected dislocation of the hip.

Patel et al, presented a case of 30 years-old male patient with neglected hip dislocation. The patient complained pain in the left hip for 2 years with fixed deformity of the hip, with history of fall from a tree 15 years ago. The radiographs showed an obturator dislocation of the hip with obvious pseudo-acetabulum around the dislocated femoral head. Uncemented total hip arthroplasty was performed and after 2 years follow up, the patient was able to walk unaided without pain.<sup>10</sup>

Ilyas et al, treated 15 patients with chronic unreduced hip fracture-dislocations result from motor vehicle injury at King Faisal Specialist Hospital & Research Center. All underwent 1-stage total hip arthroplasty with bone grafting and then monitored for 36-96 months range. Although there were 2 dislocations, 1 transient peroneal nerve palsy, and 1 superficial infection, but generally all patients had significantly decreased pain, increased function, and increased range-of-motion scores using the Merle d'Aubigné scoring system.<sup>2</sup>

Kumar et al, reported a 31 years old female patient with neglected hip dislocation. The initial injury was 2 years before the patient's presentation to hospital and had gone through many multiple treatments for her disease without any improvement. The patient was treated by constrained total hip replacement, resulting in improvement of Harris Hip Score from 48 to 81. On follow up, the patient showed improved range of motion of hip joint without pain.<sup>1</sup>

In case of preoperative traction, a retrospective study in Cambodia by Selimi et al, revealed that pre-operative traction seems to be an acceptable treatment in dislocation of the hip. In this study, there are 72 patients who presented to clinic with chronic hip dislocations. 42 of them received recorded treatment and 32 among them were followed up. 63% of the patients who undergo follow up experienced good outcomes after treatment. Open reductions which is the most common treatment, were successful 65% of the time. The use of preoperative traction increased the success of open reductions by 13%, however, this result was not statistically significant ( $p=0.64$ ).<sup>3</sup>

## CONCLUSION

Authors report a case of neglected dislocation of the hip treated by constrained total hip replacement (THR) and preoperative traction which improves the patient's functional status successfully.

*Funding: No funding sources*

*Conflict of interest: None declared*

*Ethical approval: Not required*

## REFERENCES

1. Kumar S, Dahuja A, Narula MS, Garg S, Kaur R. Neglected hip dislocation: an unusual presentation, its management and review of the literature. *Strat Trauma Limb Reconst.* 2017 Nov 1;12(3):189-92.

2. Ilyas I, Rabbani SA. Total hip arthroplasty in chronic unreduced hip fracture-dislocation. *J Arthropl.* 2009 Sep 1;24(6):903-8.
3. Selimi V, Heang O, Kim Y, Woelber E, Gollogly J. Chronic hip dislocations: a rarity. How should we treat them?. *J Orthop.* 2016 Dec 1;13(4):431-6.
4. Pugalenthil PV, Ramanathan S, Thanappan N, Sagar MV. A rare case of neglected unreduced posterior dislocation of hip managed with total hip arthroplasty-a case report. *J Evolut Med Dent Scie.* 2017 Mar 20;6(23):1953-7.
5. Ariës MJ, Joosten H, Wegdam HH, Van Der Geest S. Fracture treatment by bonesetters in central Ghana: patients explain their choices and experiences. *Tropi Medi Int Health.* 2007 Apr;12(4):564-74.
6. Sundaresh DC, Ramanath SK, Grover A, Gadi D. Uncemented total hip replacement after two years of neglected hip dislocation with fracture of posterior column and wall of the acetabulum. *Trauma Monthly.* 2016 Nov;21(5):e25301.
7. Avtar R, Khanna V, Kumar K. Neglected posterior acetabular wall fracture managed with uncemented total hip arthroplasty with posterior wall reconstruction by femoral head autograft: a case report. *Int J Res Orthop.* 2018;4(3):527-31.
8. Petis S, Howard JL, Lanting BL, Vasarhelyi EM. Surgical approach in primary total hip arthroplasty: anatomy, technique and clinical outcomes. *Canadian J Surg.* 2015 Apr;58(2):128.
9. Berend KR, Lombardi Jr AV, Mallory TH, Adams JB, Russell JH, Groseth KL. The long-term outcome of 755 consecutive constrained acetabular components in total hip arthroplasty: examining the successes and failures. *J Arthropl.* 2005 Oct 1;20:93-102.
10. Patel S, Thimmegowda RB, John R, Kumar TS, Arjun RH. Total hip arthroplasty in neglected, obturator type, hip dislocation in a young adult—an unusual case and literature review. *J Arthrosc Joint Surg.* 2017 Jan 1;4(1):50-3.

**Cite this article as:** Purvance I, Dusak WS, Stanu GNP, Astawa NMP. Functional outcome after total hip replacement following 30 years neglected posterior hip dislocation: a rare case report. *Int J Res Med Sci* 2020;8:1152-5.