

Case Report

Fatal pulmonary embolism after middle ear surgery: a case report

Khyati Ramesh Patel^{1*}, Varsha Vyas¹, Kaushal Patel², Misha Mehta¹

¹Department of Anaesthesiology, Dr. D. Y. Patil Hospital and Research Centre, Navi Mumbai, Maharashtra, India

²Department of Critical Care, P. D. Hinduja Hospital, Mumbai, Maharashtra, India

Received: 08 February 2020

Revised: 17 February 2020

Accepted: 29 February 2020

*Correspondence:

Dr. Khyati Ramesh Patel,

E-mail: khyatikalyan@gmail.com

Copyright: © the author(s), publisher and licensee Medip Academy. This is an open-access article distributed under the terms of the Creative Commons Attribution Non-Commercial License, which permits unrestricted non-commercial use, distribution, and reproduction in any medium, provided the original work is properly cited.

ABSTRACT

Pulmonary thromboembolism is a complication of underlying venous thrombosis. Factors contributing to thrombus formation include venous stasis, hypercoagulable state, immobilisation, surgery and pregnancy. Authors present the challenges authors faced in diagnosing pulmonary embolism in a post-operative patient. 35-year-old female with complaint of decreased hearing for 2 years along with tinnitus and giddiness was admitted for stapedectomy. She also gave history of dyspnoea and pedal oedema one month back for which she was hospitalized and underwent investigations which were normal. Patient was discharged as her clinical symptoms improved. On postoperative day 5, she developed sudden dyspnoea after getting up and walking a few steps. Dyspnoea along with falling saturation and bradycardia progressed to cardiopulmonary arrest. Intensive care was started. Bilateral lower limb venous doppler showed deep venous thrombosis. Clinical diagnosis of pulmonary embolism was made, and patient was lysed with Tenecteplase 30 mg. Echocardiography showed signs of resolution of embolism after lysis, but gradually patient deteriorated and developed cardiogenic shock. Intra-aortic balloon pump was inserted via right femoral artery and inotropic support was continued. However, patient's condition worsened, and she developed cardiopulmonary arrest the next day and could not be revived. Prevention of pulmonary embolism is a major clinical problem for which prophylactic measures like early ambulation in post-operative periods, elastic stockings, graduated compressive stockings for bed ridden patients and preventive anticoagulation therapy in high risk patients should be considered.

Keywords: DVT prophylaxis, Post-operative complication, Pulmonary embolism, Thrombolysis, Thromboembolism

INTRODUCTION

Pulmonary Thromboembolism (PTE) is a major health problem with significant mortality and morbidity. Pulmonary thromboembolism is a complication of underlying venous thrombosis. The clinical presentation of PE is variable and many patients, including those with large PE, are asymptomatic or have mild or nonspecific symptoms. Thus, it is critical that a high level of suspicion be maintained so that clinically relevant cases are not missed. Estimates of the incidence of Pulmonary Embolism (PE) in the general population have increased following the introduction of computed tomographic

pulmonary angiography in the 1990s.¹ The evaluation of patients with suspected PE should be efficient so that patients can be diagnosed, and therapy administered quickly to reduce the associated morbidity and mortality. Here authors present a case of a post-operative patient who was later diagnosed with pulmonary embolism and the challenges authors faced in managing this patient.

CASE REPORT

35-year-old female with complaint of decreased hearing since 2 years along with tinnitus and giddiness was admitted for stapedectomy. She also gave history of

bilateral pitting edema, cough and dyspnoea on exertion three months back for which she was hospitalized and was Investigated and evaluated. She had undergone investigations like CBC, RFT, LFT, chest x-ray, 2 decho which were normal. Patient was discharged as her clinical symptoms improved.

Preoperative workup was unremarkable, and patient was taken up for surgery under local anaesthesia with intravenous sedation. Perioperative period was uneventful, and patient was advised strict bed rest in wards. On postoperative day 5, she developed sudden dyspnoea after getting up and walking a few steps. On examination the patient was not responding to commands, and had pulse 120/minute, blood pressure of 110/60 mm Hg, respiratory rate 50/minute, Spo2 of 80% on room air. Dyspnoea along with falling saturation and bradycardia progressed to cardiopulmonary arrest. Cardiopulmonary resuscitation was started, and patient was shifted to intensive care unit. After securing airway, infusions of noradrenaline, dopamine and adrenaline were started via internal jugular vein. 2-dimensional echo revealed dilated right atrium and right ventricle with pulmonary artery systolic pressure of 68 mm of Hg and dilated non-collapsing inferior vena cava (Figure 1).

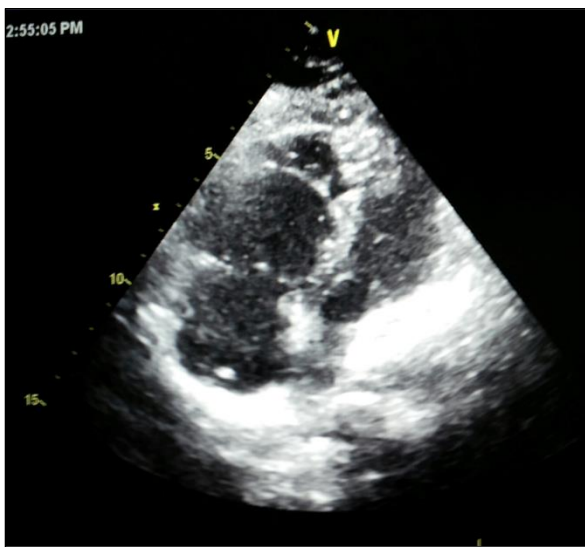


Figure 1: Two-dimensional echocardiography.

Bilateral lower limb venous Doppler showed deep venous thrombosis. Clinical diagnosis of pulmonary embolism was made, and patient was lysed with Tenecteplase 30 mg. 2-dimensional echo showed signs of resolution of embolism after lysis, but gradually patient deteriorated and developed cardiogenic shock.

Intra-aortic balloon pump was inserted via right femoral artery and inotropic support was continued. However, patient's condition worsened, and she developed cardiopulmonary arrest on 6th post-operative day and could not be revived.

DISCUSSION

A major theory delineating the pathogenesis of VTE, often called Virchow's triad proposes that VTE occurs as a result of alterations in blood flow (i.e. stasis), vascular endothelial injury, and alterations in the constituents of the blood. In a population-based study of the prevalence of VTE, 56% of the patients had three or more of the following six risk factors present at the time of VTE: >48 hours of immobility in the preceding month; hospital admission, surgery, malignancy, or infection in the past three months; or current hospitalization.

Pulmonary Embolus (PE) refers to obstruction of the pulmonary artery or one of its branches by material (e.g. thrombus, tumour, air, or fat) that originated elsewhere in the body.

The Well's Criteria risk stratifies patients for Pulmonary Embolism (PE), and has been validated in both inpatient and emergency department settings. Its score is often used in conjunction with d-dimer testing to evaluate for PE. Well's is not meant to diagnose PE but to guide workup by predicting pre-test probability of PE and appropriate testing to rule out the diagnosis.

Pulmonary Embolism (PE) has a wide variety of presenting features, ranging from no symptoms to shock or sudden death. The most common presenting symptom is dyspnoea. Other presenting symptoms include pleuritic pain, cough, Haemoptysis, Tachycardia (HR >100 bpm), elevated jugular venous pressure, a gallop rhythm at the left sternal edge, and an accentuated second heart sound, wheezing.³ Rarely patients present with shock.

Electrocardiography may show sinus tachycardia and atrial arrhythmias, non-specific ST changes, T wave inversion, right axis deviation, complete or incomplete right bundle branch block, the S1Q3T3 pattern (Figure 2), P-pulmonale.

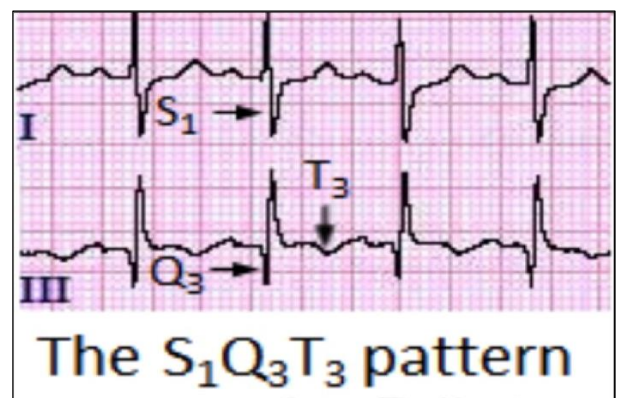


Figure 2: Electrocardiogram findings in pulmonary embolism.

Arterial blood gas analysis shows hypoxemia, respiratory alkalosis, and hypocapnea.

D-dimer and ELISA is a sensitive (96% to 98%) but very nonspecific test for PE. Brain Natriuretic Peptide (BNP) has sensitivity and specificity of 60% and 62%, respectively, in hemodynamically stable patients with acute PE.⁴⁻⁶

Chest x-ray is more useful to rule out alternative causes of hypoxemia and hypotension, such as pneumothorax, pleural effusion, pneumonia, atelectasis, aspiration, or heart failure. Cardiomegaly is most common finding on chest xray.^{7,8}

Confirmatory diagnostic tests include:

- Angiography: gold standard but expensive, invasive and not easily available.
- CT scan: preferred as it is non-invasive and readily available.
- Transesophageal echocardiography: has sensitivity of 80.5% and specificity of 97.2%.⁹
- Echocardiography is not reliable for diagnosing PE. It helps to detect RV enlargement and wall motion abnormality associated with PE. McConnell’s sign-hypokinesia of RV free wall with normal motion of RV apex is best known indirect sign of PE.^{10,11}
- V/Q scan: not very specific.

Aim of the therapy of PE is to restore patency of pulmonary artery and perfusion. Thrombolysis restores patency of occluded vessels both pulmonary as well as deep veins by dissolution of the clot which prevents exacerbation of pulmonary hypertension due to continued release of serotonin and other neurohumoral mediators. Currently, preferred fibrinolytic agent is recombinant tissue plasminogen activator which is indicated and approved by FDA in cases with massive PE. Other fibrinolytics are streptokinase, alteplase, and urokinase.

Massive Pulmonary Embolism treatment is started with Intravenous unfractionated heparin bolus of 80 units/kg followed by continuous infusion of 18 units/kg/hour with a target activated partial thromboplastin time (aPTT) between 1.5- and 2.5-times control.

Warfarin therapy is started after initial therapy with heparin. Heparin is continued for 4-5 days to overlap with warfarin therapy to counter paradoxical hypercoagulability that occurs with warfarin monotherapy.^{12,13} The novel OACs apixaban, edoxaban, rivaroxaban and dabigatran are also recommended.

2016 American College of Chest Physicians (ACCP) updated its guidelines on VTE treatment (Table 1).^{14,15}

Patients requiring extended treatment beyond 3 months can continue with their initial therapy choice (Table 2).^{14,15}

Other VTE treatments may include:

- Surgery
- Vena cava filters
- Catheter-guided thrombectomy or thrombolytic therapy

Mechanical methods of thromboprophylaxis that have been used in surgical patients include Intermittent Pneumatic Compression (IPC), Graduated Compression Stockings (GCS), and the Venous Foot Pump (VFP).¹⁶

Table 1: 2016 American college of chest physicians (ACCP) guidelines on VTE treatment.

Patients with DVT/PE	First 3 months of treatment
Without cancer	NOAC
With cancer	LMWH

Table 2: Recommendations for therapy duration for patients requiring extended treatment beyond 3 months.

Provoked VTE	3 months
Unprovoked VTE	Low-moderate bleeding risk: extended therapy
	High bleeding risk: stop treatment at 3 months
	Patients with cancer: extended therapy regardless of bleeding risk

Prevention of pulmonary embolism is a major clinical problem for which prophylactic measures like early ambulation in post-operative periods, elastic stockings, graduated compressive stockings for bed ridden patients and preventive anticoagulation therapy in high risk patients should be considered. All patients with established Venous Thromboembolic Disease (VTE), should have a thorough history and physical examination combined with routine laboratory testing and review of diagnostic imaging studies. This may provide clues to an inherited thrombophilia or reveal an acquired condition (e.g. surgery) predisposing to the thrombotic event. Every hospital should have an active strategy which should be in the form of a written institution-wide thromboprophylaxis policy endorsed by department heads and medical advisory boards.

Funding: No funding sources

Conflict of interest: None declared

Ethical approval: Not required

REFERENCES

1. Blann AD, Lip GY. Venous thromboembolism. BMJ. 2006 Jan 26;332(7535):215-9.
2. Spencer FA, Emery C, Lessard D, Anderson F, Emani S, Aragam J, et al. The Worcester Venous Thromboembolism study: a population-based study

- of the clinical epidemiology of venous thromboembolism. *J General Inter Med.* 2006 Jul;21(7):722-7.
3. Goldhaber SZ. Deep venous thrombosis and pulmonary embolism. In: Braunwald E, Kasper DL, Hauser SL, Jameson JL, Loscal Fanci AS, eds. *Harrison's Principles of Internal Medicine*, 17th ed. New York: McGraw Hill; 2008:1651-1657.
 4. Söhne M, ten Wolde M, Boomsma F, Reitsma JB, Douketis JD, Büller HR. Brain natriuretic peptide in hemodynamically stable acute pulmonary embolism. *J Thromb Haemos.* 2006 Mar;4(3):552-6.
 5. Ray P, Delerme S, Jourdain P, Chenevier-Gobeaux C. Differential diagnosis of acute dyspnea: the value of B natriuretic peptides in the emergency department. *QJM: Intern J Med.* 2008 Nov 1;101(11):831-43.
 6. Kucher N, Goldhaber SZ. Cardiac biomarkers for risk stratification of patients with acute pulmonary embolism. *Circulation.* 2003 Nov 4;108(18):2191-4.
 7. Stein PD, Terrin ML, Hales CA. Clinical, laboratory, roentgenographic and Electrocardiographic findings in patients with acute pulmonary embolism and no pre-existing cardiac or pulmonary disease. *Chest.* 1991;100:598-603.
 8. Elliott CG, Goldhaber SZ, Visani L, DeRosa M. Chest radiographs in acute pulmonary embolism: results from the International Cooperative Pulmonary Embolism Registry. *Chest.* 2000 Jul 1;118(1):33-8.
 9. Torbicki A, Pruszyński B, Chlebus M, Kuch-Wocial A, Gurba H, Pruszczyk P, et al. Noninvasive diagnosis of suspected severe pulmonary embolism: transesophageal echocardiography vs spiral CT. *Chest.* 1997 Sep 1;112(3):722-8.
 10. Lodato JA, Ward RP, Lang RM. Echocardiographic predictors of pulmonary embolism in patients referred for helical CT. *Echocardio.* 2008 Jul;25(6):584-90.
 11. Nazeyrollas P, Metz D, Chapoutot L, Chabert JP, Maillier B, Macs D, et al. Diagnostic accuracy of echocardiography-Doppler in acute pulmonary embolism. *Inter J Cardiol.* 1995 Jan 6;47(3):273-80.
 12. Kline JA, Hernandez-Nino J, Newgard CD, Cowles DN, Jackson RE, Courtney DM. Use of pulse oximetry to predict in-hospital complications in normotensive patients with pulmonary embolism. *Am J Med.* 2003 Aug 15;115(3):203-8.
 13. Anderson JT, Owings JT, Goodnight JE. Bedside noninvasive detection of acute pulmonary embolism in critically ill surgical patients. *Archi Surg.* 1999 Aug 1;134(8):869-75.
 14. Kearon C, Akl EA, Ornelas J, Blaivas A, Jimenez D, Bounameaux H, et al. Antithrombotic therapy for VTE disease: CHEST guideline and expert panel report. *Chest.* 2016 Feb 1;149(2):315-52.
 15. Kearon C, Akl EA, Comerota AJ, Prandoni P, Bounameaux H, Goldhaber SZ, et al. Antithrombotic therapy for VTE disease: antithrombotic therapy and prevention of thrombosis: American College of Chest Physicians evidence-based clinical practice guidelines. *Chest.* 2012 Feb 1;141(2):e419S-96S.
 16. Elpern E, Killeen K, Patel G, Senecal PA. The application of intermittent pneumatic compression devices for thromboprophylaxis. *AJN Am J Nursing.* 2013 Apr 1;113(4):30-6.

Cite this article as: Patel KR, Vyas V, Patel K, Mehta M. Fatal pulmonary embolism after middle ear surgery: a case report. *Int J Res Med Sci* 2020;8:1574-7.