

Original Research Article

Removal of locked intramedullary nails with the aid of bolts

Richard C. Echem*, Phillip D. Eyimina

Department of Orthopaedic Surgery, University of Port Harcourt Teaching Hospital, Port Harcourt, Rivers State, Nigeria

Received: 10 February 2020

Revised: 22 February 2020

Accepted: 02 March 2020

*Correspondence:

Dr. Richard C. Echem,

E-mail: richy1870@yahoo.co.uk

Copyright: © the author(s), publisher and licensee Medip Academy. This is an open-access article distributed under the terms of the Creative Commons Attribution Non-Commercial License, which permits unrestricted non-commercial use, distribution, and reproduction in any medium, provided the original work is properly cited.

ABSTRACT

Background: Removal of an intramedullary nail would require the extraction system of the inserted nail to be available. Sometimes the system is not available, and an alternative system would have to be utilised. Aim of the study was to document the removal of interlocked nails using bolts in the absence of appropriate fitting extraction system.

Methods: A prospective study of consecutive patients seen by the authors between September 2016 and September 2018 in private clinics in Port Harcourt where the authors were invited to remove intramedullary nails. Bolts fitted to the proximal tips of the nails were utilized. With the aid of plier applied to the bolts and mallet, the nails were extracted. The patients' socio-demographic and information relevant to the injury were obtained. Data was analysed using SPSS version 23.

Results: Fifteen patients were seen. Ages ranged from 29 to 72 years, consisting of 10 males and five females. The tibia was affected in six and the femur in nine. There were five united tibial fractures and one non-united tibial fracture, six united femoral fractures and three non-united femoral fractures. Indication for removal was mostly patients' request. Duration of surgery ranged from 1 to 4 hours. All the nails were extracted. Complications included broken nail, heterotopic calcification, bony overgrowth/ingrowth/ongrowth around the nail and interlocking screws. There was no mortality.

Conclusions: In the absence of conventional intramedullary nail extraction system, appropriate size bolts can be applied to the threaded proximal tip of nails and used for nail extraction.

Keywords: Bolt, Fracture, Intramedullary nails, Locked, Removal

INTRODUCTION

Intramedullary nailing of fractures has become the gold standard for the treatment of long bone fractures of the lower extremity.¹⁻⁵ It has been accepted as a safe and effective method to treat these fractures.^{2,6-10,11} Intramedullary nails act as internal load-sharing splints.^{1,12} Intramedullary nailing of long bone fractures has been shown to offer an ideal anatomical, functional and physiologic treatment for these fractures.¹³ Intramedullary nails have been mainly used for midshaft and transverse diaphyseal fractures. However, with the introduction of screws to interlock these nails, the

indications have broadened to include long oblique, spiral, comminuted fractures, segmental fractures or fractures that are located within the distal or proximal third of long bones and fractures with bone loss.^{2,3,13-15}

Interlocked intramedullary nailing offers greater advantage in fracture fixation.¹⁴⁻¹⁷ Implant removal is one of the commonly performed orthopedic procedures.⁹ Indications for removal of implants in the literature include symptomatic implants, skeletally immature patients, broken and/or failed implants, soft tissue compromise, nonunion, malunion, infection, fear of carcinogenesis, peri-implant failure, prevention of post

union stress shielding, prevention of future bacterial colonization, avoidance of difficult surgery due to the potential for refracture or implant failure and the possibility of improving functional outcome.^{8,9,18-20} After bony union, opinions differ on the need for removal of implants. While some favour routine removal, others do not.^{4,11,18,21} Patients' requests and symptomatic implants are typical indications for removal.

Removal of intramedullary nails require the availability of implant-specific threaded extraction bolts or similar instrumentation.^{6,19,22-24} Sometimes the appropriate extraction system may not be available, or the available extraction system may not fit. In these situations, an alternative system has to be utilized for the intramedullary nail extraction. The aim of this study is to document the removal of interlocked nails using bolts in the absence of appropriate fitting extraction system.

METHODS

This was a prospective study of consecutive patients seen by the authors between September 2016 and September 2018 in private clinics in Port Harcourt where the authors were invited to remove intramedullary nails.

The extraction system for an intramedullary nailing system was prepared for each extraction. However, the thread of the tip of the extraction system did not fit those of the nails. Appropriate sized bolts were then utilized. The proximal tip of the nail was exposed surgically after removing the locking screws. The appropriate sized bolt was then screwed to the proximal tip of the nail. The jaws of a plier were used to hold the proximal part of the bolt abutting on the cap. A mallet was then used to hammer the plier until the nail was extracted.

Inclusion criteria

- All the patients in whom the extraction system of the prepared intramedullary nailing system did not fit the proximal tip of the nail in the patients.

Exclusion criteria

- Excluded were those in whom the extraction system fitted.

Data obtained included their age, sex, diagnosis/location, affected side, mechanism of injury, indications for removal, duration before implant removal, number of previous surgeries/surgery type, duration of surgery, any blood transfusion, nail type (brand) and diameter/length of nail removed, presence of bony ingrowth/overgrowth, complications on the nails/screws, patient and surgeon at time of surgery, additional treat given and complications after treatment.

Data was analysed using IBM's Statistical Package for Social Sciences (SPSS) version 23 (IBM Inc., Armonk,

NY, USA). Mean, standard deviation and median where applicable were used for descriptive statistics while categorical variables were expressed as absolute frequencies.

Ethical approval was obtained from the Research and Ethics Committee of the University of Port Harcourt Teaching Hospital.

RESULTS

During the period, 15 patients were seen. Their ages ranged from 29 to 72 years with a mean of 43.27±12.84 years. There were 10 males and five females. The tibia was involved in six and the femur in nine patients. This consisted of five united tibial shaft fractures, one non-united tibial shaft fracture, six united femoral shaft fractures and three non-united femoral shaft fractures (Table 1). The left side was affected in seven (two tibial and five femoral) and the right in eight patients (four tibial and four femoral).

Majority of the injuries resulted from road traffic crashes (80.0%) while 20.0% were due to gunshots. The indication for intramedullary nail removal was mostly patients' requests (60.0%) (Table 1). The mean duration before implant removal was 3.48±1.74 years (range: 2-9 years). Majority of the patients (86.7%) had only the surgery for the nail insertion on the affected body part (Table 1). The mean duration of surgery was 2.03±0.96 hours (range: 1-4 hours). Only two patients had blood transfusion, and these were for non-united femoral shaft fractures.

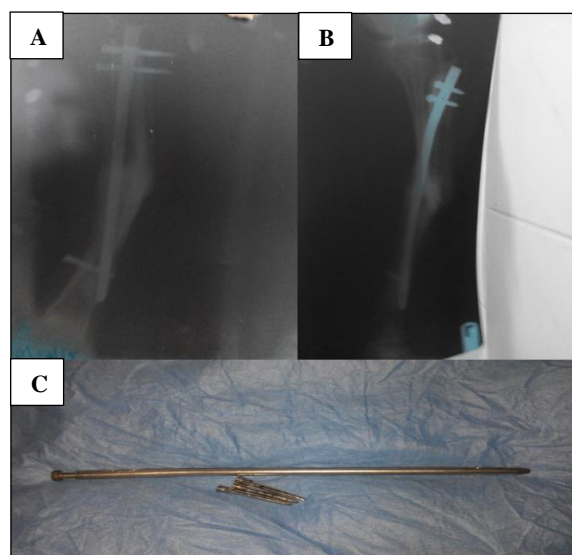


Figure 1: Plain radiographic views of united tibial fracture (1A and 1B) with intramedullary nail in situ. Removed SIGN nail with bolt in situ (1C).

The nail type/brand extracted was mainly SIGN (Surgical Implant Generation Network) (53.3%). For five extracted nails, the brand could not be identified (Table 1). The diameter/length of the extracted nail for the tibia ranged

from 8 x 280 (mm) to 9 x 300 (mm) while the femoral nails ranged from 10 x 380 (mm) to 12 x 400 (mm). Bony overgrowth/ingrowth were noticed in two patients and overgrowth over the interlocking screws in another two patients. The extraction bolt got broken also in one of these patients with bony overgrowth/ingrowth.

In this patient, the hook of a Kuntscher nail extractor was applied to the dynamic interlocking screw hole to complete the extraction process as a reasonable portion of the nail had already been extracted with the bolt. There was one broken nail. At the time of the surgery, one patient sustained

abrasion around the site through which the nail was inserted and this was as a result of hammering. One surgeon sustained finger abrasion from hammering.

All the nails were successfully extracted. Four patients had external fixation with a linear rail system to stabilize the fractured sites. No other complication was noticed in any of the patients after the nail extraction. There was no mortality. Figures 1-3 show the plain radiographs and extracted intramedullary nails with the bolts in situ. Figure 4 shows the extracted nail with bony ingrowth and on growth.

Table 1: Clinical characteristics of patients.

	Variable	Frequency (n=15)	Percentage (%)
Diagnosis/location	United left tibial shaft fracture	1	6.7
	United right tibial shaft fracture	4	26.7
	Nonunited left tibial shaft fracture + implant failure	1	6.7
	United right femoral shaft fracture	3	20.0
	Nonunited right femoral shaft fracture + shortening	1	6.7
	United left femoral shaft fracture	3	20.0
	Nonunited left femoral shaft fracture + implant failure	2	13.3
Indications for removal	Requested	9	60.0
	Nonunited fracture + implant failure	3	20.0
	Nonunited fracture	1	6.7
	Pain in the hip	1	6.7
	Pain in the proximal tibia	1	6.7
Previous surgery type on affected part	Nail insertion only	13	86.7
	Nail insertion + exchange nail	1	6.7
	Nail insertion + exchange nail + plate augmentation	1	6.7
Duration of surgery (hours)	≤ 2 hours	10	66.7
	>2 hours - 3 hours	3	20.0
	>3 Hours	2	13.3
	Mean±SD; median	2.03±0.96 hrs; 2 hrs	
	Range	1-4 hours	
Implant type make	SIGN nail	8	53.3
	Asco nail	2	13.3
	Non-identifiable	5	33.3
Presence of bony overgrowth/ingrowth/ongrowth	None	11	73.4
	Present on/around nail	2	13.3
	Present around interlocking screw	2	13.3
Complications on/around nail at time of surgery	None	11	73.4
	Bony overgrowth/ingrowth/ongrowth	2	13.3
	Heterotopic calcification	1	6.7
	Broken nail	1	6.7
	Broken extraction bolt	1	6.7
Complication on patient at time of surgery	None	14	93.3
	Abrasion around nail insertion point	1	6.7
Complication on surgeon at time of surgery	None	14	93.3
	Abrasion on surgeon's finger	1	6.7

Key: S.D = Standard Deviation; SIGN = Surgical Implant Generation Network

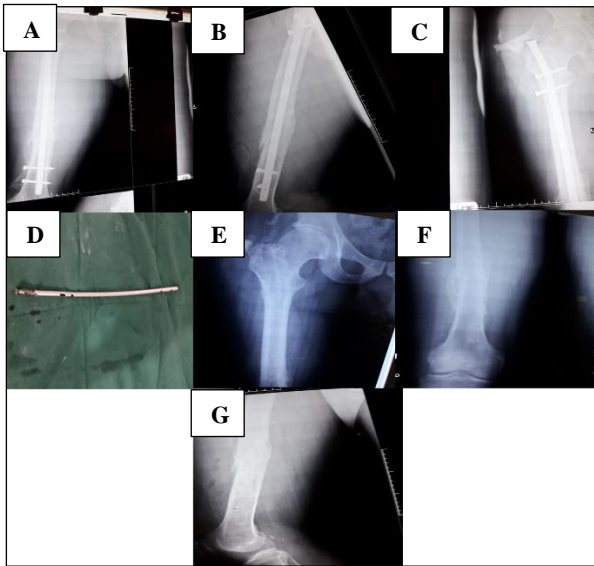


Figure 2: Plain radiographic views of united femoral fracture with intramedullary nail in situ (2A and 2B) showing heterotopic calcification and overgrowth at the proximal tip of the nail (2A and 2C). Removed intramedullary nail with bolt in situ (2D). Plain radiographs of the femur after nail removal (2E-2G).

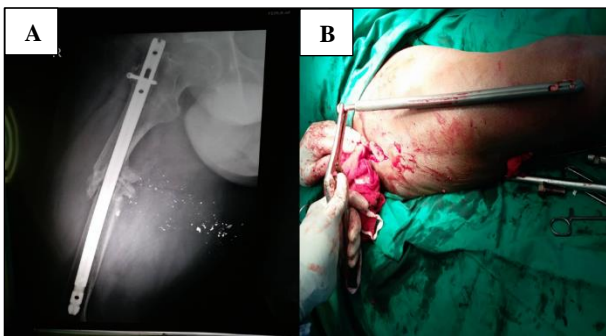


Figure 3: Plain radiograph of nonunited femoral fracture from gunshot injury with intramedullary nail in situ (3A). Removed intramedullary nail with bolt in situ (3B).

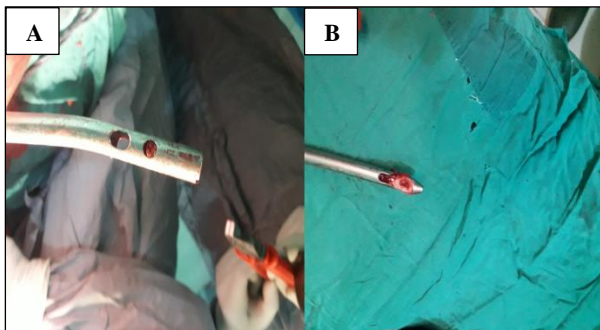


Figure 4: Intramedullary nail with bony ingrowth in the proximal locking hole (4A) and ingrowth in the distal locking hole and on growth in the distal part of the intramedullary nail (4B).

DISCUSSION

This study has shown that locked intramedullary nails could be extracted with appropriate size bolts, but this could be challenging and time-consuming, involve different nail brands with complications noticed on the nail, patients and even surgeons at the time of surgery.

With the acceptance of intramedullary nailing as the gold standard for the treatment of long bone fractures, there has been increased use of interlocked intramedullary nails to treat these fractures.¹⁻⁵ In developed countries, standard nails such as Grosse-Kempf, AO, ACE, Stryker, Smith and Nephew nails etc. are available for use with their extraction devices.^{3,5,8,10,14} Their use has been facilitated by the availability of image intensifiers. In developing countries where image intensifiers are not as readily available, external jig-aided interlocking systems have been developed by the Surgical Implant Generation Network (SIGN) and made available to a number of developing countries.^{12,25,26} These intramedullary nails have their standard extraction devices. Universal conical extraction devices have also been developed.^{22,23} In developing countries, the standard nails have also been utilized in facilities with image intensifiers.

Ideally, the extraction of inserted intramedullary nail requires implant-specific threaded extraction bolt that is attached to a bar with a slotted or sliding mallet.^{6,19,22-24} However, with the proliferation of intramedullary nail manufacturers in some developing countries, a variety of intramedullary nail brands find their way to other developing nations.¹⁹ These manufacturers have their own set of instruments and extraction devices without any universal code of the size of the conical screw and pitch of the threads.¹⁹ Sometimes the manufacturers may have disappeared from the market with their extraction instrumentation by the time the patients would be requiring nail removal.²⁹ At other times, the patients may have little or no information about the manufacturers of the intramedullary nail used for them.¹⁹ The names of the nails may not even be indicated on the nails. The intramedullary nail could be inserted by one surgeon but may have to be removed by a different surgeon who may have little or no information about the inserted nail or may not even have the extraction system of the inserted nail. These situations pose problems in the event that intramedullary nail removal is indicated.

In circumstances when “non-standard” nails had been used, even when standard extraction devices are available, they may not fit those of the inserted nails. Hence, there will be a need to improvise with commercial bolts with cap if nail removal is indicated. Different sizes of these bolts could be put together, with the one which appropriately fits the proximal tip threads of the inserted intramedullary nail being utilized. With the aid of the jaws of a plier applied to the proximal part of the bolt abutting on the cap, the nail is hammered out and extracted. This is the method utilized in the present study.

Mittal et al, had developed a universal interlocking nail (UNILEX) system composed of various sizes (7 mm to 13 mm) of six inches bolts, eight inches long ordinary heavy duty pliers with extended handles and two pound ordinary hammer.¹⁹ This is a low-cost system. These are useful in situations where standard extraction or universal extraction devices are not available or do not fit the inserted nail to be extracted. Bhat et al, have utilized long threaded rods used for Ilizarov fixator frames to insert into the proximal tip of the nails and with the aid of pliers and mallet, the nail is hammered out.¹⁵ The use of pliers and mallet in a sideways fashion as in these situations is less mechanically advantageous than the sliding or slotted hammer mechanism. This is because in the sliding or slotted hammer mechanism, the line of force application is directly in line with the nail axis rather than at an angle as occurs when the plier and mallet are used in a sideways fashion.²⁷

The extraction of inserted intramedullary nails could be difficult, challenging and time-consuming.^{6,22,27-29} In some instances the surgeon may not be able to extract the intramedullary nail and would have to abandon the procedure.^{8,10,11,27} In the present series, the nail extraction time ranged from one to four hours with a mean of 2.03±0.96 hours. Seyhan et al, in their series on tibial nail extraction reported a range of 45-120 minutes with a mean of 61.4±24.8 minutes for stainless steel nails and 55-130 minutes with a mean of 77.3±29.1 minutes for titanium nails.⁷ It had been highlighted that the difficulty of this procedure had been underestimated sometimes and the procedure even relegated to younger surgeons.⁶ Sometimes the procedure is difficult and challenging for the experienced orthopaedic surgeons.⁶ Hence the nail extraction procedure should not be taken lightly.

Different brands of intramedullary nails including standard nails are now available in developing countries. In the present series, most of the nails extracted were SIGN nails. The SIGN interlocking nails which can be utilized without image intensifiers have been made available to several developing countries.^{12,25,26} Similar interlocking nails which can be utilized without image intensifiers are also available. Five of the nails in the present series could not be identified as the brand names were not indicated on the nails. Sometimes as had been stated earlier, the manufacturers of these nails may have disappeared from the market with their extraction instruments. The inserted SIGN nails and similar nails may have to be removed in places where the SIGN extraction system or those of other manufacturers are not available. In these situations, the commercial bolts as utilized in the present series would be handy. Due to the challenge of lack of uniformity in the conical screw size, there is need to have universal codes for the size and pitch of the proximal tip threads of intramedullary nails. These will aid manufacturing of the extraction bolts such that the nails could be extracted in places other than the where the original insertions were carried out.

Complications could be noticed in the course of extraction of intramedullary nails. These could be on the nail, the patient and even the surgeon. In the present series, bony overgrowth/ingrowth/on growth and heterotopic calcifications were noticed as well as overgrowth over the interlocking screws. These have been reported by other workers.^{8,27,29-31} In growth of bone into the nail, through the interlocking holes especially if they are left open and growth over and on the nail can occur especially when the intramedullary nail has been in place for many years.^{8,29,30} While a membranous interface between the nail and bone has been demonstrated on some occasions, the bony growth has also been noticed in some instances to be solidly adhered to the nail surface.²⁷ The ingrowth, on growth and overgrowth pose challenge in extraction and make it difficult and time-consuming and sometimes impossible to extract. These difficulties in extraction have necessitated partial or entire osteotomy of the affected bone opening a window to enable separation of the nail from the bone in order to facilitate extraction.^{27,30} Some have introduced guide wire into cannulated nails to breakdown bony islands within the nail, while others redrilled/overdrilled the multiple locking holes to break down bony islands to facilitate nail removal.^{29,31}

Some workers have highlighted broken extraction bolts in the course of nail removal.^{6,22} In the present series, authors encountered a broken extraction bolt in one patient. In such instances, an alternate method of extraction would be needed. Georgiadis et al, have utilized high speed drill with a carbide metal cutting bit to create a slot in the proximal end of the nail to allow for the attachment of a hook for subsequent nail removal when a proximal extraction device fails.²⁸ In this case, part of the proximal aspect of the nail had been extracted with the exposure of the dynamic and static locking holes. The hook of a Kuntscher nail extractor was utilized to complete the nail extraction.

In the present study, authors encountered skin abrasion from hammering at the site of insertion/entry in one of the patients. The surgeon's fingers are at risk of being injured from hammering when a plier and mallet are used as occurred in this study. This is more likely when the pliers are small, and the extraction is difficult as a result of bony ingrowth/overgrowth. These complications on the patient and surgeon are less likely when implant-specific extraction system with a sliding or slotted hammering mechanism is being utilized. Where commercial bolts are utilized, long bolts and long pliers which give clearance from the patient's body and the surgeon's fingers are likely to reduce the occurrence of these. The low-cost system advocated by Mittal et al, use long bolts and long pliers.¹⁹

No complications related to the nail removal were noticed on the patients in the present study. Various complications reported by others after intramedullary nail removal include iatrogenic fracture, refracture,

neurovascular injury, haematoma, infection and implant breakage.^{7,8,18,29,32}

A limitation of the present study is the small number of patients (sample size) in the study. Also, the fact that different intramedullary nail brands were extracted could be a limitation as there was no uniformity.

CONCLUSION

In the absence of conventional implant-specific intramedullary nail extraction system, appropriate size bolts can be applied to the proximal threaded tips of the nails and used for the nail extraction. This additionally requires the use of pliers and mallet. This method will be useful in resource-limited environment.

ACKNOWLEDGEMENTS

The authors acknowledge the assistance of Anderson Ikeokwu in the data analysis.

Funding: No funding sources

Conflict of interest: None declared

Ethical approval: The study was approved by the Institutional Ethics Committee of the University of Port Harcourt Teaching Hospital

REFERENCES

- Bong MR, Koval KJ, Egol KA. The history of intramedullary nailing. Bull NYU Hosp Jt Dis. 2006;64(3-4):94-7.
- Wood GW. Intramedullary nailing of femoral and tibial shaft fractures. J Orthop Sci. 2006;11(6):657-69.
- Franklin JL, Winquist RA, Benirschke SK, Hansen ST Jr. Broken intramedullary nails. J Bone Joint Surg Am. 1988;70(10):1463-71.
- Hui C, Jorgensen I, Buckley R, Fick G. Incidence of intramedullary nail removal after femoral shaft fracture healing. Can J Surg. 2007;50(1):13-8.
- Bombaci H, Gorgec M. Difficulty in removal of a femoral intramedullary: the geometry of the distal end of the nail. Yonsei Med J. 2003;44(6):1083-6.
- Liதாகis E, Krettek C, Kenaway M, Hankemeier S. A new technique for removal of an incarcerated expandable femoral nail. Clin Orthop Relat Res. 2010;468(5):1405-9.
- Seyhan M, Guler O, Mahirogullari M, Donmez F, Gereli A, Mutlu S. Complications during removal of stainless steel versus titanium nails used for intramedullary nailing of diaphyseal fractures of the tibia. Ann Med Surg. 2018;26:38-42.
- Stenroos A, Brinck T, Handolin L. Recommendation of use of checklists in tibial intramedullary nail removal: Retrospective study of mechanical complications related to nail removal. Injury. 2018 Jul 1;49(7):1341-7.
- Sidky A, Buckley RE. Hardware removal after tibial fracture has healed. Can J Surg. 2008;51(4):263-8.
- Im GI, Lee KB. Difficulties in removing ACE tibial intramedullary nail. Int Orthop. 2003;27(6):355-8.
- Karladani AH, Ericsson PA, Granhed H, Karlsson L, Nyberg P. Tibial intramedullary nails- should they be removed? A retrospective study of 71 patients. Acta Orthop. 2007;78(5):668-71.
- Ikpeme I, Ngim N, Udosen A, Onuba O, Enembe O, Bello S. External jig-aided intramedullary interlocking nailing of diaphyseal fractures: experience from a tropical developing centre. Int Orthop. 2011;35(1):107-11.
- Winquist RA, Hansen ST, Clawson DK. Closed intramedullary nailing of femoral fractures. A report of five hundred and twenty cases. J Bone Joint Surg Am. 1984;66(4):529-39.
- Kempf I, Grosse A, Beck G. Closed locked intramedullary nailing. Its application to comminuted fractures of the femur. J Bone Joint Surg Am. 1985;67(5):709-20.
- Bhat AK, Rao SK, Bhaskaranand K. Mechanical failure in intramedullary interlocking nails. J Orthop Surg. 2006;14(2):138-41.
- Ogbemudia AO, Bafor A, Igbinovia E, Ogbemudia PE. Open interlocked nailing without a targeting device or x-ray guidance for non-union of the femur: a case series. Strategies Trauma Limb Reconstr. 2010;5(3):121-5.
- Kritsaneephaiboon A, Tangtrakulwanich B, Maliwankul K. A novel minimally invasive technique for removal of a bent femoral intramedullary nail. Injury Extra. 2012;43:157-62.
- Richards RH, Palmer JD, Clarke NM. Observations on removal of metal implants. Injury. 1992;23(1):25-8.
- Mittal RL, Gupta R, Bither N, Masih GD, Jindal A. A new low-cost universal nail extractor (Unilex system). Punjab J Orthop. 2012;13(1):22-4.
- Hasseb M, Butt MF, Altaf T, Muzaffar K, Gupta A, Jallu A. Indications of implant removal: A study of 83 cases. Int J Health Sci. 2017;11(1):1-7.
- Vos DI, Verhofstad MH. Indications for implant removal after fracture healing: a review of the literature. Eur J Trauma Emerg Surg. 2013;39(4):327-37.
- Weinrauch PC, Blakemore M. Extraction of intramedullary nails by proximal stacked wire technique. J Orthop Trauma. 2007;21(9):663-4.
- Wood GW. Safe, rapid, and effortless femoral nail removal using a new third-generation universal femoral nail extraction tool. J Orthop Sci. 2006;11(6):626-7.
- Lovell J, Krishna D, Gehr E. Stuffing the nail: A simple technique for extraction of a broken femoral nail. Trauma Case Rep. 2017;9:38-41.
- Ikem IC, Ogunlusi JD, Ine HR. Achieving interlocking nails without using an image intensifier. Int Orthop. 2007;31(4):487-90.
- Sekimpi P, Okike K, Zirkle L, Jawa A. Femoral fracture fixation in developing countries: an evaluation of the Surgical Implant Generation

- Network (SIGN) intramedullary nail. *J Bone Joint Surg Am.* 2011;93(19):1811-8.
27. Lindeque BG, Agudelo J. Incarcerated tibial nail. *Orthopedics.* 2009;32(2):126.
 28. Georgiadis GM, Heck BE, Ebraheim NA. Technique for removal of intramedullary nails when there is failure of the proximal extraction device: a report of three cases. *J Orthop Trauma.* 1997;11(2):130-2.
 29. Jeong E, Nathwani D. A simple tip for removal of a 'stubborn' tibial nail. *Injury Extra.* 2014;45:13-4.
 30. Marí R, Vilamala DV, García AL, Guirro P, López FM. A technical note for extracting an incarcerated femoral Kuntscher nail. *J Orthop Case Rep.* 2016 Jul;6(3):10.
 31. Seibert FJ, Puchwein P, Hartwagner W, Gumpert R, Karin T. Technique tip for the removal of a "non-removable" tibial nail (Expert Tibial Nail). *Injury Extra.* 2010;41:47-9.
 32. Takakuwa M, Funakoshi M, Ishizaki K, Aono T, Hamaguchi H. Fracture on removal of the ACE tibial nail. *J Bone Joint Surg Br.* 1997;79(3):444-5.

Cite this article as: Echem RC, Eyimina PD. Removal of locked intramedullary nails with the aid of bolts. *Int J Res Med Sci* 2020;8:1397-403.