

Original Research Article

Safety and efficacy of glued intraocular lens implantation in eyes with inadequate capsular support

Payal P. Gonde^{1*}, Sagar Aghadate²

¹Department of Ophthalmology, Seth GS Medical College and KEM Hospital, Mumbai, Maharashtra, India

²Department of Ophthalmology, JJ Hospital, Mumbai, Maharashtra, India

Received: 14 February 2020

Revised: 26 February 2020

Accepted: 06 March 2020

***Correspondence:**

Dr. Payal P. Gonde,

E-mail: payalgonde@gmail.com

Copyright: © the author(s), publisher and licensee Medip Academy. This is an open-access article distributed under the terms of the Creative Commons Attribution Non-Commercial License, which permits unrestricted non-commercial use, distribution, and reproduction in any medium, provided the original work is properly cited.

ABSTRACT

Background: Aim of the study was to analyze the postoperative visual outcomes, complication rate of fibrin glue-assisted, suture-less posterior chamber (PC) intraocular lens (IOL) implantation technique in eyes with inadequate capsule support at a tertiary eye care hospital.

Methods: This is a retrospective, nonrandomized case series. This study analyzes 50 eyes which underwent PC-IOL implantation by fibrin glue-assisted, suture-less technique. All patients who had IOL implants by the fibrin glue-assisted PC-IOL technique from 2017 to 2019 were included in the study. Intra- and post-operative complications were analyzed. The postoperative best corrected visual acuity (BCVA) was evaluated and recorded at the end of 6 months.

Results: Mean age of distribution are 42.94 years in glued IOL implantation. Among 50 cases 30 are males and 20 are females. There is significant difference in BCVA between preoperatively and postoperatively, p value for pre-operative to post-operative vision in glued intraocular lens group is <0.0001 i.e. there is definite improvement in vision in glued intraocular group. BCVA \geq 6/24 was 18 (48%) in Glued IOL subjects.

Conclusions: Glued IOL implantation is a feasible option in rehabilitating patients with aphakia without adequate capsular support.

Keywords: Best corrected visual acuity, Fibrin glue, Intraocular lens, Implantation/glued intraocular lens, Intraocular pressure, Posterior chamber, Pars Plana vitrectomy Scleral fixated Intraocular lens

INTRODUCTION

Aphakia is commonly the result of complications arising from cataract surgery. The most common risk factors of intraoperative complication are weakness of zonular fibers mostly due to PEX or trauma. Intraocular lens implantation (IOL) in the eyes that lack posterior capsular support is a problem for cataract surgeons for a long time. It is not only due to the visual outcome but also due to the related complications they face in the postoperative period.¹

Glued IOL is suture less, fibrin glue assisted PCIOL implantation with intra scleral tunnel fixation was first performed on December 14th, 2007 by Amar Agrawal in Chennai. A quick acting surgical fibrin sealant derived from human blood plasma, which has both hemostatic and adhesive properties, is used to seal scleral flaps. Glue assisted intra scleral fixation differs from other sutureless techniques in way that two partial scleral thickness flaps are made 180 degrees apart and scleral pockets are made at edge of flap base parallel to sclerotomy wound. The haptics are tucked in scleral pockets and the flaps are then

adhered to base with the help of tissue fibrin glue. The glue also helps in sealing sclerotomy site which would otherwise act as filtration site and cause hypotony. It is fast procedure. No specially designed IOL is needed. Fibrin glue to implant a posterior chamber intraocular lens (PCIOL) in eyes with a deficient or absent posterior capsule was introduced. Fibrin glue has two components that occur naturally in the blood namely fibrinogen and thrombin. They were separated before use, when mixed, thrombin converts fibrinogen to fibrin producing local fibrin clot.²⁻⁴

Advantage of glued intraocular lens⁵

- Absence of suture-related complications like suture erosion, suture knot exposure or dislocation of intraocular lens after broken suture.
- Ability to fix the IOL in aphakic eyes as well as under any complex situations such as subluxated cataract, dislocated IOL, AC-IOL with corneal decompensation and post vitrectomy.
- In this technique, PC-IOL was fixated without suture to the sclera by inserting the haptics into the sclera pockets. The sclera and conjunctival flaps were sealed with the fibrin glue eliminating the need for sutures and no special instrumentation was required.
- When eyes move, it acquires kinetic energy from its muscle and its attachment and energy is dissipated to internal fluids as it stops. Thus, pseudophacodonesis is result of oscillations of fluids in anterior and posterior segment of eye. These oscillations initiated by movements of eye results in shearing forces on corneal endothelium as well as vitreous motion leading to permanent damage. Although complete scleral wound healing with collagen fibrils may take up to 3 months. Since the haptic is snugly placed inside a scleral pocket, the IOL remains stable. There are no clinical pseudophacodonesis observed in glued IOL's due to good stability of the IOL.
- The use of Foldable Glued IOLs makes it possible to perform the entire procedure through small self-sealing incisions. This has the intraoperative advantage of having a well-formed globe throughout the surgery. It eliminates iris prolapse during IOL insertion and wound suturing.
- Handshake technique helps in early learning curve for easy haptic externalization which is a modification of our earlier procedure especially for foldable IOL.
- It prevents surgically induced iris trauma and iris ovalisation.

Aims and objectives

- To determine Visual outcome after surgery
- To restore Pseudophakia in complicated cases where either the posterior capsule is deficient or inadequate to support an intraocular lens.

- To Prevent suture related complication like suture erosion, suture knot exposure or dislocation of intraocular lens after broken suture.
- To prevent Surgically induced astigmatism due to aphakia.

METHODS

This study is a retrospective, nonrandomized case analysis of patients who underwent glued IOL implantation from 2017 to 2019. Case records of all patients who underwent glued IOL implantation were analyzed. The mean follow-up period for patients was 2 years.

The study was approved by the Institutional Ethics Committee consisting of a nine-member team. All patients included in the study had undergone a complete ophthalmic evaluation, which included detailed history, preoperative visual acuity, intraocular pressure (IOP), keratometry, slit lamp, and fundus evaluation. IOL power was calculated by keratometry and A-scan under aphakic mode.

Inclusion criteria

- Aphakia due to trauma, complicated cataract surgery, Lens /IOL subluxation, integrity of iris.
- Normal Intraocular pressure
- Anterior chamber depth >3.2 mm
- Normal Retinal examination
- Inability/Intolerance/Unwilling for aphakic spectacles/contact lens.

Exclusion criteria

- Uncontrolled Glaucoma
- Any pathology of retina
- Active, chronic or recurrent Uveitis
- Severe Anterior segment structural abnormalities
- Inability to follow up

Preoperative preparation

- Mydriasis was achieved by using a combination of eyedrop tropicamide (0.8%) and phenylephrine (5%) every ten minutes one hour before surgery.
- Anaesthesia - Peribulbar block was given at the junction of outer one third and inner two thirds of the lower orbital rim. The needle was directed away from the eye and towards the floor of the orbit with eye in primary gaze. In the superior orbital margin injection was given at the junction of medial one- third and lateral two third towards the roof of the orbit. When orbicularis oculi function remains active seventh cranial nerve akinesia was achieved by O'Brien akinesia technique with 2ml of 2%lidocaine with 1:200000 adrenaline with hyaluronidase.
- Cleaning and Drapping: -Preparation included use of 5% povidone iodine to clean the surrounding skin. Skin area that extended from midline to

beyond lateral can thus and from above the eyebrows to well down onto the cheek was cleaned. 5% iodine solution was applied into conjunctival cul de sac with subsequent saline wash to cleanse the conjunctiva.

- Draping the Surgical field: The eye and surrounding sterile periocular region was draped with a sterile cloth with a 3cm × 3cm round opening for the eye. Lid speculum was applied.

Glued Intraocular lens implantation technique (Figure 1).⁶

- Under peribulbar anesthesia, localized peritomy at the site of exit of the IOL haptics is one. Infusion cannula or anterior chamber (AC) maintainer is inserted. Positioning of the infusion cannula should be in the pars plana about 3 mm from the limbus. Anterior segment surgeons can use an Anterior Chamber maintainer or 23G trocar cannula infusion.
- Two partial thickness limbal based scleral flaps about 2.5 mm × 2.5 mm are created exactly 180° diagonally (use RK marker & pen) apart and about 1-1.5 mm from the limbus.
- This is followed by vitrectomy via pars plana or anterior route to remove all vitreous traction.
- Two straight sclerotomies with a 20G needle are made about 1 mm from the limbus under the existing scleral flaps.
- A corneo-scleral tunnel incision is then prepared for introducing the IOL in the case of PMMA non-foldable IOL or corneal incision with keratome in the case of injectable three piece foldable IOL.
- While the IOL is being introduced with one hand, an end gripping 23G micro rhexis forceps (Micro Surgical Technology, USA) is passed through the opposite sclerotomy with the other hand. The tip of the leading haptic is then grasped with the micro rhexis forceps, pulled through the sclerotomy following the curve of the haptic and is externalized under the scleral flap. Similarly, the trailing haptic is also externalized through the other sclerotomy under the scleral flap.
- The haptic tips are tucked into the intralamellar scleral tunnel made with a 26G needle at the point of externalization of the haptics on either side.
- Then, the reconstituted fibrin glue prepared is injected through the cannula of the syringe delivery system under the scleral flaps.
- Local pressure is given over the flaps for about 10-20 s for the formation of fibrin polypeptides.
- Corneo scleral wound is closed with 10-0 monofilament nylon in PMMA IOL and in the case of foldable IOL corneal incision is closed with fibrin glue.
- The anterior chamber maintainer or the infusion cannula is removed. Conjunctiva is closed with the fibrin glue in all eyes irrespective of the type of IOL.

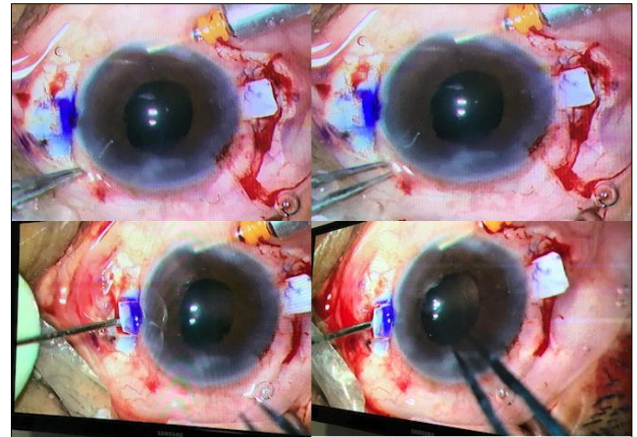


Figure 1: Steps of glued intraocular lens implantation.

Statistical analysis

Data were statistically described in terms of mean (\pm SD), frequencies (number of cases) and percentages when appropriate. Data were tested first for normal distribution by Kolmogorov–Smirnov test. Comparison of quantitative variables between the study was done using Student t test for independent samples if normally distributed.

Mann-Whitney U test was used for non-normally distributed quantitative data. Fisher test was performed. Exact test was used instead when the expected frequency is less than 5. A probability value (p value) less than 0.05 was considered statistically significant. All statistical calculations were done using computer programs Microsoft Excel 2015 (Microsoft Corporation, NY, USA) and SPSS (Statistical Package for the Social Science; SPSS Inc., Chicago, IL, USA) version.

Postoperative care

- Eye pad will be removed next day morning. Eye drops will be administered.
- All patients will receive eyedrop Atropine (1%) two times daily, Prednisolone (1%) eight times daily initially tapering during 1 month, Moxifloxacin (0.5%) eight times daily and Lubricating eyedrop 1% daily for one month.
- Follow-up: 1st week, 2nd week, 1st month and then monthly till 6 months.
- Urine follow-up of patients, visual acuity will be checked.
- Slit lamp examination will be done to look for status of cornea, anterior chamber, iris, position of IOL.
- Fundus examination will be done using indirect ophthalmoscopy. Applanation tonometry will be done.
- Auto refraction will be done.
- Patients with raised intraocular pressure will be managed medically. Wound sutures will be removed after 8 weeks. Refraction will be done 2 weeks after suture removal.

RESULTS

The current study was conducted at a tertiary care hospital in a metropolitan city. This study was done to study visual outcome of Glued Intraocular lens Implantation to correct Aphakia. A total of 50 patients were enrolled in this study. The findings of this study presented as results are discussed in detail with the findings of the relevant studies.

Table 1: Age wise distribution of study participants.

Age (year)	Glued scleral fixated IOL	%
≤15	9	18
16-30	11	22
31-45	4	8
46-60	11	22
>60	15	30

Table 1 showing 50 patients were divided in age groups of <15 years, 16-30 years, 31-45 years, 46-60 years and >60 years in-

- 9(18%) patients were from age group ≤15 years in glued Intraocular implantation group
- 11(22%) patients were from age group 16-30 years in glued Intraocular implantation group.
- 4(8%) patients were from age group 31-45 years in glued Intraocular implantation group.
- 11(22%) patients were from age group 46-60 years in glued Intraocular implantation group.
- 15(30%) patients were from age group >60 years in glued Intraocular implantation group.

Table 2: Average age.

Group	Average age (yr)	p value
Glued scleral fixated IOL	42.94±24.22	0.14

Mann Whitney test

Table 2 showing mean age of distribution is 42.94 yrs in glued IOL implantation group with p value of 0.14 which is statistically not significant.

Table 3: Gender wise distribution.

Gender	Glued scleral fixated IOL	p value
Male	30	1.00 *
Female	20	

*Fisher test

Table 3 showing among 50 cases 30 in glued iol implantation group are males (60%) and 20 are females (40%) with male: female ratio of 1.5:1, p value is 1 which is statistically not significant.

Table 4 showing out of total 50 patients (50 each group) 2 of Dislocated lens, 2 patients of subluxated cataract, 12 cases of subluxated lens, 29 cases of surgically induced

aphakia, 5 cases of traumatic aphakia from Glued IOL implantation group, p value is 0.21 which is statistically not significant.

Table 4: Diagnosis.

Diagnosis	Glued scleral fixated IOL	p value
Dislocated lens	2	0.21*
Subluxated cataract	2	
Subluxated lens	12	
Surgically induced Aphakia	29	
Traumatic Aphakia	5	

* Chi square test

Table 5 showing p value for pre-operative to post-operative vision in Glued IOL is <0.05 i.e. there is definite improvement in vision.

Table 5: Pre-operative and post-operative comparison in Glued scleral fixated IOL group.

Glued scleral fixated IOL	Average Visual acuity	p value
Pre-operative	0.07±0.04	<0.0001*
Post-operative	0.12±0.06	

Wilcoxon matched pair signed rank test

Table 6 showing p value for pre-operative to post-operative intra ocular tension in glued intra ocular lens group is 0.96 i.e. clinically insignificant.

Table 6: IOP pre and post operatively in Glued scleral fixated IOL group.

Glued scleral fixated IOL	Average IOP	p value
Pre-operative	13±1.84	0.96
Post-operative day 1	13.06±2.41	

Wilcoxon matched pair signed rank test.

Table 7 showing Post-operative day 1 complication in Glued Intraocular lens group.

Table 7: Day 1 complication in Glued scleral IOL group.

Complication	Glued scleral fixated IOL	%
No	40	80
Hyphema	3	6
pigment precipitates	0	0
IOL tilt	0	0
Raised IOP	0	0
Vitreous haemorrhage	1	2
Cystoid macular oedema	2	4
Hypotony	4	8

Table 8 showing Post-operative at 6 month complication in Glued Intraocular lens group.

Table 8: Complication in glued IOL at the end of 6 month.

Complication	Glued scleral fixated IOL	Percentage
No	46	92
Pigment precipitates	0	0
IOL tilt	0	0
Optic capture	2	4
Resolved cystoids macular oedema	2	4

DISCUSSION

Correction of aphakia in patients with complicated cataract surgery or trauma and inadequate capsular support is a debatable issue. These patients often require PPV to remove a dislocated crystalline lens, nucleus or IOL. Correction of aphakia by intraocular lens is well accepted surgical procedure. Scleral fixation is a more demanding procedure technically and requires longer operative time and is associated with complications such as retinal detachment, cystoid macular edema and IOL dislocation and tilt. Degradation of the polypropylene sutures may lead to conjunctival erosion and eventually IOL malposition in SFIOL. This post-operative complication has been reported in 27.9% of eyes in one study with 6 years of follow-up and in 24% of cases in another study with 7 years of follow-up.⁷ Posterior chamber glued IOL are suture less techniques of IOL fixation and eliminate all suture related complication. In our study we determine visual outcome and complications of Glued IOL Implantation procedure for correction of aphakia.

Different techniques have been developed for IOL implantation in the absence of capsular support such as PC-IOL and AC-IOL, but each has their own set of limitations. In 2008, Agarwal were the first to describe glued IOL implantation. In this technique, a single-piece non-foldable IOL was used. This procedure has undergone numerous modifications and advances since then.⁸ The advantages associated with glued IOL implantation are the short learning curve, absence of suture-related complications, ability to fix the IOL in aphakic eyes as well as under any complex situations such as subluxated cataract, dislocated IOL, AC-IOL with corneal decompensation and post vitrectomy, and SOR. In this technique, the PC-IOL was fixated without suture to the sclera by inserting the haptics into the sclera pockets. The sclera and conjunctival flaps were sealed with the fibrin glue eliminating the need for sutures, and no special instrumentation was required apart from micro forceps.

This study was conducted with the purpose of evaluating the safety and effectiveness of this relatively new

procedure. In Present study, 50 cases with monocular aphakia and were treated surgically with secondary IOL implantation. All patients examined postoperatively. Visual Acuity recorded on 1st day, 1st week, 1st month, 3rd month, 6th month after surgery. Postoperative complications was recorded on 1st day, 1st week, 1st month, 3rd month and 6th month.

Amongst them 50 cases 30 in glued IOL implantation group are males (60%) and 20 are females(40%) with male: female ratio of 1.5:1. This study shows males are more affected than females. Mean age in glued IOL implantation group is 42.94±24.22 years with p value of 0.14 which is statistically not significant.

There is significant difference in UCVA between the two groups preoperatively and postoperatively. p value for pre-operative to post-operative vision in glued intraocular lens group is <0.0001 i.e. there is definite improvement in vision in glued intraocular group. UCVA_{≥6/24} was present 18 (48%) in Glued IOL subjects. The primary factor analyzed in our study was the improvement in BCVA after the surgery, measured with Snellen visual acuity chart. Eighty-four percent (84.6%) maintained or improved BCVA which compares well with the other study.⁹ In their retrospective analysis of 735 eyes, there was a significant improvement in the UCVA and BCVA of 486 patients with rigid IOLs (paired t-test p=0.000) with the mean postoperative UCVA and BCVA being 0.19±0.19 and 0.38±0.27, respectively.

Post-operative hypotony following both Glued intraocular lens implantation has been raised as a concern in the literature. Mean pre-operative intraocular pressure is 13.0±1.84 mm of Hg in Glued intraocular lens implantation groups. While Mean postoperative intraocular tension is 13.06±2.41 mm of Hg. Out of 50 cases glued intra ocular lens implantation only 4 cases had IOP less than 8 on post-operative day 1 which increased to normal within 4 days. Improper scleral flap sealing or wound leak, large guagesclerotomy, failure to inject air into eye can lead to postoperative hypotony. The glue also helped in sealing the sclerotomy site which would otherwise act as a filtration site and cause hypotony.¹⁰

In this study, no IOL tilt were observed. This was comparable to the study published by Agarwal where the decentration rate was 5.6%.¹¹

There was no precipitation of glaucoma after the glued IOL surgery in any of the patients, which clearly demonstrates that the procedure did not compromise the angles. However, in patients with preexisting glaucoma, aggressive treatment was necessary.

There was no major sight-threatening complication such as retinal detachment as occurred in previous study reported by Kang JJ.¹² We preferred biological glue to stick the flaps, as it prevents formation of subconjunctival bleb, which may happen when the scleral flaps are

sutured. The risk of bleb-related endophthalmitis and suture-related complications are less when the flaps are closed with fibrin glue.¹³⁻¹⁵ The pseudophakodonesis due to the oscillations of the fluids in the anterior and posterior segment is known to cause permanent damage on the corneal endothelium.^{16,17} However, there was no clinical pseudophakodonesis and endothelial cell loss observed in this series.

Uthoff et al, showed suture erosion (17.9%), cystoid macular oedema (5.8%), retinal detachment (1.4%), vitreous haemorrhage (1.0%), and uveitis (0.5%) in a 1-year post-operative outcome of sclera-fixated IOL.¹⁸ Vote et al, showed the high risk of repeat surgeries in sutured SF IOL due to suture-related complications.¹⁹ In Present study, the incidence of CME is 2(4%) and vitreous haemorrhage is 1(2%) in Glued IOL which was resolved within duration of 6 month. It was noted that none of the intraoperative complications in the patients affected the final functional outcome.

The haptics of the sulcus-fixated IOL in direct contact with the posterior surface of the overlying iris can cause focal iris atrophy and pigment dispersion.²⁰ The IOL rotation and recurrent irritation of the iris are known to cause late UGH syndrome.^{21,22} Moreover, rubbing between the IOL optic and iris seems to contribute to the high flare counts in eyes with a sulcus-to-sulcus IOL fixation.²³ Consistent vault is maintained between the iris and the IOL, which was consider as one of the reasons for less post-operative uveitis and pigment dispersion.

Patients with large dislocation of lens, such as traumatic dislocation, Marfan's syndrome did very well with a combined primary procedure of lensectomy with glued IOL.

Limitation of the study is that there is no comparison with other methods of IOL implantation such as Iris claw and sutured sclera-fixated IOL's.

CONCLUSION

Glued IOL implantation is an excellent surgical procedure for implantation of IOL in the absence of capsular support. The technique is completely suture-less in both securing the haptic and sealing the sclera flaps and conjunctiva. The excellent approximation allows sealing of the sclerotomy without leakage ensuring prevention of wound-related complications and endophthalmitis. In addition, it is possible to combine it with other techniques where suturing is not essential. The technique has a short learning curve and requires minimal instrumentation. Glued IOL implantation is a relatively new procedure with published reports from handful of institution. This study provides information from the institution.

Funding: No funding sources

Conflict of interest: None declared

Ethical approval: The study was approved by the Institutional Ethics Committee

REFERENCES

1. Choragiewicz T, Rejdak R, Grzybowski A, Nowomiejska K, Moneta-Wielgoś J, Ozimek M, et al. Outcomes of Sutureless iris-claw lens implantation. *J Ophthalmol.* 2016;2016.
2. Agarwal A, Kumar DA, Jacob S, Baid C, Agarwal A, Srinivasan S. Fibrin glue-assisted sutureless posterior chamber intraocular lens implantation in eyes with deficient posterior capsules. *J Cataract Refractive Surg.* 2008 Sep 1;34(9):1433-8.
3. Lagoutte FM, Gauthier L, Comte PRM. A fibrin sealant for perforated and preperforated corneal ulcers. *Br J Ophthalmol.* 1989;73:757-61.
4. Falavarjani KG, Modares M, Foroutan A, Bakhtiari P. Reply: Fibrin glue-assisted sutureless scleral fixation. *J. Cataract Refract. Surg.* 2009;35:795-6.
5. Kumar DA, Agarwal A, Agarwal A, Prakash G, Jacob S. Glued intraocular lens implantation for eyes with defective capsules: A retrospective analysis of anatomical and functional outcome. *Saudi J Ophthalmol.* 2011 Jul 1;25(3):245-54.
6. Kumar DA, Agarwal A. Glued intraocular lens: a major review on surgical technique and results. *Curr Opin Ophthalmol.* 2013 Jan 1;24(1):21-9.
7. Hazar L, Kara N, Bozkurt E, Ozgurhan EB, Demirok A. Intraocular lens implantation procedures in aphakic eyes with insufficient capsular support associated with previous cataract surgery. *J Refract Surg.* 2013 Jul 30;29(10):685-91.
8. Ganekal S, Venkataratnam S, Dorairaj S, Jhanji V. Comparative evaluation of suture-assisted and fibrin glue-assisted scleral fixated intraocular lens implantation. *J Refrac Surg.* 2012 Apr 1;28(4):249-52.
9. Agarwal A, Kumar DA, Nair V. Cataract surgery in the setting of trauma. *Curr Opin Ophthalmol.* 2010 Jan 1;21(1):65-70.
10. Maheshwari R, Vaishnavi T, Revanasiddappa I, Joseph J, Kalikivayi V, Cherian Jacob S. Safety and efficacy of trans-scleral glued intraocular lens implantation. *Ann Eye Sci.* 2017 Jul 14;2(7).
11. Mohan S, John B, Rajan M, Malkani H, Nagalekshmi SV, Singh S. Glued intraocular lens implantation for eyes with inadequate capsular support: Analysis of the postoperative visual outcome. *Ind J Ophthalmol.* 2017 Jun;65(6):472.
12. Kang JJ, Ritterband DC, Toles SS, Seedor JA. Outcomes of glued foldable intraocular lens implantation in eyes with preexisting complications and combined surgical procedures. *J Cataract Refract Surg.* 2015 Sep 1;41(9):1839-44.
13. Song A, Scott IU, Flynn Jr HW, Budenz DL. Delayed-onset bleb-associated endophthalmitis: clinical features and visual acuity outcomes. *Ophthalmol.* 2002;109: 985-91.
14. Price MO, Price Jr FW, Werner L, Berlie C, Mamalis N. Late dislocation of scleral-sutured posterior chamber intraocular lenses. *J Cataract Refract Surg.* 2005;31:1320-6.

15. Heilskov T, Joondeph BC, Olsen KR, Blankenship GW. Late endophthalmitis after transscleral fixation of a posterior chamber intraocular lens. *Arch Ophthalmol.* 1989;107:1427.
16. Jacobs PM, Cheng H, Price NC. Pseudophakodonesis and corneal endothelial contact: direct observations by high-speed cinematography. *Br J Ophthalmol.* 1983;67:650-4.
17. Jacobi KW, Jagger WS. Physical forces involved in pseudophacodonesis and iridodonesis. *Albrecht Von Graefes Arch Klin Exp Ophthalmol.* 1981;216:49-53.
18. Uthoff D, Teichmann KD. Secondary implantation of scleral-fixated intraocular lenses. *J Cataract Refract Surg.* 1998;24:945-50.
19. Vote BJ, Tranos P, Bunce C, Charteris DG, Da Cruz L. Long-term outcome of combined pars plana vitrectomy and scleral-fixated sutured posterior chamber intraocular lens implantation. *Am J Ophthalmol.* 2006;141:308-12.
20. Ferguson AW, Malik TY. Pseudophakic posterior iris chafing syndrome. *Eye.* 2003;17:451-2.
21. John G, Stark W. Rotation of posterior chamber intraocular lenses for management of lens-associated recurring hyphemas. *Arch Ophthalmol.* 1992;110:963-4.
22. Nicholson D. Occult iris erosion: a treatable cause of recurrent hyphema in iris-supported intraocular lenses. *Ophthalmol.* 1982;89:113-20.
23. Amino K, Yamakawa R. Long-term results of out-of-the-bag intraocular lens implantation. *J Cataract Refract Surg.* 2000;26:266-70.

Cite this article as: Gonde PP, Aghadate S. Safety and efficacy of glued intraocular lens implantation in eyes with inadequate capsular support. *Int J Res Med Sci* 2020;8:1419-25.