

## Case Report

# Laparoscopic cholecystectomy in a patient with pneumonectomy

Nisha Sharma, Ankita Chandel\*, Manjit Singh Kanwar

Department of Anaesthesia, Dr. Radhakrishnan Government Medical College, Hamirpur, Himachal Pradesh, India

**Received:** 14 February 2020

**Revised:** 20 February 2020

**Accepted:** 06 March 2020

**\*Correspondence:**

Dr. Ankita Chandel,

E-mail: [ankitachandelchauhan@gmail.com](mailto:ankitachandelchauhan@gmail.com)

**Copyright:** © the author(s), publisher and licensee Medip Academy. This is an open-access article distributed under the terms of the Creative Commons Attribution Non-Commercial License, which permits unrestricted non-commercial use, distribution, and reproduction in any medium, provided the original work is properly cited.

### ABSTRACT

Post pneumonectomy patients pose a challenge to the anaesthetist owing to the altered respiratory mechanics and decreased respiratory reserve. Performing laparoscopic surgery in such patients further deteriorates the already compromised lung functions. Authors report a case of laparoscopic cholecystectomy performed in post pneumonectomy patient. A clear understanding of respiratory mechanics and post pneumonectomy physiological changes helped us to administer a safe anaesthesia and safe perioperative outcome.

**Keywords:** Anaesthesia, Cholecystectomy, Perioperative, Respiratory, Surgery

### INTRODUCTION

Laparoscopic technique of cholecystectomy has now become gold standard when compared with open cholecystectomy due to well documented advantages in relation to respiration, cardiovascular as well as overall perioperative wellbeing of patient.<sup>1</sup> But pneumoperitoneum created by CO<sub>2</sub> insufflation sometimes poses a challenge especially in patients with respiratory diseases. Pneumonectomy is one such condition which compromises the respiratory reserve of a patient. Post-pneumonectomy patients pose challenges in anaesthesia management.<sup>2</sup> Oxygenation and ventilation changes due to the absence of one lung, age, associated systemic co-morbidities affects the outcome after surgery.

Literary data for laparoscopic cholecystectomy in post pneumonectomy patients is limited and also there are no guidelines regarding anesthetic consideration for laparoscopic surgery in a patient with one lung. We hereby, report a case of laparoscopic cholecystectomy in a patient with previous pneumonectomy. An understanding of the combined physiological consequences of pneumonectomy and pneumoperitoneum facilitated the provision of safe and uneventful anaesthesia.

### CASE REPORT

A 40 years old female diagnosed with symptomatic cholelithiasis was scheduled for laparoscopic cholecystectomy. She had history of right-side pneumonectomy done 20 years back for bronchiectasis with pulmonary hemorrhage. On examination there was no cyanosis, respiratory rate was 18 per minute, heart rate was 98/min and baseline SPO<sub>2</sub> was 88%. On auscultation breath sounds were absent on right side of the chest while vesicular breath sounds were present on left side. Metabolic equivalents were >5. Her Pulmonary Function Tests (PFT) showed FEV<sub>1</sub> 23%, FVC 27% and FEV<sub>1</sub>/FVC 86.2% of predicted values (Figure 1).

Chest X-ray showed upward deviation of right hemidiaphragm with hyperinflated left lung and mediastinal shift towards right side (Figure 2).

On day of surgery her preoperative vitals were HR - 100/min, B.P - 110/74 mm Hg, SPO<sub>2</sub> on room air 89%. After preoxygenation patient was induced with Inj fentanyl 100 µg iv, inj propofol 100 mg iv and inj atracurium 25 mg iv. A size 7.5 mm ID Cuffed ETT was introduced after direct laryngoscopy. Maintenance of

anaesthesia was done with 66% N<sub>2</sub>O, 33% O<sub>2</sub> and 0.2 to 1.2 % isoflurane. Inj diclofenac 75 mg and Inj PCM 1 gm were given intraoperatively. Total duration of surgery was 40 minutes. CO<sub>2</sub> insufflation was done at slower rate of 2 l/min instead of 4-6l/min. Intraabdominal pressure was kept at 8-10 mmHg instead of 12-14 mm Hg.

Parameter		Pred	Test	%Pred
SVC	L	2.93	0.97	33.3
FVC	L	3.35	0.93	27.8
FEV 1	L	2.76	0.66	23.8
FEV 1/FVC	%	81.69	70.45	86.2
PEF	L/M	392.10	116.88	29.8
FEF 2-1.2	L/S	5.19	0.41	13.6
FEF 25-75	L/S	3.00	0.07	6.8
FEF 75-85	L/S	1.07	0.57	14.2
FEF 50	L/S	3.98	0.81	27.5
FIVC	L	2.96	24.60	23.8
MVV ind	L/M	103.48		

Figure 1: Post pneumonectomy ABG of patient.

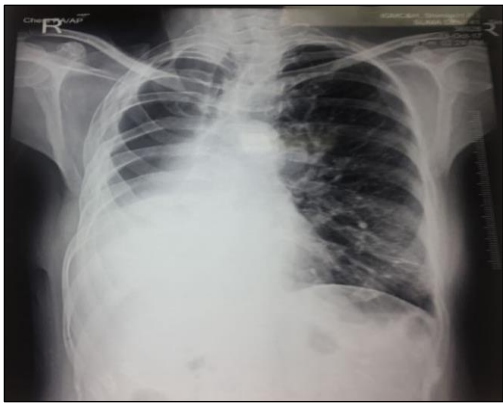


Figure 2: Post pneumonectomy chest x ray showing mediastinal shift and air in right side of chest.

Patient was ventilated with 260 ml at RR of 14 - 16/min so as to keep Etco<sub>2</sub> between 35 to 40 mm Hg. Peak pressure were kept below 23 cm of H<sub>2</sub>O, plateau and peep were 10 cm of H<sub>2</sub>O and 0 cm of H<sub>2</sub>O. Local infiltration with 14 ml of bupivacaine (7ml diluted with 7 ml of NS) was done at port sites. Extubation was done after giving reversal with inj neostigmine 2.5 mg iv and inj glycopyrrolate 0.4 mg iv. Patient was kept in PACU for one hour on ventimask at O<sub>2</sub> flow of 4 l/min in propped up position. Patient was discharged after one day from ward without any need for supplemental O<sub>2</sub>.

**DISCUSSION**

Laparoscopic Cholecystectomy (LC) provides advantages of being minimally invasive, less postoperative respiratory complications, early ambulation to name a few over open cholecystectomy.<sup>1</sup> With five-year survival rates in patients undergoing pneumonectomy exceeding 40% for malignant disease and 75% for benign disease.<sup>3-5</sup> an anesthetist can reasonably expect to encounter an increasing number of these patients presenting for elective or emergency surgery.

The postpneumonectomy state is associated with predictable anatomic and physiological changes. With time, the heart and mediastinum deviate toward the side of the resected lung, by counterclockwise rotation after left pneumonectomy and by translocation after right pneumonectomy. The remaining lung develops compensatory hyperinflation and frequently herniates across the midline. Elevation of the ipsilateral hemidiaphragm shifts the liver or spleen in a cephalad direction.<sup>6</sup> The postpneumonectomy space is immediately filled with air after surgery and this space is slowly obliterated by raising of hemidiaphragm, mediastinal shift to operated side and filling up with fluid. Complete opacification may not occur in all the patients with most patients having residual fluid or air as in our case.

Right pneumonectomy is associated with a threefold greater mortality than left pneumonectomy. Reasons for this are unclear, although anatomical factors predispose to a higher incidence of serious early and late complications after right-sided surgery. These include bronchopleural fistula and empyema, postpneumonectomy pulmonary oedema, postoperative arrhythmias, pulmonary artery thrombosis, and the postpneumonectomy syndrome in which long-term anatomical changes result in stretching and extrinsic compression of the tracheobronchial tree and oesophagus.<sup>7</sup>

Pneumonectomy patients have decreased respiratory reserve. And it has been found that decrease in lung functions are not by 50% as expected. There is mixed restrictive and obstructive pattern. Long term changes after pneumonectomy are decrease in FEV<sub>1</sub> and FVC by 30% with greater loss occurring after right pneumonectomy than after left pneumonectomy. DLCO is reduced by 33% of predicted value but still high as expected for one lung.<sup>8</sup> ABG values are normal, pulmonary hypertension is quite uncommon and exercise capacity is normal. Pulmonary hypertension if present is mostly mild and more so with left pneumonectomy.

It has been found that peak airway and plateau airway pressures increasing by 50% and 81% respectively while the compliance of the respiratory system decreases by 47% during pneumoperitoneum in the supine position.<sup>9</sup> Following the release of pneumoperitoneum, peak and plateau pressures remain elevated by 37% and 27% respectively, and the compliance is 86% of the preinsufflation value. There is a significant increase in the linear elastance and resistance and a significant decrease of flow and volume dependence of resistance. Peak pressures increase by 6 cmH<sub>2</sub>O, mean pressure by 3 cmH<sub>2</sub>O and end-inspiratory airway pressure increases by 40%. After release of the pneumoperitoneum, inspiratory airway pressure and compliance return to control levels.<sup>8,9</sup> The increase in Paco<sub>2</sub> is 15% to 25% which pleatues after 15 to 30 minutes.

In patient we chose to give general anaesthesia with airway secured with cuffed ETT, controlled ventilation with TV of 5ml/kg and RR of 14 - 18/min. Our main aim

was to provide safe anaesthesia while taking into account the effect of decreased pulmonary reserve of the patient and the added effects of pneumoperitoneum on respiratory system.

Firstly, authors preferred GA over regional anaesthesia. Patient anxiety, discomfort from abdominal distention and shoulder tip pain due to diaphragmatic irritation always necessitates iv sedation. This results in hypoventilation. Greater increases in ETCO<sub>2</sub> in pneumonectomy patient together with hypoventilation are not acceptable. So, authors preferred to hyperventilate patient by controlled ventilation with low TV of 5 ml/kg so as to prevent volume trauma with increased RR to prevent hypercapnia.

Airway was secured with cuffed ETT to make sure so that the only lung is protected from aspiration risk. These patients may have functional changes in oesophageal motility with dysphagia. Though increased risk of aspiration is not clear but due to increased intraabdominal pressures can increase the risk so preventive measures should be done to protect the remaining lung.

Insufflation of abdomen was done at slower rate so as to prevent sudden cardiovascular respiratory changes.<sup>10</sup> Intraabdominal pressure was kept between 8-10 mmHg so as to prevent large increases in airway pressures and hence barotrauma.

With all these measures hypercapnia was prevented, airway pressures were kept below 25 cm H<sub>2</sub>O and patient remained hemodynamically stable. It may be because of head up and right tilt of the patient.

## CONCLUSION

Laparoscopic surgery which has a compromising effect on the respiratory mechanics can be safely done in a patient of pneumonectomy without any untoward intraoperative and postoperative consequences. Taking into consideration a few points regarding controlled ventilation with low tidal volumes and hyperventilation and intraperitoneal pressures to be kept on lower side. Gasless laparoscopies may be considered a better choice if available as there are no cardiorespiratory effect.

*Funding: No funding sources*

*Conflict of interest: None declared*

*Ethical approval: Not required*

## REFERENCES

1. Joris JL. Anesthesia for laparoscopic surgery. In: RD, Miller LA, Eriksson LA, Fleisher et al., eds. Miller's Anesthesia. Churchill Livingstone, Philadelphia, Pa, USA; 2010: 21-95.
2. Bardoczky GI, Engelman E, Levarlet M, Simon P. Ventilatory effects of pneumoperitoneum monitored with continuous spirometry. Anaesthesia. 1993 Apr;48(4):309-11.
3. Veen EJ, Janssen-Heijnen MLG, Ritchie ED, Biesma B, van den Bogart MPH, Bolhuis RJ. Pneumonectomy for bronchogenic carcinoma: analysis of factors predicting short- and long-term outcome. Intera Cardio Thoracic Surg. 2009;9(2):260-4.
4. Kawaguchi T, Tojo T, Kushibe K, Kimura M, Nagata Y, Taniguchi S. Short- and long-term outcomes after pneumonectomy for primary lung cancer. Ann Thoracic Cardio Surg. 2008;14(5):289-93.
5. Massard G, Lyons G, Wihlm JM, Fernoux P, Dumont P, Kessler R, et al. Early and long-term results after completion pneumonectomy. Ann Thor Surg. 1995 Jan 1;59(1):196-200.
6. Vassiliou MP, Rizzoti L, Laopodis V. Non-linear evaluation of respiratory mechanics during laparoscopic cholecystectomy. Hepato gastroenterol. 2003;50(52):934-8.
7. Kopec SE, Irwin RS, Umali-Torres CB, Balikian JP, Conlan AA. The postpneumonectomy state. Chest. 1998 Oct 1;114(4):1158-84.
8. Deslauriers J, Ugalde P, Miro S, Deslauriers DR, Ferland S, Bergeron S, et al. Long-term physiological consequences of pneumonectomy. In Seminars in thoracic and cardiovascular surgery 2011 Sep 1;23(3):196-202.
9. Smulders SA, Smeenk FW, Janssen-Heijnen ML, Postmus PE. Actual and predicted postoperative changes in lung function after pneumonectomy: a retrospective analysis. Chest. 2004 May 1;125(5):1735-41.
10. Di Sebastiano N, Bonetti L, Boninsegni P et al. Respiratory mechanics and gas exchange in anesthesia for laparoscopic cholecystectomy. Minerva Anesthesiol. 1993 Oct;59(10):487-92.

**Cite this article as:** Sharma N, Chandel A, Kanwar MS. Laproscopic cholecystectomy in a patient with pneumonectomy. Int J Res Med Sci 2020;8:1582-4.