

## Review Article

# Subacute sclerosing panencephalitis: case based review

Raman Singh<sup>1\*</sup>, Zubin A. Mahajan<sup>1</sup>, Sameera R. Mehta<sup>1</sup>, Jayesh Ranchhod<sup>2</sup>,  
Soham J. Nadkarni<sup>3</sup>

<sup>1</sup>MBBS, <sup>2</sup>Intern, Bharati Vidyapeeth University and Medical College, Pune, Maharashtra, India

<sup>3</sup>Student, MBBS, Lokmanya Tilak Municipal Medical College, Mumbai, Maharashtra, India

**Received:** 14 June 2020

**Accepted:** 06 July 2020

### \*Correspondence:

Dr. Raman Singh,

E-mail: [proframan@hotmail.com](mailto:proframan@hotmail.com)

**Copyright:** © the author(s), publisher and licensee Medip Academy. This is an open-access article distributed under the terms of the Creative Commons Attribution Non-Commercial License, which permits unrestricted non-commercial use, distribution, and reproduction in any medium, provided the original work is properly cited.

### ABSTRACT

Subacute sclerosing panencephalitis (SSPE) is a chronic debilitating condition that occurs in children affected with measles. SSPE is broadly distinguished as typical SSPE, the more rampant form, occurring over a period of years following primary measles infection, while the atypical has a more rapidly progressive course over weeks to months. SSPE can present with cognitive, epileptic, autonomic, pyramidal and ophthalmologic manifestations with scholastic decline being the primary feature. The management of SSPE focuses on improvement of quality of life and prolongation of survival which can be achieved with the use of supportive care modalities and immunomodulators respectively. This is a comprehensive review which discusses several parameters of SSPE such as epidemiology, pathophysiology, clinical presentations, and detailed management protocol for this condition. As part of this review, we also discuss a case of rapidly progressive, fulminant and atypical SSPE in a five-year-old male presenting clinically with myoclonic jerks of lower extremities.

**Keywords:** Isoprinosine, Measles virus, Myoclonic jerks, Subacute sclerosing panencephalitis

### INTRODUCTION

Subacute sclerosing panencephalitis (SSPE) is a chronic, progressive, inflammatory, and degenerative affliction of the brain caused by a mutation due to persistent infection with an altered measles virus (MV).<sup>1</sup> The virus directly infects the brain causing progressive inflammation and sclerosis due to an impaired immune response.<sup>2,3</sup> SSPE usually has a predilection for children and younger adults and has broadly distinguished into typical and atypical SSPE. The typical SSPE usually occurs over a slow course of 6-10 years after primary measles infection as compared to the atypical form usually has a more fulminant course occurring within 1-6 months with a few occasional cases with deterioration occurring over a small span of 15 days.<sup>4</sup>

A case report by Gokcil et al, shows that death occurred in the concerned patient within a short span of two

months.<sup>5</sup> A World Health Organization (WHO) expert group reported the global incidence of four to 11 SSPE patients per 100 000 measles cases.<sup>6</sup> In developing countries, the incidence seems to be much higher with up to 27.9 SSPE patients per 100 000 cases of measles.<sup>7</sup> In contrast, developed countries like Canada have incidence as low as 0.06 per 100 000 cases that can be attributed to the widely implemented vaccination programs.<sup>7</sup> With due consideration to age distribution, the incidence of SSPE is twice as high (1:609) when measles infection is acquired in infancy compared to childhood up to 5 years of age (1:1367).<sup>8</sup> Furthermore, the male to female ratio of SSPE is approximately 3:1.<sup>9</sup>

Subacute sclerosing panencephalitis is a serious neurological disorder characterized by continual mental deterioration ultimately terminating in optic atrophy, akinetic mutism, and clinical signs suggestive of decortication. It usually manifests as behavioral changes,

cognitive impairment, inattention, progressive difficulties with academic skills and myoclonic seizures.<sup>10</sup>

The clinical presentation of SSPE can mimic some of the more common neurological conditions in children such as hypoxic ischemic encephalopathy due to Status

epilepticus, Japanese encephalitis and autoimmune encephalitis as shown in Table 1 below.<sup>11-16</sup> In this case-based review article, we discuss a case of a very rare case of atypical SSPE in a 5-year-old male child and comprehensively summarize epidemiology, clinical parameters, clinical diagnosis and management of SSPE.

**Tables 1: Differential diagnosis of SSPE.**

Condition	Age of onset	Clinical features	Investigations
Hypoxic Ischemic Encephalopathy	Perinatal. 76% survive into childhood.	Cerebral palsy, visual and auditory deficits, epilepsy and developmental delay.	Neurological examination, MRI, EEG and biomarkers including glial fibrillary acidic protein.
Japanese Encephalitis	Variable (vector-borne disease)	Fever, headache, impaired consciousness, seizures including GTCS and subtle motor and dyskinesias.	Serum ELISA for anti-JEV antibodies, CSF protein, CT and MRI.
Autoimmune encephalitis	Variable (all subtypes have a very wide age range)	Fever, headache, cognition impairment, behavioral changes, dyskinesias, focal and generalized seizures	Serum and CSF auto-immune antibodies according to subtype. (anti-NMDA, anti-VGKC, etc.)

## CASE FINDINGS

A 5-year old male with a past medical history of Measles infection came to the hospital due to episodes of jerky movements of the lower limbs and trunk associated with repetitive falls for the past 4 weeks, occurring both during wakefulness and sleep. This gradually progressed from 2-3 episodes a day initially, to approximately 8-10 episodes per day over a short span of 15 days. The past medical history suggests measles infection 8 months ago, while family history was noncontributory. The birth was a full-term normal vaginal delivery without perinatal complications. He is developmentally normal and his immunization history is unclear since the parents were unable to provide medical immunization records.

On admission, his vitals were stable and examination of the respiratory, cardiovascular, abdominal systems was noncontributory. Inspection of his face demonstrated scars on the right cheek likely due to recurrent falls. Central nervous system examination revealed intact consciousness and with preserved function of the cranial nerves and the sensory domains. The motor system demonstrated normal tone, reflexes and 4/5 power in all four extremities. There were no signs of meningeal irritation.

The child was hospitalized, with a provisional diagnosis of myoclonic jerks, for further investigation of the etiology. Over the hospital course, there was worsening of his cognitive functions and his speech became slurred and slow. The power declined to 3/5 in all extremities with persistence of myoclonic jerks and falls during

walking. Additionally, intermittent fever spikes were also recorded.

A seizure workup consisting of complete blood count (CBC), serum electrolytes, electroencephalogram (EEG), Magnetic resonance imaging (MRI) of the brain and lumbar puncture for cerebrospinal fluid (CSF) examination was conducted over the hospital course. The CBC, electrolytes were within normal ranges. The EEG presented periodic high-voltage complexes associated with the muscle jerks. The MRI of the brain did not show any intracranial abnormality. Since MRI was inconclusive, parental consent was obtained for lumbar puncture and a pre-anesthetic evaluation was conducted. CSF sample was clear and cytology revealed predominant lymphocytosis and no red blood cells. A CSF sample was sent to the National Institute of Mental Health and Neurosciences, Bangalore, for analysis and it showed positive anti-measles antibodies. The patient's recent medical history of measles infection with 8 months accompanied by unclear vaccination background in addition to the episodic myoclonic seizures with periodic high voltage complexes on EEG and CSF analysis demonstrating positive anti-measles antibodies suggests the diagnosis of atypical subacute sclerosing panencephalitis SSPE.

The management of this patient focused on appropriate seizure control was broadly classified as symptom control and prevention of disease progression and supportive therapy. The seizure was controlled with oral clonazepam (0.25 mg) OD and oral levetiracetam (100 mg/ml) at a dose of 1 ml BD. The fever spikes were controlled with

an oral dose of acetaminophen as needed. The disease control was achieved with the use of an immunomodulator, Isoprinosine. The dose of isoprenosine was gradually increased as follows in order to prevent the occurrence of unfavorable side effects: 250 mg BD on the first day, 250 mg TDS on days 2 and 3, and 500 mg TDS on days 4-6. Afterward, the patient received maintenance therapy at dose of 500 mg TDS. Nutritional supplementation was provided with folic acid, methylcobalamin, pyridoxine and oral feeds to prevent hospital acquired malnutrition. Additionally, trauma precautions were taken to ensure safe transit within the hospital.

## DISCUSSION

### *Pathophysiology*

The understanding of the pathophysiology of this disease may be the primary step for comprehension of its clinical parameters. On gross examination of brain parenchyma, demyelination of white matter is observed in temporal and parietal lobes during the initial stages of SSPE. Other areas like basal ganglia, thalamus, brainstem, white matter of corona radiata, and cerebellar peduncles are also affected eventually, while diffuse cortical atrophy and ventricular dilatation occur at later stages. Histologically, neuronophagia, microglial nodules, intranuclear inclusions and oligodendroglial cells are seen with hyperphosphorylated tau and neurofibrillary tangles. Additionally, there is perivascular inflammation consisting of lymphocytes and histiocytes suggestive of marked panencephalitis.<sup>17-19</sup> The measles virus attacks GABAergic and glutamergic neurons but spares the cholinergic pathway which explains the involvement of motor, somatosensory, auditory and visual cortex, basal ganglia and thalamus sparing the hippocampus and cerebellum.<sup>20,21</sup>

### *Clinical features*

SSPE can be described based on multiple clinical paradigms such as cognitive, epileptic, pyramidal, autonomic, and ophthalmologic. The cognitive impairment is progressive ultimately terminating to the poor scholastic performance in addition to the memory deficits and verbal incompetence. A study conducted by Khadilkar et al. in India shows that poor scholastic performance is the most common presentation affecting 52.5% of the patients, followed by seizures in 23.5%, with myoclonic seizures being the most common variant.<sup>22</sup> On the contrary, case series conducted by Gadoth et al, showed that 6/40 patients had true epileptic seizures with focal seizures being the most common variant.<sup>23</sup>

The epileptic features start as myoclonus, which in initial stages, may be imperceptible. Subtle myoclonus can be unveiled by observing the patient with outstretched upper limbs and while doing the finger-to-nose test and tandem

walking. The myoclonus is typically generalized, periodic and stereotyped, translating into generalized, high-amplitude periodic complexes. Pyramidal manifestations, a consequence of rigidity and spasticity, ultimately culminates to akinesia, dystonia and chorea.<sup>24,26</sup> Hyperhidrosis and fever are some of the accompanying autonomic disturbances.<sup>23</sup> While cognitive impairment and seizures are commonest features, ophthalmological findings are also characteristic of this disease and precede neurological manifestations by weeks to years.<sup>27</sup> Chorioretinitis is a hallmark of SSPE characterized by macular involvement, characterized by dilated tortuous veins, retinal hemorrhages, sub-retinal exudates and pigmentary changes.<sup>28</sup> According to Baillif et al., infrequent findings such as serous macular detachment, retinal vasculitis, subretinal fluid, papillitis may additionally occur among SSPE patients.<sup>29</sup>

### *Staging of SSPE*

The Risk- Haddad classification, utilizes the clinical course of SSPE, to stage the disease. Stage 0 corresponds to subtle neurological deficits that go unnoticed. Stages 1 is characterized by noticeable neurological deficits, while onset myoclonic jerks define stage 2. Stage 2 is further classified into 2a (jerks without falls), 2b (jerks with falls in an ambulatory patient) and 2c (jerks with falls in a bedridden patient). Stage 3 parallels to stupor initially (3a and 3b) and coma later (3c). The patient falls into stage 4 if he experiences some improvement in symptoms. However, if after improvement, he relapses into SSPE, he would be categorized as stage 5.<sup>30</sup> Based on this staging system, our patient can be defined as having stage 2b SSPE.

### *Diagnosis*

The diagnosis of SSPE relies on the modified Dyken's criteria that consists of major and minor criteria. Two major and one minor criterion must be satisfied to confirm the diagnosis of SSPE.

The major criteria include clinical history and CSF measles antibody titers while minor criteria include EEG, MRI and brain biopsy. Of note, brain biopsy given its invasive nature, is incompatible with routine use and is therefore restricted to cases where clinical suspicion is high and the antibody titer is negative.<sup>31</sup> The EEG tracing in SSPE includes generalized, periodic and synchronous sharp-slow wave discharges which are polyphasic lasting from 0.5 to 2 seconds, high in voltage (300-1500 mV), and regularly repetitive (occurring every 4 to 15 s). These discharges are stereotyped in the form of large delta waves, large delta waves and rapid spikes, or fast activity and persist during sleep.<sup>32</sup> These EEG findings have been noted in 65% to 83% of patients of SSPE present with these EEG findings and diazepam is often injected intravenously during the study to increase the sensitivity of the testing-the periodic discharges become more noticeable.<sup>33,34</sup>

The detection of CSF IgG against the measles virus using the Enzyme linked immunosorbent assay (ELISA) technique has a very high sensitivity and specificity (table 2) value which explains why it is a major criterion in the diagnosis of SSPE.<sup>7,35</sup> Other nonspecific CSF findings in SSPE are oligoclonal bands and lymphocytosis.<sup>36</sup> The neuroimaging modalities may include a CT or MRI brain:

- **CT:** It is normal in the early stages of SSPE. Later, focal white matter hypodensities in parieto-occipital regions can be seen.<sup>37</sup>
- **MRI:** It is also normal in the earlier stages of this disease. However, in later stages, bilateral asymmetric periventricular and subcortical white matter hyperintensities on fluid-attenuated inversion recovery (FLAIR) are seen. Occasionally, the corpus callosum, basal ganglia, cerebellum, and brainstem are affected. Finally, cerebral atrophy is additionally seen.<sup>38</sup>

**Table 2: Sensitivities and specificities of investigations for SSPE.**

Investigation	Jabbour stage	Sensitivity (%)	Specificity (%)
CSF IgG	All stages	100	93.3
MRI	I	No MRI findings	No MRI findings
	II	60	87.5
	III	87.5	100
	IV	87.5	100

### Management

SSPE is ultimately a terminal disease with a few documented survivors. Therefore, the management of SSPE is primarily to prolong survival and improve the quality of life. The treatment can be broadly classified into averting the disease pathology and controlling symptoms as illustrated in Figure 1. As described earlier, SSPE has a unique disease pathology which can be modified by the use of immunomodulation and inhibition of measles antibodies.

#### Immunomodulation

Immunomodulation therapy mainly comprises of isoprinosine and interferons. Isoprinosine has immunostimulant properties and administered orally in a dosage of 100 mg per kg (maximum of 3000 mg) per day, usually in three to five divided doses.<sup>39</sup> A multi-centered non-randomized controlled study involving 98 patients with SSPE concluded that isoprinosine has increased survival by 2 years in patients in comparison to the control group.<sup>39</sup> However, the use of this drug is limited by its cost and lack of availability in developing countries.<sup>40</sup> Similarly, Interferons are immunomodulators that are usually given in combination with Isoprinosine and are administered subcutaneously at a dose of 10

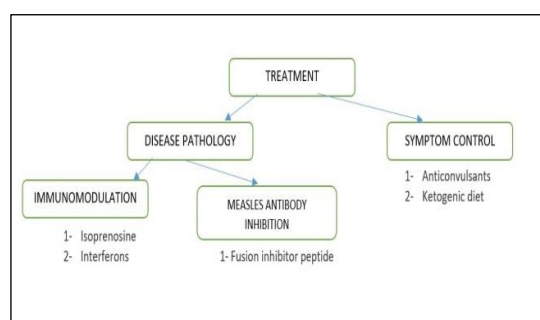
million units/m<sup>2</sup> three times a week or intrathecally and via the intraventricular route.<sup>41</sup> Intraventricular interferon- $\alpha$  dose ranges from 100 000 to 1 000 000 U/m<sup>2</sup>, usually given for 2 to 5 days a week. Interferon- $\beta$  is manufactured from virus-infected fibroblasts.<sup>41</sup> A multicenter randomized study involving 121 patients showed that improvement in SSPE outcomes was 34% in the Isoprinosine group and 35% in the interferon- $\alpha$  group, suggesting similar efficacies.<sup>42</sup>

#### Inhibition of measles antibodies

Fusion inhibitor peptides (FIP) are a prospective option for the treatment of SSPE. Measles virus (MV) can spread between neurons through its hyperfusogenic F protein. A fusion inhibitor peptide has been developed which binds to the F protein limiting the interneuronal spread. The study by Watanabe et al., confirms that FIP inhibits HR2 region of MV both in vivo and in vitro.<sup>43</sup>

#### Supportive care

Myoclonic jerks are a prominent debilitating symptom in SSPE. Two modalities are tried to control the jerks: anticonvulsants and a ketogenic diet. The anticonvulsants such as Carbamazepine, levetiracetam and clobazam have been tried to control myoclonic jerks without any effect on disease progression in SSPE and related neurological deterioration.<sup>44</sup> The Ketogenic diet (KD) has also been tried and it has been observed to reduce myoclonic jerks via decreasing neuronal hyperexcitability in the hippocampus and reducing oxidative stress given its anti-inflammatory properties. KD has also improved physical and cognitive skills in these patients.<sup>45,46</sup>



**Figure 1: Management modalities for SSPE.**

#### Prognosis

SSPE does not have a cure and there are few documented survivors with SSPE infection. Therefore, palliative options are available to improve the quality of life and slow disease progression. However, death is inevitable within 1 to 3 years after diagnosis with 41% patients surviving upto 2 years as per Risk and Haddad.<sup>47,48</sup> Around 5% of SSPE patients have spontaneous long-term remission and have survived up to 8 years. This may be due to recent management modalities such as

immunomodulators. According to a prospective study conducted by Prashanth et al., use of medications like interferons can increase survival up to 18 years.<sup>49</sup>

## CONCLUSION

SSPE is a progressive, debilitating neurological disorder following primary measles infection. It remains a burden in countries with a high incidence of measles infection where vaccination is inefficient. SSPE can present with cognitive, autonomic, epileptic, ophthalmologic and pyramidal manifestations. Once the diagnosis of SSPE is made, the management modalities are limited and the prognosis is very poor. However, immunomodulatory therapy along with symptom control has shown to increase life expectancy by a few years.

*Funding: No funding sources*

*Conflict of interest: None declared*

*Ethical approval: Not required*

## REFERENCES

- Bellini WJ, Rota JS, Lowe LE, Katz RS, Dyken PR, Zaki SR, et al. Subacute sclerosing panencephalitis: more cases of this fatal disease are prevented by measles immunization than was previously recognized. *J Infectious Disease.* 2005 Nov 15;192(10):1686-93.
- Garg RK. Subacute sclerosing panencephalitis. *Postgraduate Med J.* 2002 Feb 1; 78(916):63-70.
- Griffin DE, Ward BJ, Esolen LM. Pathogenesis of measles virus infection: an hypothesis for altered immune responses. *J Infectious Disease.* 1994 Nov 1;170(Supplement\_1):S24-31.
- Jain RS, Sannegowda RB, Srivastava T, Jain R, Mathur T, Gandhi P. A rare presentation of subacute sclerosing panencephalitis with acute fulminant course and atypical radiological features. *Ann Indian Acad Neurol.* 2013 Oct 1;16(4):732.
- Gökçil Z, Odabaşı Z, Aksu A, Vural O, Yardim M. Acute fulminant SSPE: clinical and EEG features. *Clinical Electroencephalography.* 1998 Jan;29(1):43-8.
- World Health Organization. Weekly epidemiological record. No. 2, 2006, 81,13-20. Geneva, Switzerland. Available at: [http://www.who.int/vaccine\\_safety/committee/reports/wer8102.pdf?ua=1](http://www.who.int/vaccine_safety/committee/reports/wer8102.pdf?ua=1) Accessed on 1 May 2020.
- Alkan A, Korkmaz L, Sigirci A, Kutlu R, Yakinci C, Erdem G, et al. Subacute sclerosing panencephalitis: Relationship between clinical stage and diffusion-weighted imaging findings. *J Magn Resonance Imaging: J Intern Society for Magnetic Resonance Med.* 2006 Mar;23(3):267-72.
- Ko SB, Ortega-Gutierrez S, Choi HA, Claassen J, Presciutti M, Schmidt JM, et al. Status epilepticus-induced hyperemia and brain tissue hypoxia after cardiac arrest. *Archives of neurology.* 2011 Oct 1;68(10):1323-6.
- Beersma MF, Galama JM, Van Druten HA, Renier WO, Lucas CJ, Kapsenberg JG. Subacute Sclerosing Panencephalitis In The Netherlands—1976–1990. *Intern J Epidemiol.* 1992 Jun 1;21(3):583-8.
- Jabbour JT, Duenas DA, Sever JL, Krebs HM, Horta-Barbosa L. Epidemiology of subacute sclerosing panencephalitis (SSPE): a report of the SSPE registry. *JAMA.* 1972 May 15;220(7):959-62.
- Chiu MH, Meatherall B, Nikolic A, Cannon K, Fonseca K, Joseph JT, et al. Subacute sclerosing panencephalitis in pregnancy. *The Lancet Infectious Dis.* 2016 Mar 1;16(3):366-75.
- Oyanagi S, Rorke LB, Katz M, Koprowski H. Histopathology and electron microscopy of three cases of subacute sclerosing panencephalitis (SSPE). *Acta neuropathologica.* 1971 Mar 1;18(1):58-73.
- Ohya T, Martinez AJ, Jabbour JT, Lemmi H, Duenas DA. Subacute sclerosing panencephalitis: correlation of clinical, neurophysiologic and neuropathologic findings. *Neurology.* 1974 Mar 1;24(3):211-18.
- Iked K, Akiyama H, Kondo H, Arai T, Arai N, Yagishita S. Numerous glial fibrillary tangles in oligodendroglia in cases of subacute sclerosing panencephalitis with neurofibrillary tangles. *Neuroscience letters.* 1995 Jul 14;194(1-2):133-35.
- Lewandowska E, Szpak GM, Lechowicz W, Pasennik E, Sobczyk W. Ultrastructural changes in neuronal and glial cells in subacute sclerosing panencephalitis: correlation with disease duration. *Folia neuropathologica.* 2001;39(3):193-202.
- Khadilkar SV, Patil SG, Kulkarni KS. A study of SSPE: early clinical features. *J Pediatr Neurol.* 2004 Jan 1;2(2):73-7.
- Gadoth N. Subacute sclerosing panencephalitis (SSPE) the story of a vanishing disease. *Brain and Development.* 2012 Oct 1;34(9):705-11.
- Eroglu E, Gokcil Z, Bek S, Ulas UH, Ozdag MF, Odabasi Z. Long-term follow-up of patients with adult-onset subacute sclerosing panencephalitis. *J Neurological Sciences.* 2008 Dec 15;275(1-2):113-16.
- Cole AJ, Henson JW, Roehrl MH, Frosch MP. Case 24-2007: A 20-Year-Old Pregnant Woman with Altered Mental Status. *New England J Med.* 2007 Aug 9;357(6):589-600.
- Dimova PS, Bojinova VS. Case of subacute sclerosing panencephalitis with atypical absences and myoclonic-atonic seizures as a first symptom. *J Child Neurol.* 2004 Jul;19(7):548-52.
- Babu RB, Biswas J. Bilateral macular retinitis as the presenting feature of subacute sclerosing panencephalitis. *J Neuro-Ophthalmol.* 2007 Dec 1;27(4):288-91.
- Agarwal A, Singh R, Kumar A, Dogra MR, Gupta A. Bilateral subretinal fluid and retinal vasculopathy associated with subacute sclerosing panencephalitis.

- Retinal Cases and Brief Reports. 2017 Apr 1;11(2):145-7.
23. Baillif S, Tieulie N, Queyrel V, Cornut PL, Gastaud P. New aspects of viral necrotizing retinitis in subacute sclerosing panencephalitis with spectral-domain optical coherence tomography. *Retinal Cases and Brief Reports.* 2012 Jul 1;6(3):235-41.
  24. Risk WS, Haddad FS. The variable natural history of subacute sclerosing panencephalitis: a study of 118 cases from the Middle East. *Arch Neurol.* 1979 Oct 1;36(10):610-4.
  25. Gutierrez J, Issacson RS, Koppel BS. Subacute sclerosing panencephalitis: an update. *Developmental Med Child Neurol.* 2010 Oct;52(10):901-7.
  26. Ekmekci Ö, Karasoy H, Gökçay A, Ülkü A. Atypical EEG findings in subacute sclerosing panencephalitis. *Clinical Neurophysiol.* 2005 Aug 1;116(8):1762-7.
  27. Dyken PR. Subacute sclerosing panencephalitis: current status. *Neurologic Clinics.* 1985 Feb 1;3(1):179-96.
  28. Anlar B, Yalaz K, Ustacelebi S. Symptoms and clinical signs, laboratory data in 80 cases of subacute sclerosing panencephalitis. *Revue Neurologique.* 1988;144(12):829-32.
  29. Owens GP, Gilden D, Burgoon MP, Yu X, Bennett JL. Viruses and multiple sclerosis. *The Neuroscientist.* 2011 Dec;17(6):659-76.
  30. Jayakumar PN, Taly AB, Arya BY, Nagaraj D. Computed tomography in subacute sclerosing panencephalitis: report of 15 cases. *Acta neurologica scandinavica.* 1988 Apr;77(4):328-30.
  31. Praveen-Kumar S, Sinha S, Taly AB, Jayasree S, Ravi V, Vijayan J, et al. Electroencephalographic and imaging profile in a subacute sclerosing panencephalitis (SSPE) cohort: a correlative study. *Clinical neurophysiology.* 2007 Sep 1;118(9):1947-54.
  32. Jones C, Huttenlocher P, Dyken P, Jabbour JT, Maxwell K. Inosiplex therapy in subacute sclerosing panencephalitis: a multicentre, non-randomised study in 98 patients. *Lancet.* 1982 May 8;319(8280):1034-7.
  33. Dyken PR, Swift A, Durant RH. Long-term follow-up of patients with subacute sclerosing panencephalitis treated with inosiplex. *Ann Neurol: Official J Am Neurolog Association Child Neurol Soc.* 1982 Apr;11(4):359-64.
  34. Aydin ÖF, Şenbil N, Kuyucu N, Gürer YY. Combined treatment with subcutaneous interferon- $\alpha$ , oral isoprinosine, and lamivudine for subacute sclerosing panencephalitis. *J Child Neurol.* 2003 Feb;18(2):104-8.
  35. Jovic NJ. Epilepsy in children with subacute sclerosing panencephalitis. *SrpArhCelok Lek* 2013;141:434-40.
  36. Watanabe M, Hashimoto K, Abe Y, Kodama EN, Nabika R, Oishi S, et al. A novel peptide derived from the fusion protein heptad repeat inhibits replication of subacute sclerosing panencephalitis virus in vitro and in vivo. *PloS one.* 2016;11(9).
  37. Becker D, Patel A, Abou-Khalil BW, Pina-Garza JE. Successful treatment of encephalopathy and myoclonus with levetiracetam in a case of subacute sclerosing panencephalitis. *J Child Neurol.* 2009 Jun;24(6):763-7.
  38. Maalouf M, Rho JM, Mattson MP. The neuroprotective properties of calorie restriction, the ketogenic diet, and ketone bodies. *Brain Research Reviews.* 2009 Mar 1;59(2):293-315.
  39. Yaqub BA. Subacute sclerosing panencephalitis (SSPE): early diagnosis, prognostic factors and natural history. *J Neurological Sci.* 1996 Aug 1;139(2):227-34.
  40. Risk WS. Subacute sclerosing panencephalitis with remission in a Bosnian refugee child. *Pediatric Infectious Dis J.* 2003 Aug;22(8):757-8.
  41. Risk WS, Haddad FS. The variable natural history of subacute sclerosing panencephalitis: a study of 118 cases from the Middle East. *Arch Neurol.* 1979 Oct 1;36(10):610-4.
  42. Prashanth LK, Taly AB, Ravi V, Sinha S, Rao S. Long term survival in subacute sclerosing panencephalitis: an enigma. *Brain and Development.* 2006 Aug 1;28(7):447-52.
  43. Douglas-Escobar M, Weiss MD. Hypoxic-ischemic encephalopathy: a review for the clinician. *JAMA Pediatr.* 2015 Apr;169(4):397-403.
  44. Van Laerhoven H, de Haan TR, Offringa M, Post B, van der Lee JH. Prognostic tests in term neonates with hypoxic-ischemic encephalopathy: a systematic review. *Pediatrics.* 2013 Jan 1;131(1):88-98.
  45. Thoresen M, Hellström-Westas L, Liu X, de Vries LS. Effect of hypothermia on amplitude-integrated electroencephalogram in infants with asphyxia. *Pediatrics.* 2010 Jul 1;126(1):e131-9.
  46. Morita K, Nabeshima T, Buerano CC. Japanese encephalitis. *Rev Sci Tech.* 2015 Aug 1;34(2):441-52.
  47. Dung NM, Turtle L, Chong WK, Mai NT, Thao TT, Thuy TT, et al. An evaluation of the usefulness of neuroimaging for the diagnosis of Japanese encephalitis. *J Neurol.* 2009 Dec 1;256(12):2052.
  48. Newman MP, Blum S, Wong RC, Scott JG, Prain K, Wilson RJ, et al. Autoimmune encephalitis. *Internal Medicine Journal.* 2016 Feb;46(2):148-57.
  49. Lakshmi V, Malathy Y, Rao RR. Serodiagnosis of subacute sclerosing panencephalitis by enzyme linked immunosorbent assay. *Indian J Pediatr.* 1993 Jan 1;60(1):37-41.

**Cite this article as:** Singh R, Mahajan ZA, Mehta SR, Ranchhod J, Nadkarni SJ. Subacute sclerosing panencephalitis: case based review. *Int J Res Med Sci* 2020;8:3135-40.