

## Case Report

# Pulmonary pleomorphic carcinoma masquerading as pulmonary tuberculosis: incidental autopsy finding

Teerthanath Srinivas, Shreya Goel\*, Shubha P. Bhat, Ritu Asnani

Department of Pathology, K.S Hegde medical academy, Mangalore, Karnataka, India

**Received:** 02 September 2020

**Accepted:** 07 October 2020

### \*Correspondence:

Dr. Shreya Goel,

E-mail: drshreyagoel2@gmail.com

**Copyright:** © the author(s), publisher and licensee Medip Academy. This is an open-access article distributed under the terms of the Creative Commons Attribution Non-Commercial License, which permits unrestricted non-commercial use, distribution, and reproduction in any medium, provided the original work is properly cited.

## ABSTRACT

Pleomorphic carcinoma is a very rare subtype of pulmonary sarcomatoid carcinoma. It is an aggressive primary lung carcinoma that accounts for about <0.4% of lung tumors. The tumor usually recurs, resulting in a poor prognosis even after complete resection. Herein, we report an extremely rare case of an advanced pleomorphic carcinoma of the lung which was incidentally detected on autopsy as pulmonary tuberculosis. This patient did not have any clinical manifestations of either malignancy or tuberculosis when he was alive. This is extremely rare, being it an aggressive carcinoma that presents without any apparent symptoms.

**Keywords:** Pleomorphic carcinoma, Autopsy, Incidental, Smoking

## INTRODUCTION

Lung tumors are usually associated with chronic smoking and inhalation of pollutants. The lung tumors clinically present with symptoms of cough, hemoptysis, weight loss, breathlessness and loss of appetite. Histologically they usually belong to squamous cell, adenocarcinoma or small cell carcinoma. However, sarcomatoid carcinomas are extremely rare, very aggressive and high-grade tumors, which accounts for 0.3% of invasive lung malignancies.<sup>1</sup>

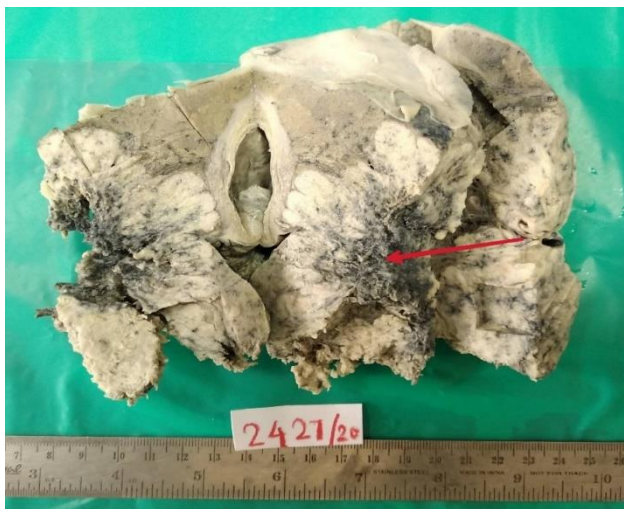We report an extremely rare case of pulmonary pleomorphic carcinoma (PPC), which was incidentally detected during autopsy of the patient who did not have any clinical manifestation of lung tumor, while he was alive.

## CASE REPORT

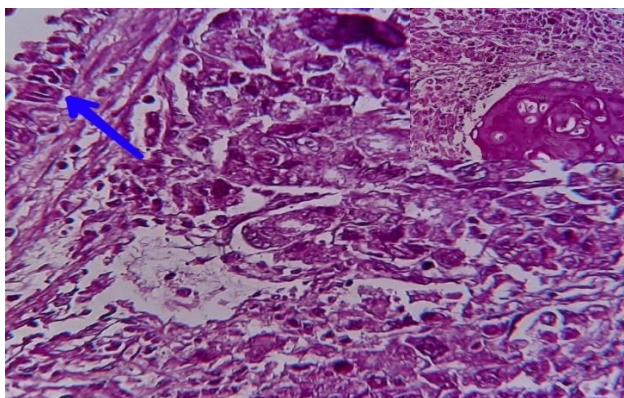
A case of 63-year male with history of accidental drowning was brought to forensic department for autopsy. The patient was a chronic smoker, an occasional

alcoholic and did not have any clinical manifestations nor had any previous history of chronic lung disease. On dissection, thorax was opened by making "I" shaped incision, the left mid and lower lobe of the lung were adherent to chest wall and were difficult to separate. After meticulous dissection lungs were exposed. Left mid and lower lobe showed an irregular gray white lesion involving the pleura and chest wall. All other organs systems appeared normal. Axillary lymph nodes were not enlarged. On autopsy table pulmonary tuberculosis was suspected. The involved adherent mid and lower lobes of the left lung were removed and were sent for histological confirmation.

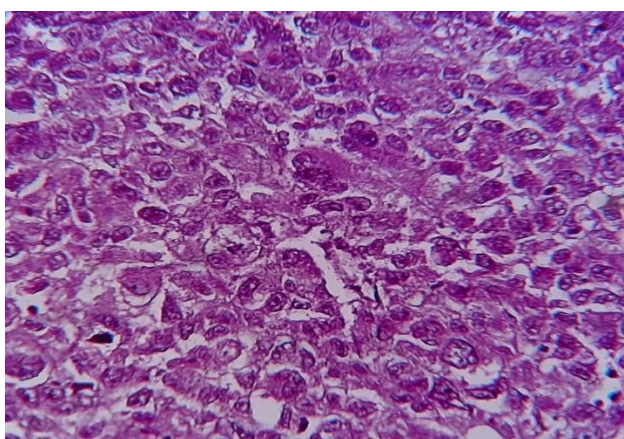
Grossly we received mid and lower lobes of left lung measuring 14.5x10.5x7 cm and weighing 428 gm. Outer surface showed an irregular grey white lesion with loss of parietal pleura measuring 12x8 cm with areas of necrosis. Sectioning revealed an irregular grey white tumor measuring 9x5.5x6.5 cm involving mid and lower lobe of left lung, predominantly seen in periphery of lung with irregular areas of necrosis. Hilar lymph nodes appeared gray white (Figure 1).



**Figure 1: Cut section of the left lung showing invasive gray white tumor involving the pleural surface (marked by red arrow).**



**Figure 2: Pleomorphic tumor cells in sheet with blue arrow showing respiratory epithelium. (H&E 400X)  
Inset shows squamous component (H&E 100X).**



**Figure 3: Pleomorphic bizarre looking tumor cells and anaplastic giant cells (H&E 400X).**

Microscopically the tumor cells were discohesive, large, polygonal to pleomorphic and spindle shaped having pleomorphic vesicular nucleus, prominent nucleoli, frequent mitosis (25-30/10 hpf) and moderate to abundant eosinophilic cytoplasm. There were a good number of anaplastic bizarre tumor giant cells noted amidst the tumor cells. Tumor cells were invading in irregular clusters with extensive areas of necrosis. (Figure 2 and 3).

The sections from the coastal and diaphragmatic visceral pleural surface also revealed extensive tumor infiltration. There was evidence of metastatic tumor in hilar lymph nodes. There was no evidence of tuberculosis in multiple sections studied. The final diagnosis of pleomorphic carcinoma- variant of sarcomatoid carcinoma of the lung, histological grade 4- undifferentiated. The pathological staging (pTNM) was pT4pN1.

### DISCUSSION

Lung tumors are currently the most frequently diagnosed tumors and cancer related deaths in both men and women. It accounts for 14% of new cancers in men and 13% of new cancers in women which is commonly associated with chronic smoking.<sup>2</sup> Lung tumors presents with manifestations of cough, sputum, hemoptysis and breathlessness.<sup>3</sup>

Sarcomatoid carcinomas accounts for 0.3% of all lung tumors.<sup>1</sup> According to the Surveillance, Epidemiology, and End Results (SEER) Database (1973-2013), of all diagnosed cases of NSCLC, Sarcomatoid carcinoma (SC) was present in only 0.52% of the cases.<sup>4</sup> SC is a heterogeneous group of tumors without any definitive diagnostic criteria.<sup>5</sup> The classification of SC of lung has been controversial, but recent WHO classification is completely based on the histological features and is straight forward. WHO classifies sarcomatoid lung carcinoma into five distinct subtypes; pleomorphic carcinoma, spindle cell carcinoma, giant cell carcinoma, carcinosarcoma and pulmonary blastoma.<sup>1</sup>

PPC is an uncommon variant of sarcomatoid carcinoma and only few cases have been reported in the literature. It accounts for 0.1-0.4% of all lung carcinomas. A retrospective study of 718 lung malignancies was done by Mirza et al wherein PPC accounts for only 0.14% of all lung malignancies.<sup>1</sup> PPC is most commonly seen in 60-65 years of age. It has male predominance, with male to female ratio of 4.4:1 and has strong association with smoking. PPC also arises in various other organs like oral cavity, larynx, thyroid, breast, kidney, urinary bladder, pancreas and lung.<sup>6</sup> In lung PPC presents with early clinical manifestation of chronic cough, hemoptysis and chest pain.<sup>3</sup> In our case patient did not have any complaints related to lung tumor. It was an incidental finding found during the autopsy.

The PPC is a biphasic tumor with carcinomatous component comprising of either squamous cell carcinoma, adenocarcinoma, large cell carcinoma and mixed cell type. The sarcomatous component comprises of giant cell or spindle cell or both giant and spindle cells. The giant and/or spindle cell element should be at least 10% of the tumor.<sup>6</sup> In our case, pleomorphic component was 95% and giant cells were 20%. Conventional adenocarcinoma and squamous cell carcinomas are the most common carcinomatous element.<sup>3</sup> Histological differential diagnosis of metastatic undifferentiated carcinoma needs to be ruled out from primary lung carcinoma based on the clinical and radiological evaluation. Immunohistochemistry can be used for confirmation like TTF-1 and SP-A markers are used to diagnose adenocarcinoma, while pan cytokeratin (CAM 5.2 and LP 34) will be positive in sarcomatoid carcinoma.<sup>7</sup> For evaluation of pulmonary epithelial tumor, monoclonal antibodies are available like surfactant Apo protein-A, thyroid transcription factor-1 and cytokeratins can be used to differentiate from metastatic tumor.<sup>3</sup> Pathogenesis of PPC is unclear. Two hypotheses are considered. Monoclonal origin hypothesis suggests stem cell giving rise to both epithelial and mesenchymal components and polyclonal origin for each of mesenchymal and epithelial components. Recent molecular studies have shown epithelial mesenchymal transition, that is, sarcomatoid transformation from epithelial component.<sup>6</sup>

Radiologically PPC presents as large peripheral mass and shows substantial enhancement on contrast computed tomography. The central low attenuation areas and myxoid degeneration is seen in lesions larger than 5cm which corresponds to regions of hemorrhage or necrosis.<sup>3,8</sup> It has upper lobe predilection. Pleural metastasis is frequently encountered.<sup>9</sup> In our case, the tumor was located in middle and lower lobe along with pleural involvement which is even rarer.

Trans thoracic CT guided biopsy may be helpful in arriving at the definitive diagnosis. In PPC due to tumor heterogeneity, preoperative diagnosis is difficult.<sup>10</sup> Transbronchial biopsies are usually a failure in these cases, as the tumor usually has peripheral predominance. Diagnosis of sarcomatoid tumors can be done by light microscopy. The PPC is an aggressive tumor and has worse clinical outcome than other NSCLC.<sup>11</sup>

In early PPC, surgery is the first choice, however recurrence is more common after complete resection. Wedge resection has worth prognosis as compared to lobectomy.<sup>12</sup> In advanced cases of PPC palliative chemotherapy is used.<sup>3</sup> Epidermal growth factor receptor (EGFR) mutation occurs in 15-20% patients with PPC, but because of tumor heterogeneity, response to EGFR TKIs was transient and weak.<sup>7</sup> In a study by Tamura et al PPC revealed KRAS mutation and EGFR mutation and were negative for ALK expression.<sup>13</sup> While in another study done by Ushiki et al revealed that adenocarcinoma

cells had an exon 19 deletion and sarcomatous cells had both the deletion 19 and 20 T790M EGFR mutations.<sup>14</sup> To select targeted immunotherapy, testing of other potential genetic alterations could be beneficial.<sup>1</sup> There is no influence of histological entity on patient's survival as found in a retrospective study done by Rosel et al on 58 patients, although older patients (>65 years) had decreased survival rate.<sup>15</sup> The 5-year overall survival was 20–40%, according to the Japanese joint committee of lung cancer registry data, whereas that of the other histologic types was 61.4%.<sup>16</sup> Chang et al reported 3 months as median survival time for inoperable cases treated by chemotherapy.<sup>17</sup> In a study done by Mochizuki et al, massive coagulative necrosis was found to be an independent prognostic factor for disease free survival.<sup>6</sup>

## CONCLUSION

PPC is an extremely rare tumor with aggressive biological behavior and low incidence which usually presents with severe clinical manifestations like cough, hemoptysis and chest pain, while they can be asymptomatic as noted in our case which is quite rare. Light microscopy from the tumor can yield definitive diagnosis though IHC may not be necessary as PPC contain all the components. Clinically one should suspect sarcomatoid carcinoma in contrast to pulmonary tuberculosis involving the lung when mantoux test and biopsy are inconclusive.

*Funding: No funding sources*

*Conflict of interest: None declared*

*Ethical approval: Not required*

## REFERENCES

1. Mirza R, Shi M. Large pleomorphic carcinoma of the lung Human Pathology. *Cas Repor.* 2019;16:1-4.
2. Siegel RL, Miller KD, Jemal A. Cancer statistics, 2018. *CA Cancer J Clin.* 2018;68:7-30.
3. Zhang X, Wang Y, Zhao L, Jing H, Sang S, Du J. Pulmonary pleomorphic carcinoma: A case report and review of the literature. *Medic.* 2017;96(29):e7465.
4. Rahouma M, Kamel M, Narula N, Nasar A, Harrison S, Lee B et al. Pulmonary sarcomatoid carcinoma: an analysis of a rare cancer from the surveillance, epidemiology, and end results database. *Eur J Cardiothorac Surg.* 2018;53:828-34.
5. Blaukovitsch M, Halbwedl I, Kothmaier H, Kammerer MG, Popper HH et al. Sarcomatoid carcinomas of the lung—are these histogenetically heterogeneous tumors. *Virchows Arch.* 2006;449(4):455-61.
6. Mochizuki T, Ishii G, Nagai K, Yoshida J, Nishimura M, Mizuno T et al. Pleomorphic carcinoma of the lung: Clinicopathologic characteristics of 70 cases. *Am J Surg Pathol.* 2008;32(11):1727-35.

7. Anter AH, Al-Jahel M, AbdelLatif RM, AbdELmohsen MF, Shata A. Pulmonary pleomorphic carcinoma harboring epidermal growth factor receptor mutation: Response to afatinib. *J Cancer Res Pract.* 2019;6:103-6.
8. Fujisaki A, Aoki T, Kasai T, Kinoshita S, Tomoda Y, Fumihiro T et al. Pleomorphic Carcinoma of the Lung: Relationship Between CT Findings and Prognosis. *AJR Am J Roentgenol.* 2016;207(2):289-94.
9. Kim TS, Han J, Lee KS, Jeong JY, Kwak SH, Byun HS et al. CT findings of surgically resected pleomorphic carcinoma of the lung in 30 patients. *AJR Am J Roentgenol.* 2005;185(1):120-5.
10. Kim MJ, Lee HN, Kim JI, Kim GY. Pleomorphic carcinoma of the lung mimicking synchronous pulmonary adenocarcinoma and small bowel sarcoma. *Ann Thorac Med.* 2018;13(4):251-3.
11. Roesel C, Terjung S, Weinreich G, Hager T, Chalvatzoulis E, Metzenmacher M et al. Sarcomatoid carcinoma of the lung: a rare histological subtype of nonsmall cell carcinoma with a poor prognosis even at earlier tumor stages, *Interact Cardiovasc Thorac Surg.* 2017;24(3):407-13.
12. Lui NS. Commentary: Pleomorphic carcinoma: An aggressive type of non-small cell lung cancer that should be treated like the others. *J Thorac Cardiovasc Surg.* 2019;158(2):592-3.
13. Tamura Y, Fujiwara Y, Yamamoto N, Nokihara H, Horinouchi H, Kanda S. et al. Retrospective analysis of the efficacy of chemotherapy and molecular targeted therapy for advanced pulmonary pleomorphic carcinoma. *Brit Med Cen Res Notes.* 2015;8:800.
14. Asamura H, Goya T, Koshiishi Y, Sohara Y, Eguchi K, Mori M et al. A Japanese Lung Cancer Registry study: prognosis of 13,010 resected lung cancers. *J Thorac Oncol.* 2008;3:46-52.
15. Kaira K, Horie Y, Ayabe E, Murakami H, Takahashi T, Tsuya A et al. Pulmonary pleomorphic carcinoma: a clinicopathological study including EGFR mutation analysis. *J Thorac Oncol.* 2010;5(4):460-5.
16. Ushiki A, Koizumi T, Kobayashi N, Kanda S, Yasuo M, Yamamoto H et al. Genetic heterogeneity of EGFR mutation in pleomorphic carcinoma of the lung: response to gefitinib and clinical outcome. *Jpn J Clin Oncol.* 2009;39(4):267-70.
17. Chang YL, Lee YC, Shih JY, Wu CT. Pulmonary pleomorphic (spindle) cell carcinoma: peculiar clinicopathologic manifestations different from ordinary non-small cell carcinoma. *Lun Canc.* 2001;34:91-7.

**Cite this article as:** Srinivas T, Goel S, Bhat SP, Asnani R. Pulmonary pleomorphic carcinoma masquerading as pulmonary tuberculosis: incidental autopsy finding. *Int J Res Med Sci* 2020;8:4134-7.