

Case Report

Cephalosporin graded challenges approach in community-acquired pneumonia patient with a history of penicillin allergy

Ketut Suryana*

Department of Internal Medicine, Merpati Clinic, Wangaya HIV Study Group (WHSG), Allergy and Clinical Immunology Services Unit at Wangaya Hospital in Denpasar, Bali, Indonesia

Received: 25 April 2021

Accepted: 29 May 2021

***Correspondence:**

Dr. Ketut Suryana,

E-mail: ketutsuryana@gmail.com

Copyright: © the author(s), publisher and licensee Medip Academy. This is an open-access article distributed under the terms of the Creative Commons Attribution Non-Commercial License, which permits unrestricted non-commercial use, distribution, and reproduction in any medium, provided the original work is properly cited.

ABSTRACT

Community-Acquired Pneumonia (CAP) is an acute pulmonary parenchyma infection that acquired in the community. Diagnosis based on clinical manifestations, chest X-ray (CXR) and microbiological diagnosis test (lung aspirates culture). Recently there was advance in antimicrobial treatments of CAP and a microbiological diagnostic test is essential to ensure antimicrobial treatments. In the other hand microbiological diagnostic test does not achieve all of the pneumonic cases. Therefore, antimicrobial treatment should be empirically performed to avoid the delay in establishing appropriate treatment related with the mortality. By administering combination antimicrobial will achieve a better outcome than a mono-therapy. For patients with history of penicillin allergy, though the risk of cephalosporin allergic cross-reactivity is low, a greater awareness is still needed, so a graded challenge approach could be considered. Herein we present a case report of a female, 20-year-old, hospitalized due to CAP, and also had a history of penicillin allergy. She was treated by levofloxacin 750 mg IV q 24 hour and cephalosporin (ceftriaxone) 1 g IV q 12 hour with a Graded challenge approach. Although it does not a novelty, we hope it would remind the health care that a Graded challenge could be considered as an approach of administering cephalosporin in patient who has an experience of penicillin allergy.

Keywords: A Community-acquired pneumonia, Penicillin allergy, Allergic cross-reactivity, Graded challenge approach

INTRODUCTION

Pneumonia is an acute respiratory illness associated with recently CXR result.¹⁻³ Pneumonia are classified as Community acquired pneumonia (CAP), Hospital-Acquired Pneumonia (HAP) and Ventilator associated pneumonia (VAP).^{1,2} Microbiological diagnosis test as the basic consideration to take an appropriate antibiotic treatment, decreases mortality. It has been confirmed in <50% of cases, so antimicrobial treatment should be administered empirically. The regimens is levofloxacin 750 mg IV q 24 hour combination with cephalosporin 1 g IV q 12 hour.^{1,2}

Although penicillin cross-reactivity to cephalosporin is about 3%, administering cephalosporin for patient with history of penicillin allergy should be considered by a Graded challenge approach.^{4,5} The patient signed a written informed consent, the study procedure has been approved by the Wangaya Hospital Ethical Committee in Denpasar, Bali, Indonesia and it is allowed to publish this case report. In conjunction with the Declaration of Helsinki, this study was conducted.

CASE REPORT

A female, 20-year-old, came to Emergency Unit at Wangaya Hospital on December 10th, 2020 (1-day) with

complaint fever, cough, dyspnea and chest pain for 5 days prior to admission. No closed contact with a COVID-19 patient, had a history of penicillin allergy.

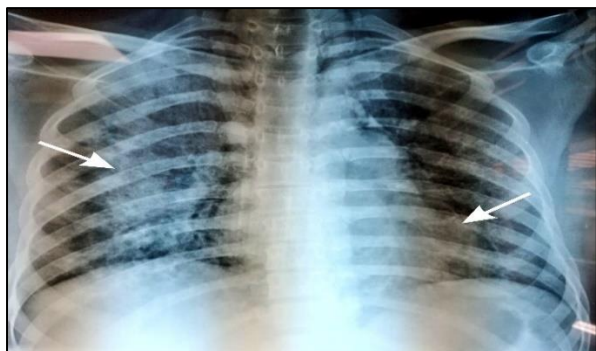

Figure 1: The chest X-ray on I-day (admission) showed minimal bilateral infiltrates.

Fully alert, blood pressure 120/80 mmHg, pulse rate 92 times per minute, the body temperature 38.20 C and respiratory rate 28 breaths per minute, oxygen saturation (SpO₂) 94%. The CXR result showed bilateral infiltrates in the lungs (Figure 1).

Other laboratory results; leucocytosis $13.28 \times 10^3 / \mu\text{L}$ ($4.0\text{-}10.0 \times 10^3 / \mu\text{L}$), neutrophil to lymphocyte ratio / NLR 3.90

(<3.13). ALT was 14 U/L, AST was 22 U/L, Urea was 12 mg/dL, creatinine serum was 0.8 mg/dL, albumin serum level 3.9 g/dL and blood sugar 127 mg/dL (80-200 mg/dL), normal electrolyte levels and RT-PCR was negative SARS-CoV-2.

Based on the clinical manifestations, the laboratory results and CXR, the final diagnosis was pneumonia (CAP) with a history of penicillin allergy. She was hospitalised (inpatient non-ICU), treated by levofloxacin 750 mg IV q 24-hour combination with cephalosporin (ceftriaxone) 1 g IV q 12 hour by a Graded challenge approach, we started with a small dose and increased to the desired dose. No reaction occurred with the therapeutic dose, further more we could give the drug as prescribed.

Progress note

On the first day hospitalized (December 10th, 2020), she was treated by administering Levofloxacin 750 mg IV q 24-hour combination with Cephalosporins (Ceftriaxone) 1 g IV q 12 hours. Another symptomatic treatment and oxygenation. The patients with a history of penicillin allergy, and did not get a penicillin skin testing, Ceftriaxone treatment, should be considered via a Graded challenge approach, begin with a low dose and gradually increase to the desired dose.

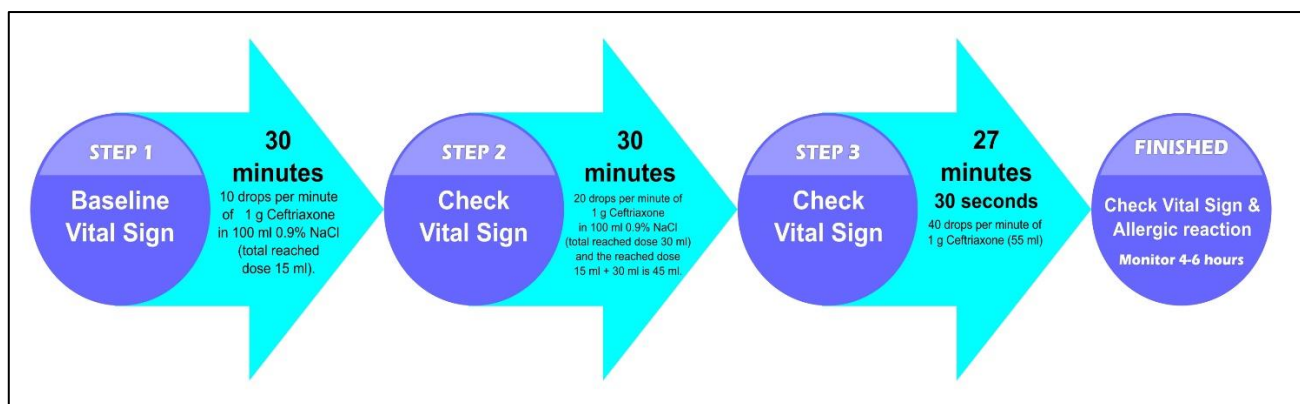


Figure 2: A graded challenge procedure.

DISCUSSION

CAP clinical manifestations are fever, cough, dyspnea, chills, fatigue, rigors, pleuritic chest pain and normal or leucocytosis with pneumonia radiographic evidence.¹

She was complaints of fever, cough, and shortness of breath for 5 days, had a history of penicillin allergy, no closed contact with a COVID-19 patient. The laboratory results, leucocytosis $13.28 \times 10^3 / \mu\text{L}$ ($4.0\text{-}10.0 \times 10^3 / \mu\text{L}$), neutrophilia $8.12 \times 10^3 / \mu\text{L}$ ($1.50\text{-}7.00 \times 10^3 / \mu\text{L}$), lymphocyte $2.08 \times 10^3 / \mu\text{L}$ ($1.00\text{-}3.70 \times 10^3 / \mu\text{L}$), neutrophil to lymphocyte ratio / NLR 3.90 (<3.13). RT-PCR was negative SARS-CoV-2. CXR showed bilateral

infiltrates in the lungs and normal of heart. Finally, the patient was confirmed with CAP with a history of penicillin allergy. Due to the limitation of microbiological diagnosis, recent guidelines for empirical would be essential. Empiric treatment regimens for CAP for inpatient non-ICU:

Levofloxacin 750 mg IV or PO q 24 hour or Moxifloxacin 400 mg IV or PO q 24 hour or combination of a beta-lactam (Ceftriaxone 1g IV q 12 hour or Cefotaxime 1 g IV q 8 hour or Ertapenem 1 g IV daily or Ceftaroline 600 mg IV q 12 hour) plus Azithromycin 500 mg PO q 24 hour. Minimum treatment duration is 5 days, no fever for 48-72 hours. Stable hemodynamic, adequate oral intake, SpO₂ is

greater than 90%, longer duration is probably needed in some cases.^{2,6}

This patient was treated by Levofloxacin 750 mg IV q 24-hour, combination with 1 g Ceftriaxone IV q 12 hour and plus 500 mg Azithromycin PO q 24 hour and other symptomatic treatment, intra venous fluid drip, oxygenation and high calorie protein diet.

Cephalosporin causes allergic reaction with a similar spectrum such as penicillins. Allergic cross-reactivity between Cephalosporin and Penicillins potentially occurs due to presence of similar R-group side chains. It's about 3%, although it may seem infrequent, anaphylactic reactions, Stevens-Johnson Syndrome, toxic epidermal necrolysis, and acute generalized exanthematous pustulosis have been reported in patients with penicillin allergy after receiving cephalosporin. The risk factor of cephalosporin allergy is an allergic history to penicillin or cephalosporin itself.⁷⁻⁹

She was found with a history of penicillin allergy. A Graded challenge approach was considered as a treatment approach of Ceftriaxone, to confirm that the patient might safely receive the drug.

Generally, the standard A Graded challenge approach needs 2 to 3 steps, with the initial dose is lower than the full dose, increasing doses are given every 30 to 60 minutes until the therapeutic dose is reached fully (Figure 2). It's may be the most fixed in vivo test to confirm the existence of an antibiotic allergy.¹⁰⁻¹²

The therapeutic dose was reached with no reaction, so it was concluded no allergic reaction to Ceftriaxone, she could take the drug as prescribed for 5 days.

CONCLUSION

CAP diagnosis is based on clinical manifestations, laboratory results and CXR evidence of pneumonia. The limitations of pneumonia microbiological diagnosis, so antimicrobial treatment should be empirically. The patient who experiences a history of penicillin allergy, a Graded challenge approach should be considered as a cephalosporin treatment strategy. It may be the most fixed in vivo test to confirm the existence of an antimicrobial allergy.

ACKNOWLEDGEMENTS

The author appreciates to Emergency Care Unit Team at Wangaya Hospital in Denpasar, Bali, Indonesia. All of the

staffs in Praja Amerta Wards, for a good team work. The author would also like to thank to the patients and the family, Director Wangaya Hospital for all of the supports.

Funding: No funding sources

Conflict of interest: None declared

Ethical approval: Not required

REFERENCES

1. Cilloniz C, Martin-Loeches I, Garcia-Vidal C, San Jose A, Torres A. Microbial Etiology of Pneumonia: Epidemiology, Diagnosis and Resistance Patterns. *Int J Mol Sci.* 2016;17(12):2120.
2. Akter, S. Community Acquired Pneumonia. *Int J Respir Pulm Med.* 2015;2.
3. Lutfiyya MN, Henley E, Chang LF, Reyburn SW. Diagnosis and treatment of community-acquired pneumonia. *Am Fam Physician.* 2006;73(3):442-50.
4. Pongdee T, Li JT. Evaluation and Management of Penicillin Allergy. *Mayo Clin Proc.* 2018;93(1):101-7.
5. Gonzalez-Estrada A, Radojicic C. Penicillin allergy: A practical guide for clinicians. *Cleve Clin J Me.* 2015;82(5):295-300.
6. Lim WS, Smith DL, Wise MP on behalf of the British Thoracic Society. British Thoracic Society community acquired pneumonia guideline and the NICE pneumonia guideline: how they fit together. *BMJ Open Respiratory Research.* 2015;2:e000091.
7. Devchand M, Trubiano JA. Penicillin allergy: a practical approach to assessment and prescribing. *Aust Prescr.* 2019;42(6):192-9.
8. Yuson CL, Katelaris CH, Smith WB. 'Cephalosporin allergy' label is misleading [published correction appears in *Aust Prescr* 2018;41(6):205]. *Aust Prescr.* 2018;41(2):37-41.
9. Kim MH, Lee JM. Diagnosis and management of immediate hypersensitivity reactions to cephalosporins. *Allergy Asthma Immunol Res.* 2014;6(6):485-95.
10. Abrams EM, Khan DA. Diagnosing and managing drug allergy. *CMAJ.* 2018;190(17):E532-8.
11. Khan DA, Solensky R. Drug allergy. *J Allergy Clin Immunol.* 2010;125(Suppl 2):S126-37.
12. Pourpak Z, Fazlollahi MR, Fattahi F. Understanding adverse drug reactions and drug allergies: principles, diagnosis and treatment aspects. *Recent Pat Inflamm Allergy Drug Discov.* 2008;2(1):24-46.

Cite this article as: Suryana K. Cephalosporin graded challenges approach in community-acquired pneumonia patient with a history of penicillin allergy. *Int J Res Med Sci* 2021;9:2106-8.